

An Unusual Case of Osteomyelitis in a Pediatric Patient

Patel Amy ¹, Hyer Matthew ¹, Heydarlou Dorsa ¹, Thiemann Anna ², Kayali Mohammad ³, Ranasinghe Leonard ^{4*}

¹ Second-year medical students at California Northstate University, Elk Grove, California.

² Fourth-year medical student, California Northstate University College of Medicine, Elk Grove, California.

³ Associate Medical Director, Dignity Woodland Memorial Hospital, Woodland, California.

⁴ Professor and Clerkship Director of Emergency Medicine, California Northstate University College of Medicine, Elk Grove, California.

***Corresponding Author:** Leonard Ranasinghe, Ph.D., MD. Professor and Clerkship Director of Emergency Medicine, California Northstate University College of Medicine, 9700 W. Taron Dr., Elk Grove, California 95757.

Received Date: August 24, 2022; **Accepted Date:** August 31, 2022; **Published Date:** September 07, 2022

Citation: Patel Amy, Hyer Matthew, Heydarlou Dorsa, Thiemann, Anna, Kayali Mohammad. et all (2022) An Unusual Case of Osteomyelitis in a Pediatric Patient. *J. Biomedical Research and Clinical Reviews*. 7(2); DOI:10.31579/2692-9406/131

Copyright: © 2022 Leonard Ranasinghe, this is an open-access article distributed under the terms of the Creative Commons Attribution License, which permits unrestricted use, distribution, and reproduction in any medium, provided the original author and source are credited.

Abstract

Background: In children, *Staphylococcus aureus* infects growing, long bones causing osteomyelitis. While the symptoms are recognizable, its occurrence in children is quite rare.

Purpose: To highlight a novel case of pediatric osteomyelitis with delirium.

Presentation: A 10-year old male presented to the emergency room with a fever and limited range of motion, swelling, and pain in the right clavicular region. His condition declined over two days, developing tachycardia and delirium. Laboratory and imaging studies revealed an abscess in the chest wall as well as severe myositis and cellulitis. The patient was treated with surgical drainage and IV antibiotics, leading to resolution of the patient’s condition.

Conclusion: This case report will help physicians in the pediatric or emergency department settings consider, identify, and accurately assess patients for osteomyelitis in developing treatment plans to resolve their patients’ conditions.

Key words: osteomyelitis; pediatric; methicillin-susceptible *Staphylococcus aureus*; case report; myositis; cellulitis

Abbreviations:

OM	:Osteomyelitis
CRP	:C-reactive Protein
HR	: Heart Rate
BP	:Blood Pressure
TM	:Temperature
RR	:Respiratory Rate
RA	:Room Air
BMI	:Body-Mass Index
ED	:Emergency Department
ROM	:of Motion
WBC	:White Blood Cell
RBC	:Red Blood Cell

Hgb	:Hemoglobin
Hct	:Hematocrit
BUN	:Blood Urea Nitrogen
ALT	:Alanine Transaminase
AST	:Aspartate Transferase
CK	:Creatine Kinase
CT	:Computerized Tomography
UCD	:University of California, Davis
ESR	:Erythrocyte Sedimentation Rate
DFU	:Diabetic Foot Ulcer
COVID-19	:Corona Virus Disease 2019
RSV	:Respiratory Syncytial Virus

Introduction

Osteomyelitis is an infection of the bone that is commonly caused by *Staphylococcus aureus* which causes infection through spread among people, animals, and shared objects. [1,2] In children, it commonly occurs at the metaphysis of long, growing bones which contain venous sinusoids that

promote blood stasis that can promote bacterial growth. [3] Increased risks of trauma, malnutrition, and poor hygiene lead to greater incidence of osteomyelitis in developing countries. [4] The common symptoms of osteomyelitis include pain, swelling, and fever. [5] Although not always

present, elevated white blood cell count and elevated C-reactive protein (CRP) can also be seen in patients with osteomyelitis. [7] While rare, osteomyelitis has been found in the ribs in about 1% of hematogenous cases and should be treated with a targeted antibiotic regimen. [4,8] Osteomyelitis is a disease where early diagnosis and treatment is critical to minimizing the risk of developing severe complications, such as permanent bone damage. In the pediatric population, osteomyelitis may show a multifarious clinical presentation, which ultimately makes diagnosis difficult. Alongside gathering a comprehensive history and performing a thorough physical exam, it is imperative to be aware of the evolving epidemiology and presentation of osteomyelitis to aid in an early diagnosis. Therefore, we present a novel case of an ten-year-old male patient with methicillin-susceptible *Staphylococcus aureus* osteomyelitis of the rib and a chest wall abscess that initially presented as right clavicular pain. Our case report will investigate the uniqueness of a presentation of osteomyelitis of the chest wall in a pediatric patient. We will be evaluating the patient's symptoms, diagnosis and progression and compare it to findings in literature regarding similar presentations. The ultimate goal is to highlight the novelty of the patient's case and its relevance to evaluate and manage patients who may display a similar clinical presentation.

Case Presentation

We present a case of methicillin-susceptible *Staphylococcus aureus* osteomyelitis in the rib and chest wall of an ten-year-old male who was initially seen for right clavicular pain. On day one, the patient's pain was reported as 10/10 starting 4 days prior to arriving at the emergency department and was exacerbated by elevating the right arm or by pressing the affected area over the collarbone. There was no history of shoulder injuries or pain and the patient had otherwise been healthy. Physical exam

revealed HR: 118 bpm, BP: 127/90 mmHg, Tm: 36.5 °C at temporal artery, RR: 20 breaths/minute, O2 Sat: 100% on RA, BMI: 29.09kg/m², Height: 151.5cm. Significant lab results were high absolute neutrophils (9.7 K/uL), low sodium levels (135 mmol/L), high glucose levels (120 mg/dL), and high total protein levels (8.7 gm/dL) and elevated ESR (82 mm/hour) (**Table 1**). An x-ray of the complete right clavicle was also ordered but no fracture, dislocation, or bony erosions were found. The soft tissue appeared normal. The patient was treated for contusion/sprain and dismissed as not having an infectious etiology given that laboratory/imaging work-up did not suggest an inflammatory condition or infection. He was given ibuprofen and discharged with educational materials on musculoskeletal pain and a follow-up appointment within 3-5 days.

On day three, the patient returned to the ED with swelling over the right clavicular and chest area with increased pain, as well as fever, chills, hallucinations, and altered level of consciousness. Physical exam findings revealed HR: 177 bpm, BP: 99/65 mmHg, Tm: 40 °C, RR: 28 breaths/minute, O2 Sat: 99% on RA. Further examination identified skin that was "warm to the touch"; "dry mucous membranes" over the ears, nose, mouth, and throat; tachycardia; and a "well-defined area of swelling and induration in the right upper chest area with mild tenderness but no overlying skin erythema that felt slightly warm compared to the left chest wall". Examination also revealed limited ROM in his right arm and neurological deficits in that the patient was "not answering questions appropriately". Laboratory tests were significant for high WBC count (19.7 K/uL), low hematocrit (34.5%), high absolute neutrophils (15.6 K/uL), low sodium levels (134 mmol/L), low CO₂ (21 mmol/L), and high total protein (8.2 gm/dL) (**Table 1**).

Lab Finding	Value on Day 1	Value on Day 3	Reference Range
WBC (x 10 ³ /μL)	12.5	19.7	4.5-13.5
RBC (x 10 ⁶ /μL)	4.69	4.32	4.20-5.50
Hgb (g/dL)	12.7	11.8	11.5-15.5
Hct (%)	37.6%	34.5	35.0-45.0
Absolute Neutrophils (x 10 ³ /μL)	9.7	15.6	1.0-7.3
Sodium (mmol/L)	135	134	136-146
Glucose (mg/dL)	120	164	70-99
BUN (mg/dL)	10	8	8-25
Creatinine (mg/dL)	0.64	0.63	0.50-1.50
Protein, Total (g/dL)	8.7	8.2	6.0-8.0
Procalcitonin (ng/mL)	Not reported	0.38	0.02-0.15
ALT (units/L)	32	26	0-55
AST (units/L)	20	19	5-34
CK (units/L)	Not reported	70	30-200
CRP (mg/L)	10.59	28.63	0.10-0.90

Lactic Acid (mg/dL)	N/A	0.9	0.6-2.3
ESR (mm/hour)	82	Not reported	< 15

Table 1: Patient’s lab findings on days one and three, 02 December and 04 December respectively. Reference ranges are specific to the presenting emergency department.

Microbiology tests for COVID-19, Influenza A, Influenza B, RSV, and COVID-19 were negative. Chest CT with contrast, returned with extensive severe myositis/cellulitis in the right chest wall, right axilla and anterior to

the sternum to the anterior mediastinum, which occluded the right subclavian vein (**Figures 1 and 2**). Patient was treated with Tylenol and Motrin for the fever as well as broad-spectrum IV antibiotics (Rocephin, vancomycin, and clindamycin, which was added after CT results arrived) to treat infection.

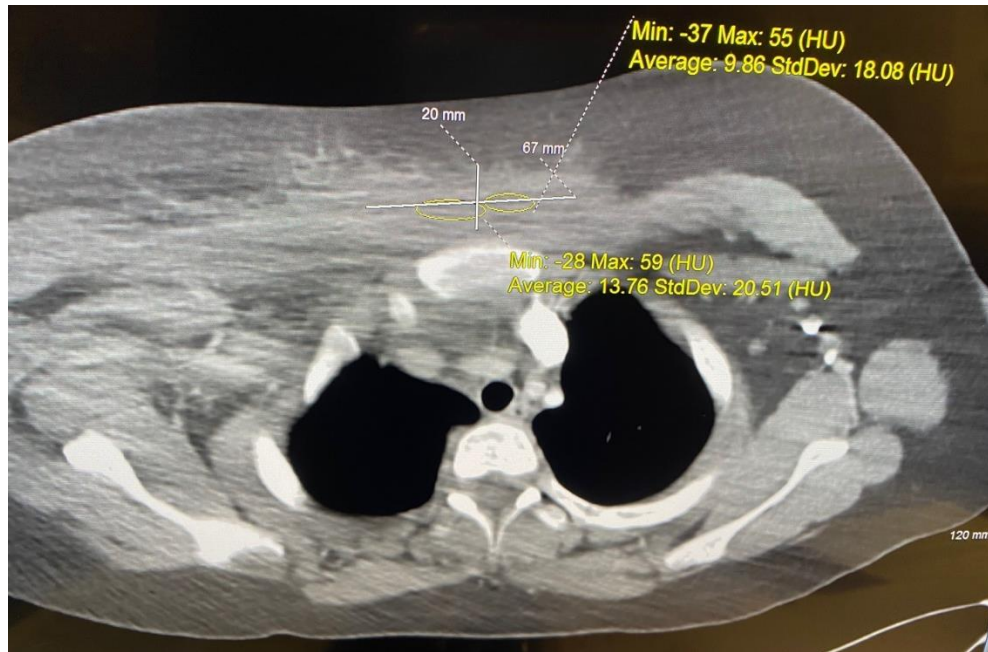


Figure 1: Transverse CT with contrast

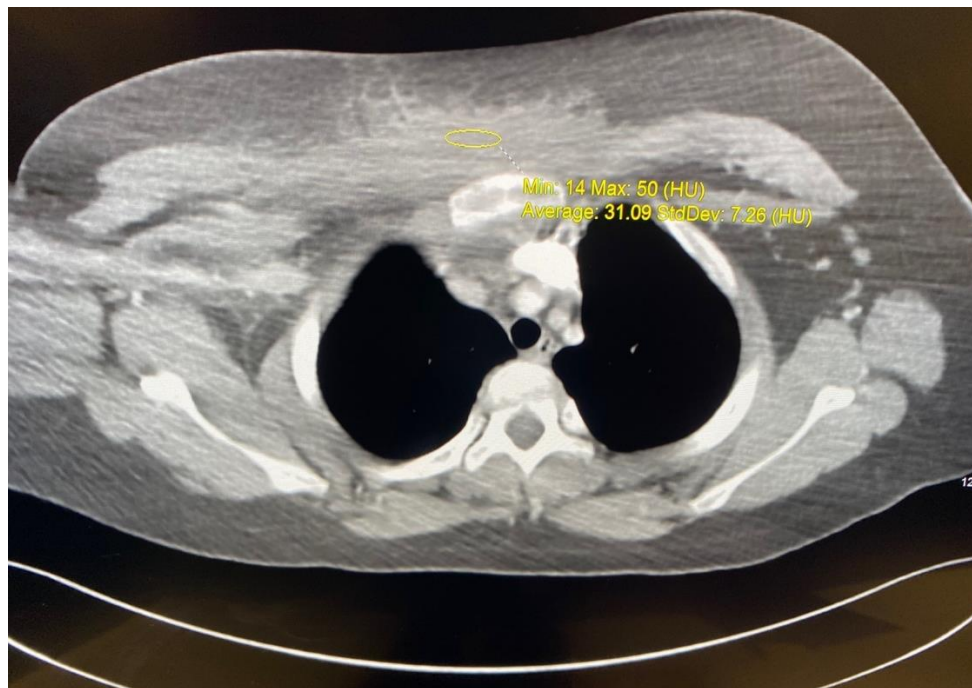


Figure 2: Transverse CT with contrast showing cellulitis/myositis in right chest wall.

The patient was diagnosed with a methicillin-sensitive *Staphylococcus aureus* infection causing osteomyelitis of the rib and chest wall. Subsequent history taking prompted a discussion whether this infection may have resulted from *S. aureus* colonization of mosquito bites. Patient was given 650 mg of Tylenol which improved their perceived health and stabilized them for transport to University of California, Davis (UCD) where they were admitted. Patient underwent surgical drainage at UCD and was discharged on day nine on oral clindamycin.

On day thirteen the patient attended the recommended hospital follow-up appointment. Physical exam findings included HR: 84bpm, BP: 107/67 mmHg, Tm: 35.9 °C, O2 Sat: 97% on RA. The exam also found the patient to be in no acute distress and alert and oriented; moist mucous membranes in the ears, nose, mouth, and throat; regular heart rate and rhythm, no tachycardia; slight tenderness to the right clavicular region; and no neurological deficits. The patient was prescribed topical mupirocin (2% 3x/day). The patient and their mother were counseled on the natural history of colonization of the skin and potential for cutaneous infections as well as routine care for future small skin infections that may appear.

On day sixteen the patient attended the recommended follow-up appointment. Physical exam findings included HR: 98bpm, BP: 113/72 mmHg, Tm: 35.5 °C, O2 Sat: 98% on RA. Other physical exam findings were consistent with the patient's physical on day thirteen, except, at this visit, the patient did not report any actual or suspected pain of the right clavicular region. The patient had no further symptoms and their wound was improving. Weekly ESR and CRP laboratory tests were ordered for the foreseeable future to track possible methicillin-resistant *S. aureus* remission.

Discussion

Demographics of OM

One of the interesting factors of this particular case was the patient's age. While OM can affect individuals of all ages, a population-based study analyzing the prevalence of this disease in the United States found that the incidence rate of OM in males under 18 years old per 100,000 person-years is 10.9. In adults, the incidence rate of OM rises precipitously, with the highest incidence after the age of 80 years old where the rate is 128.4, making OM likely be diagnosed more frequently among the elderly population than in the pediatric population. [9] Significantly, the patient in this case was only ten years old, making the contraction of OM extremely rare for their age group. Also of note is that these trend of OM occurring more in the elderly population has been proposed to result from the relative frequency at which adults are exposed to infection compared to children. [10] Significantly, the incidence rate of OM in patients under 18 years old has not significantly changed over the last 30 years in the population studied. [9] Aside from age, diabetes has been identified as a major factor for OM in addition to age. It has been reported that diabetic patients' foot ulcers (DFU) are a frequent source for invasion of the pathogen. DFUs occur in 7.02% of patients with Type 2 Diabetes, with amputation leading to 68% of that cohort later developing OM. [11,12] While the patient in this case has not been diagnosed with diabetes or developed DFUs, their BMI, blood glucose levels, and lifestyle are indicative of entering a pre-diabetic state. While this pre-diabetic state could lead a clinician to consider OM as a diagnosis, it must be noted that the physical examination did not observe any DFUs. Their absence would direct a clinician away from an infectious diagnosis such as OM as the site of entry is not present. However, this patient uniquely had OM despite not having the key risk factor of diabetes or DFUs, making this case even more significant for physicians of all specialties to be aware of.

Common and novel symptoms of OM

The clinical presentation of osteomyelitis may vary depending on a myriad of components. This inflammatory process caused by pyogenic organisms may be acute or chronic and differs in presentation between adults and

children. [13] Although each clinical pattern may have its own unique presentation, general symptoms include pain, fever, malaise, and possible erythema near the affected region. [14] The pain is generally noted near the site of infection, however, in rare cases such as osteomyelitis of the ribs, chest, back, and abdominal pain have been previously noted. [15,16]

Pathogens of OM

The pathogenic cause of osteomyelitis is a result from pyogenic organisms including bacteria, mycobacteria, and fungi. Both gram positive and gram negative bacteria have been identified, however, *Staphylococcus aureus* is a frequent causative agent. Other bacterial agents include *Streptococcus pyogenes*, *Streptococcus pneumoniae*, and *Kingella kingae*, *Pseudomonas aeruginosa*, *Enterobacter cloacae*, *Escherichia coli*, *Bartonella henselae*, and *Clostridium* species. [17-20] Although not as common, fungal agents such as *Aspergillus* and *Cryptococcus* have also been observed. [21,22] In addition, cases on osteomyelitis resulting from *Mycobacterium tuberculosis* have further been reported. [23,24]

Insects Bites and Soft Tissue/Skin Infections

In the current case, the mention of the patient's frequent infection of mosquito bites prompted discussions of infection caused by staph colonization of the bites. Aside from anaphylaxis, life threatening conditions from insect bites are usually rare. Although rare, there have been cases skin and soft tissue infections from insect bites. There was a report of upper extremity Volkmann's contracture, a form of compartment syndrome, from a flying insect bite, in a 20 year old woman. [26] A case of compartment syndrome in the calf was also reported in a 29 year old woman. [27] Similar to the patient in the current case, these patients initially presented with pain and swelling in the affected area. In the case of the 29 year old woman, upon admission, she developed signs of septic shock including decreases consciousness, elevated WBC count, and elevated neutrophil count. The current case also described the patients altered level of consciousness and increased WBC and neutrophil counts. While both of these cases of compartment syndrome required surgical intervention, the patients recovered and were able to resume daily life. In other cases, infection from an insect bite had less successful outcomes. An otherwise healthy man developed necrotizing fasciitis following a tick bite. [28] As with the patient in the current case, this man presented with pain and swelling and eventually showed signs of septic shock. However, that patient died 48 hours after presenting to the hospital.

Treatment of OM

Osteomyelitis is frequently treated with antibiotics and surgery, if necessary. With oral and IV antibiotics available, there may be considerations of efficacy and practicality when choosing a route of administration. A study conducted in Italy found that oral antibiotics in the treatment of osteomyelitis in adults was non-inferior to IV therapy. [29] In cases of hand osteomyelitis in pediatric patients, most cases were managed with oral antibiotics as the primary treatment or secondary to surgery. There was one patient, reported in the literature, however, that needed to be treated with IV antibiotics due to concurrent cellulitis. [30] The patient in the current case was initially treated with IV antibiotics to manage the infection, but eventually needed surgery, which was followed up with postoperative oral antibiotics. It is possible that IV antibiotics were deemed necessary due to the novelty and severity of the patient's case. However, it is interesting to consider if oral antibiotics could have been as equally successful in initially managing the infection.

Conclusion

This case report presents a rare occurrence of osteomyelitis infection of the rib in a pediatric patient. The patient's status declined rapidly after an initial

presentation to the emergency room, exhibiting signs of tachycardia and delirium. Through this report, providers can be better informed to identify presentations of osteomyelitis in children in a timely manner.

Acknowledgements

None to State

References

- Popescu, B., et al., *Acute hematogenous osteomyelitis in pediatric patients: epidemiology and risk factors of a poor outcome*. J Int Med Res, 2020. 48(4): p. 300060520910889.
- Knox, J., A.C. Uhlemann, and F.D. Lowy, *Staphylococcus aureus infections: transmission within households and the community*. Trends Microbiol, 2015. 23(7): p. 437-44.
- Rhodes, J.T., et al., *Orthopedics*, in *Current Diagnosis & Treatment: Pediatrics, 25e*, W.W. Hay Jr, et al., Editors. 2020, McGraw-Hill Education: New York, NY.
- Peltola, H. and M. Paakkonen, *Acute osteomyelitis in children*. N Engl J Med, 2014. 370(4): p. 352-60.
- Hawkshead, J.J., 3rd, et al., *Comparative severity of pediatric osteomyelitis attributable to methicillin-resistant versus methicillin-sensitive Staphylococcus aureus*. J Pediatr Orthop, 2009. 29(1): p. 85-90.
- Guillerman, R.P., *Osteomyelitis and beyond*. Pediatr Radiol, 2013. 43 Suppl 1: p. S193-203.
- Lammin, K.A., Taylor, J., Zenios, M., *The usefulness Of CRP and ESR In diagnosing long bone osteomyelitis in children - are we being falsely reassured?* Orthopaedic Proceedings, 2012. 94-B(SUPP_XXXIX): p. 156-156.
- Raffaelli, G., et al., *Abdominal mass hiding rib osteomyelitis*. Ital J Pediatr, 2016. 42: p. 37.
- Kremers, H. M., Nwojo, M. E., Ransom, J. E., Wood-Wentz, C. M., Melton, L. J., 3rd, & Huddleston, P. M., 3rd (2015). Trends in the epidemiology of osteomyelitis: a population-based study, 1969 to 2009. *The Journal of bone and joint surgery. American volume*, 97(10), 837–845. <https://doi.org/10.2106/JBJS.N.01350>
- Cunha B. A. (2002). Osteomyelitis in elderly patients. *Clinical infectious diseases : an official publication of the Infectious Diseases Society of America*, 35(3), 287–293. <https://doi.org/10.1086/341417>
- Younis, B.B., Shahid, A., Arshad, R. et al. Frequency of foot ulcers in people with type 2 diabetes, presenting to specialist diabetes clinic at a Tertiary Care Hospital, Lahore, Pakistan. *BMC Endocr Disord* **18**, 53 (2018). <https://doi.org/10.1186/s12902-018-0282-y>
- Gregg EW, Li Y, Wang J, Burrows NR, Ali MK, Rolka D, Williams DE, Geiss L. Changes in diabetes-related complications in the United States, 1990-2010. *N Engl J Med*. 2014. April 17;370(16):1514-23
- Momodu II, Savaliya V. Osteomyelitis. [Updated 2022 May 12]. In: StatPearls [Internet]. Treasure Island (FL): StatPearls Publishing; 2022 Jan-. Available from: <https://www.ncbi.nlm.nih.gov/books/NBK532250/>
- Urish KL, Cassat JE. Staphylococcus aureus Osteomyelitis: Bone, Bugs, and Surgery. *Infect Immun*. 2020 Jun 22;88(7):e00932-19. doi: 10.1128/IAI.00932-19. PMID: 32094258; PMCID: PMC7309607.
- Nascimento M, Oliveira E, Soares S, Almeida R, Espada F. Rib osteomyelitis in a pediatric patient case report and literature review. *Pediatr Infect Dis J*. 2012 Nov;31(11):1190-4. doi: 10.1097/INF.0b013e318266ebe8. PMID: 22760539.
- Cunningham RJ. Osteomyelitis of the Ribs. *Br Med J*. 1963 Nov 2;2(5365):1128-9. doi: 10.1136/bmj.2.5365.1128-c. PMID: 14057722; PMCID: PMC1873241.
- Lew DP, Waldvogel FA. Osteomyelitis. *Lancet*. 2004 Jul 24-30;364(9431):369-79. doi: 10.1016/S0140-6736(04)16727-5. PMID: 15276398.
- Funk SS, Copley LA. Acute Hematogenous Osteomyelitis in Children: Pathogenesis, Diagnosis, and Treatment. *Orthop Clin North Am*. 2017 Apr;48(2):199-208. doi: 10.1016/j.ocl.2016.12.007. PMID: 28336042.
- Sakellaris G, Kampitakis E, Karamitopoulou E, et al. Cat scratch disease simulating a malignant process of the chest wall with coexistent osteomyelitis. *Scand J Infect Dis*. 2003;35(6-7):433-435. doi: 10.1080/00365540310012262
- Balamohan A, Buchmann RF. Osteomyelitis of the Rib in a Child With Indolent Symptoms. *Glob Pediatr Health*. 2022 Apr 5;9:2333794X221086583. doi: 10.1177/2333794X221086583. PMID: 35400018; PMCID: PMC8990543.
- Mamishi S, Zomorodian K, Saadat F, Gerami-Shoar M, Tarazooie B, Siadati SA. A case of invasive aspergillosis in CGD patient successfully treated with Amphotericin B and INF-gamma. *Ann Clin Microbiol Antimicrob*. 2005 Mar 3;4:4. doi: 10.1186/1476-0711-4-4. PMID: 15745454; PMCID: PMC555544.
- Raftopoulos I, Meller JL, Harris V, Reyes HM. Cryptococcal rib osteomyelitis in a pediatric patient. *J Pediatr Surg*. 1998 May;33(5):771-3. doi: 10.1016/s0022-3468(98)90216-0. PMID: 9607497.
- Chong SG, Herron M, Dolan L, McDonald C, O'Donnell R, Fahy RJ, Keane J, McLaughlin AM. TB osteomyelitis. *QJM*. 2016 Nov;109(11):751-752. doi: 10.1093/qjmed/hcw166. Epub 2016 Sep 21. PMID: 27736741.
- Lebowitz D, Wolter L, Zenklusen C, Chouiter A, Malinverni R. TB determined: tuberculous osteomyelitis. *Am J Med*. 2014 Mar;127(3):198-201. doi: 10.1016/j.amjmed.2013.12.001. Epub 2013 Dec 12. PMID: 24333617.
- Martini M, Hannachi MR, Boudjemaa A. Tuberculosis of bone. Tuberculous osteomyelitis. *Acta Orthop Belg*. 1981 Jan-Feb;47(1):95-103. PMID: 7293762.
- Hardwicke, J., & Srivastava, S. (2013). Volkmann's contracture of the forearm owing to an insect bite: a case report and review of the literature. *Annals of the Royal College of Surgeons of England*, 95(2), e36–e37. <https://doi.org/10.1308/003588413X13511609955210>
- Wang, J., Duan, Q., Sun, X., Mou, X., Song, B., & Yuan, H. (2018). Acute compartment syndrome of the leg due to infection following an insect bite: A case report. *Medicine*, 97(30), e11613. <https://doi.org/10.1097/MD.0000000000011613>
- Fernando, D. M., Kaluarachchi, C. I., & Ratnatunga, C. N. (2013). Necrotizing fasciitis and death following an insect bite. *The American journal of forensic medicine and pathology*, 34(3), 234–236. <https://doi.org/10.1097/PAF.0b013e3182a18b0b>

29. Melis, F., De Vito, A., Fiore, V., Rostagno, R., Ravera, L., Babudieri, S., Borrè, S., & Madeddu, G. (2022). Is oral antibiotic therapy as effective as intravenous treatment in bacterial osteomyelitis? A real-life experience. *European review for medical and pharmacological sciences*, 26(11), 4069–4073. https://doi.org/10.26355/eurrev_202206_28976
30. Kargel, J. S., Sammer, D. M., Pezeshk, R. A., & Cheng, J. (2020). Oral Antibiotics Are Effective for the Treatment of Hand Osteomyelitis in Children. *Hand (New York, N.Y.)*, 15(2), 220–223. <https://doi.org/10.1177/1558944718788666>



This work is licensed under Creative Commons Attribution 4.0 License

To Submit Your Article Click Here:

Submit Manuscript

DOI: [10.31579/2692-9406/131](https://doi.org/10.31579/2692-9406/131)

Ready to submit your research? Choose Auctores and benefit from:

- fast, convenient online submission
- rigorous peer review by experienced research in your field
- rapid publication on acceptance
- authors retain copyrights
- unique DOI for all articles
- immediate, unrestricted online access

At Auctores, research is always in progress.

Learn more <https://www.auctoresonline.org/journals/biomedical-research-and-clinical-reviews->