

Immune Checkpoint Inhibitor Mediated Myocarditis: A Case Report

Carrie L Cicirale

Barnes Jewish Hospital, USA.

Corresponding Author: Carrie L Cicirale, Barnes Jewish Hospital, USA.

Received Date: August 12, 2022; **Accepted Date:** August 25, 2021; **Published Date:** August 31, 2022

Citation: Carrie L Cicirale (2022). Immune Checkpoint Inhibitor Mediated Myocarditis: A Case Report, *J. Clinical Cardiology and Cardiovascular Interventions*, 5(8); DOI:10.31579/2641-0419/275

Copyright: © 2022 Carrie L Cicirale, This is an open-access article distributed under the terms of the Creative Commons Attribution License, which permits unrestricted use, distribution, and reproduction in any medium, provided the original author and source are credited.

Abstract

This is a case report describing an 83-year-old male with suspected immune checkpoint inhibitor mediated myocarditis after two cycles of ipilimumab and nivolumab. The patient was treated with intravenous (IV) steroids after other common causes of his symptoms were ruled out. While the patient's lab values reflected a slight treatment response, ultimately the patient expired due to progression of symptoms. Myocarditis due to immune checkpoint inhibitor therapy is a rare but fatal occurrence, and more data is needed to determine the optimal treatment and dosing strategy.

Keywords: cardiology; oncology; immune checkpoint inhibitors; myocarditis

Introduction

Immune checkpoint inhibitors are antineoplastic medications prescribed for the treatment of various malignancies, including breast, bladder, cervical, colon, head and neck, Hodgkin lymphoma, liver, lung, renal, skin, stomach, and rectal cancers. Most commonly prescribed medications within this class include ipilimumab and nivolumab, however there are several other agents available, including avelumab, pembrolizumab, atezolizumab, cemiplimab, and durvalumab [1]. Their mechanism acts on immune negative regulation receptors, such as cytotoxic T-lymphocyte associated protein 4 (CTLA-4), programmed cell death receptor 1 (PD-1), and programmed cell death ligand 1 (PD-L1) [2]. While these medications can be effective in their treatment of malignancies, they unfortunately are associated with many autoimmune related adverse drug events, least common of which are cardiotoxicities like myocarditis [3]. Cardiotoxicity related to immune checkpoint inhibitors occurs about in about 1.14% of patients receiving this therapy. Myocarditis occurs most frequently in patients taking a combination of ipilimumab and nivolumab. It is hypothesized that cardiotoxicity can occur due to the role that PD-1 and PD-L1 receptors have in the immune system of the myocardium [4].

Median onset to myocarditis development is after one to two infusions of the medication. If myocarditis does occur, mortality rates can range from 25 to 50%, and this increases further if patients are receiving more than one immune checkpoint inhibitor. Diagnosis is made by utilizing multiple imaging procedures, including cardiac magnetic resonance imaging (MRI) and endomyocardial biopsies [1]. Cardiac MRI findings indicative of immune checkpoint inhibitor mediated myocarditis include myocardial edema and non-ischemic myocardial injury. Often found on biopsy results are inflammatory infiltrates and myocardial necrosis, similar to what may

be seen in a heart transplant experiencing acute rejection [5]. Troponin and brain-type natriuretic peptide (BNP) are measured to predict prognosis and guide treatment decisions. It is important to recognize and diagnosis this condition quickly in order to begin treatment and improve patient outcomes [4].

Case Report

This patient was an 83-year-old male who presented to the emergency department with generalized weakness. His past medical history included hypertension, hyperlipidemia, chronic kidney disease, chronic obstructive pulmonary disease, benign prostatic hyperplasia, coronary artery disease with a history of ST elevation myocardial infarction, heart failure with persevered ejection fraction, and a newly diagnosed case of adenocarcinoma to the lung and renal cell carcinoma, in which he was prescribed ipilimumab and nivolumab. As of this admission, the patient had two cycles of the chemotherapy. After the most recent infusion of ipilimumab and nivolumab, the patient described feeling short of breath and weak and experienced lower extremity edema. The patient was admitted and transferred to the cardiac intensive care unit (ICU) for treatment.

Upon evaluation of his physical exam, he was noted to have crackles bilaterally, lower extremity edema bilaterally, and jugular vein distention. As far as the patient's social history, he reported no illicit drug or alcohol use and has never smoked. He did not report any allergies to any medications. In addition to the immune checkpoint inhibitor therapy he was receiving, his home medications included aspirin, atorvastatin, bisoprolol, finasteride, fluticasone/umeclidinium/vilanterol inhaler, and furosemide. The patient's electrocardiogram (ECG) showed left bundle branch block and ST elevations (Figure 1).

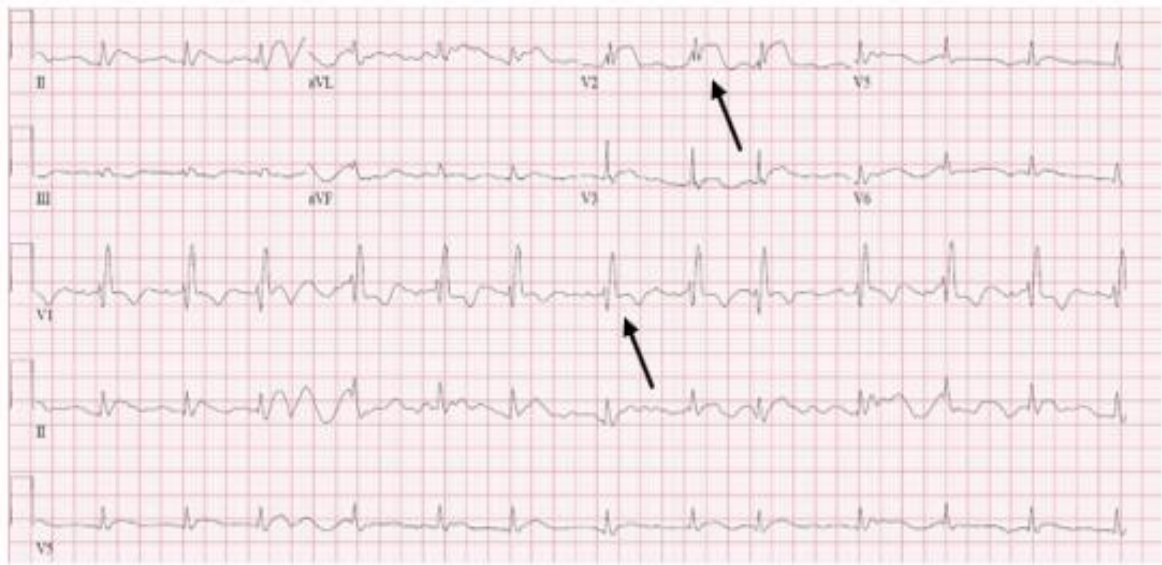


Figure 1: depicts the patient's electrocardiogram, which revealed left bundle branch blocks and ST elevations.

The patient's transesophageal echocardiogram revealed an ejection fraction of 50%, along with a dilated right ventricle, mild to moderate tricuspid regurgitation, and a small pericardial effusion.

The patient's chest x-ray showed mild cardiomegaly, interstitial edema, pleural thickening, and a right sided infiltrate (Figure 2).

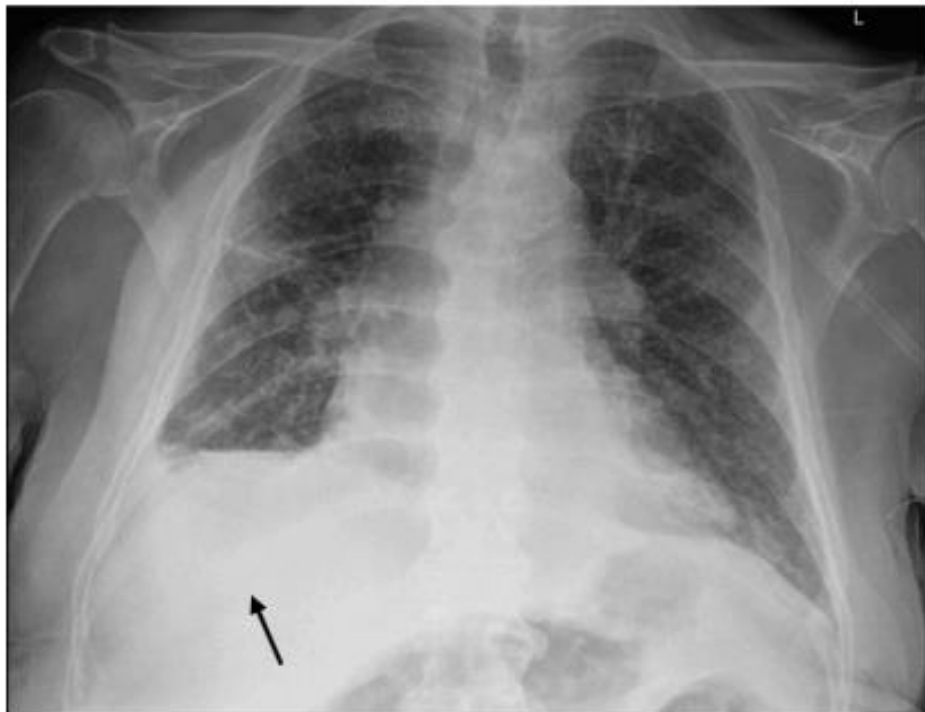


Figure 2: depicts the patient's chest x-ray, which revealed mild cardiomegaly, interstitial edema, pleural thickening, and a right sided infiltrate.

Pertinent labs on admission include a troponin of 31.39 nanograms per deciliter (ng/dL), a BNP of 1919 picograms per milliliter (pg/dL), a serum creatinine (SCr) of 2.51 milligrams per deciliter (mg/dL). D dimer was within normal limits, ruling out possible pulmonary embolism (PE). The patient's baseline SCr was 1.3 mg/dL, therefore this patient was presenting with an acute kidney injury (AKI). The AKI did resolve throughout the admission, and the patient's SCr returned to baseline. The

patient received a cardiac catheterization due to the ST elevations seen on ECG, and this revealed a patent stent to the right coronary artery (RCA) and no significant coronary artery disease in any of the patient's coronary vessels. Since acute coronary syndrome was ruled out, a positron emission tomography (PET) scan was ordered to evaluate for possible myocarditis related to the patient's immune checkpoint inhibitor therapy. Unfortunately, while patient was being taken to the PET scan, he

experienced atrial fibrillation (Afib) with rapid ventricular rate (RVR) and the test was canceled.

The team decided to move forward with treatment for myocarditis despite not being able to receive the planned diagnostic imaging. There were various discussions had to determine which dose of steroids, specifically methylprednisolone, would be optimal for this patient's treatment. The cardiology team opted for higher doses of 1000 milligrams (mg) daily, while the oncology team preferred lower doses of one mg per kilogram

(kg) of methylprednisolone daily given the risk of adverse drug reactions like increased risk of infection and hyperglycemia [2]. Based on compromise made from the cardiology and oncology teams, as well as pharmacy input and extensive literature review, he was administered intravenous (IV) methylprednisolone 160 mg, equaling two mg/kg, for three days with a plan to taper over four to six weeks based on the patient's troponin level trends in response to the treatment [2]. The patient's troponin trended down after administration of methylprednisolone (figure 3).

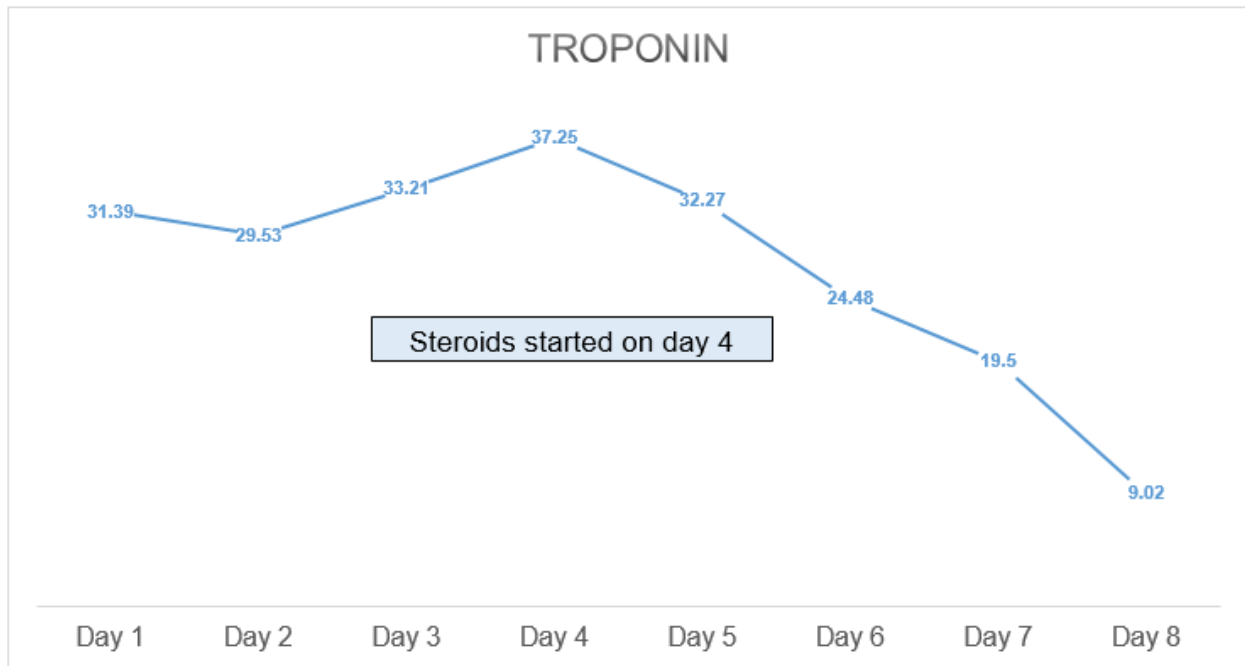


Figure 3: highlights the changes in troponin before and after administration of steroids to the patient. Once treated with steroids, the patient experienced a decrease in troponin levels.

After three days, the patient's troponin levels continued to trend down, and the dose of methylprednisolone was decreased to 140 mg daily. The plan was to administer three days of this dose and to continue to taper based on his troponin response, however the patient unfortunately expired on day five of treatment, likely due to the progression of myocarditis. While his troponin levels were responding to the steroids, his symptoms did not improve.

Discussion

There are other potential treatment options this patient could have trialed if the use of methylprednisolone had failed, such as plasmapheresis, alemtuzumab, abatacept, mycophenolate, infliximab, anti-thymocyte globulin, however the data is limited on the success of these therapies and some are also associated with cardiotoxicities in their side effect profile [1]. The studies that are published that examine the treatment of immune checkpoint inhibitor mediated myocarditis most often report use of IV methylprednisolone at various doses. Monitoring the treatment response of steroids via troponin trends is reported in the literature frequently [2]. However, this particular patient experienced a downward trend in troponin without an equivalent clinical response. Symptoms persisted and

the patient expired, unable to complete the planned course of steroids. Discussion following the patient's death revolved around if the IV methylprednisolone was given too late and if the dose was enough to lead to a significant recovery. Unfortunately, autoimmune adverse drug reactions like myocarditis, while rare, can be life threatening in patients receiving immune checkpoint inhibitors [5]. Early detection, aggressive

steroid management, supportive care, and discontinuation of the culprit medication are the ideal ways to treat patients with this condition based on limited literature available on this topic [2]. Currently, the data available regarding the treatment of this condition is limited to case reports and case series. Larger trials should be conducted to further investigate the best treatment options for future patients who experience this life threatening adverse reaction to their chemotherapy [2].

Conflicts of Interest

The author declares that there are no actual or potential conflicts of interest in the research.

Acknowledgements

Nicholas Servati, PharmD, BCCP and Richard Rovelli, PharmD

References

1. Palaskas N, Lopez-Mattei J, Bernard Durand J, Illiescu C, Deswal A. Immune checkpoint inhibitor myocarditis: pathophysiological characteristics, diagnosis, and treatment. *J Am Heart Assoc.* 2020;9:e013757.
2. Osinga TE, Oosting SF, van der Meer P, et al. Immune checkpoint inhibitor-associated myocarditis Case reports and a review of the literature. *Neth Heart J.* 2022;30:295-301.
3. Makunts T, Saunders IM, Cohen IV, et al. Myocarditis occurrence with cancer immunotherapy across indications in clinical trial and post-marketing data. *Sci Rep.* 2021;17324.

4. McDowall LM, Fernando SL, Ange N, Yun J, Chia KKM. Immune checkpoint inhibitor–mediated myocarditis and ventricular tachycardia storm. *Heart Case Rep.* 2019;5(10):497-500.
5. Javid Moslehi, Andrew H. Lichtman, Arlene H. Sharpe, Lorenzo Galluzzi. Immune checkpoint inhibitor–associated myocarditis: manifestations and mechanisms. *J Clin Invest.* 2021;131(5):e145186.



This work is licensed under Creative Commons Attribution 4.0 License

To Submit Your Article Click Here:

Submit Manuscript

DOI: [10.31579/2641-0419/275](https://doi.org/10.31579/2641-0419/275)

Ready to submit your research? Choose Auctores and benefit from:

- fast, convenient online submission
- rigorous peer review by experienced research in your field
- rapid publication on acceptance
- authors retain copyrights
- unique DOI for all articles
- immediate, unrestricted online access

At Auctores, research is always in progress.

Learn more <https://auctoresonline.org/journals/clinical-cardiology-and-cardiovascular-interventions>