

# Sentinel Node in Endometrial Cancer. Metastatic Pathways

**Chrisostomos Sofoudis**

Ippokratous 209, 11472, Athens, Greece.

**Corresponding Author:** Chrisostomos Sofoudis MD, Ippokratous 209, 11472, Athens, Greece.

**Received Date:** 16 July 2022 | **Accepted Date:** 29 July 2022 | **Published Date:** 04 August 2022

**Citation:** Chrisostomos Sofoudis. (2022). Sentinel Node in Endometrial Cancer. Metastatic Pathways. *Journal of Clinical Surgery and Research*, 3(5); DOI:10.31579/2768-2757/056

**Copyright:** © 2022 Chrisostomos Sofoudis. This is an open access article distributed under the Creative Commons Attribution License, which permits unrestricted use, distribution, and reproduction in any medium, provided the original work is properly cited.

## Abstract:

Endometrial cancer represents the second most frequent malignant entity among gynecologic malignancies. Many predisposition factors reflect and affect the chronological outcome of the lesion. Age of the patient, obesity, postmenopausal vaginal bleeding among with endometrial hyperplasia, histologic type, grading, staging, vascular or lymph node penetration consist factors with direct depiction concerning the therapeutic mapping. Sentinel node consists the first regional lymph node infiltration, indicating local or external spread of the lesion. In order to explore and investigate potential infiltration or metastatic capability of the lesion, sentinel node infiltration represents optimal solution. According to current literature, sentinel node infiltration depicts increased sensitivity and specificity concerning surgical or conservative therapeutic management. Aim of our study represents assiduous decoding of sentinel node infiltration and potential metastatic pathways, with ultimate scope the increased optimal survival and quality of life of the patient.

**keywords:** sentinel node; endometrial cancer; staging; grading

## Introduction:

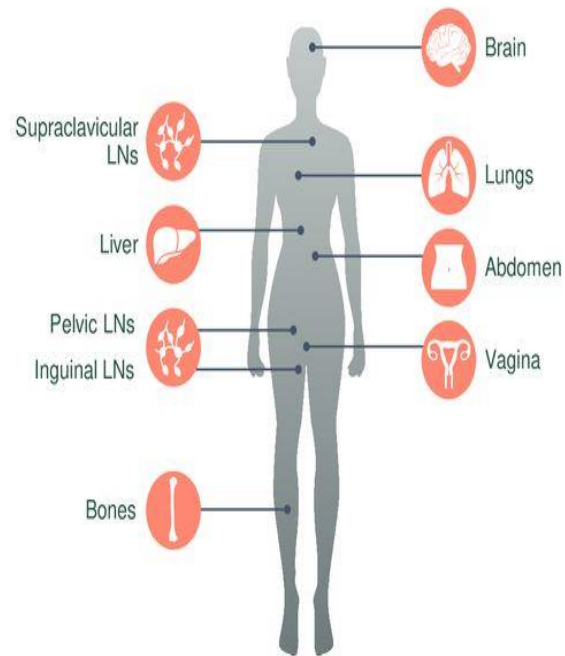
According to current literature, endometrial cancer consists the 2nd most common gynecologic malignancy in developed countries. [1] Focusing on imaging depiction and assiduous reflection of all predisposition

factors, most of cases are nearly diagnosed. [2] Endometrial cancer classification remains the most diagnostic tool regarding the therapeutic mapping of such cases. (Table I.)

# FIGO Staging Is the Most Commonly Used Staging System for Endometrial Cancer

Stage <sup>a</sup>	Stage Definitions
I	<p><b>Tumor confined to the corpus uteri</b></p> <ul style="list-style-type: none"> <li>IA: No or less than half myometrial invasion</li> <li>IB: Invasion equal to or more than half of the myometrium</li> </ul>
II	<p><b>Tumor invades cervical stroma, but does not extend beyond the uterus<sup>b</sup></b></p>
III	<p><b>Local and/or regional spread of the tumor</b></p> <ul style="list-style-type: none"> <li>IIIA: Tumor invades the serosa of the corpus uteri and/or adnexae<sup>c</sup></li> <li>IIIB: Vaginal and/or parametrial involvement<sup>c</sup></li> <li>IIIC1: Metastases to pelvic lymph nodes<sup>c</sup></li> <li>IIIC2: Metastases to para-aortic lymph nodes with or without positive pelvic lymph nodes<sup>c</sup></li> </ul>
IV	<p><b>Tumor invades bladder and/or bowel mucosa, and/or distant metastases</b></p> <ul style="list-style-type: none"> <li>IVA: Tumor invasion of bladder and/or bowel mucosa</li> <li>IVB: Distant metastases, including intra-abdominal metastases and/or inguinal lymph nodes</li> </ul>

## Most Common Sites of Metastatic Spread



<sup>a</sup> Either grade 1, grade 2, or grade 3. <sup>b</sup> Endocervical glandular involvement only should be considered stage I.

<sup>c</sup> Positive cytology has to be reported separately without changing the stage.

FIGO, International Federation of Gynecology and Obstetrics; LN, lymph node.

NCI. Endometrial Cancer Treatment (PDQ<sup>®</sup>) – Health Professional Version. <https://www.cancer.gov/types/uterine/hp/endometrial-treatment-pdq#section/all>. Updated January 19, 2018. Accessed January 8, 2019.

**Figure 1: FIGO Endometrial Cancer Classification. Gemstone Oncology**

Among age of the patient, staging, grading, postmenopausal bleeding, histologic type, lymph node infiltration presents as most significant prognostic factor. [3]

Optimal treatment of endometrial cancer consists total abdominal hysterectomy accompanied with bilateral salpingo oophorectomy. Further surgical intervention is strongly adjusted with the lymphatic infiltration and the staging of the lesion. In cases of more than 50 % of myometrial invasion, bilateral lymphadenectomy should be performed. [3] Many conducted studies have proposed in cases of advanced stages, series of chemotherapy with radiotherapy, combined with hormonal therapy when estrogen and progesterone receptors were found positive. [4] Sentinel node consists as primary lymphatic external spread of each malignant entity. [5] Many recent studies have been conducted mostly in areas such breast malignancies or melanomas with great successful therapeutic management. Cutaneous melanomas presented as primary malignancies

in which SLN mapping depicted worldwide acceptance. In cases of vulvar cancer SLN mapping managed to bring promising results in order to establish more precise therapeutic strategy.

Radio colloid and blue dye SLN mapping were first described in the early 1990s.

Lymphoscintigraphy in the early 1980s was initially used for SLN mapping in breast malignancies. Since 1977, SLN mapping procedures have been included in the treatment for a number of types of tumor, including vulvar, breast, anal, colon, skin, gastric, penile, esophageal, bladder, prostatic neoplasm and non-small cell lung cancer.

According to current bibliography, SLN mapping was depicted with Technetium Radio colloid (<sup>99</sup>Tc) alone or with blue dyes. Besides the daily use of these substances, many side effects were described. [6]

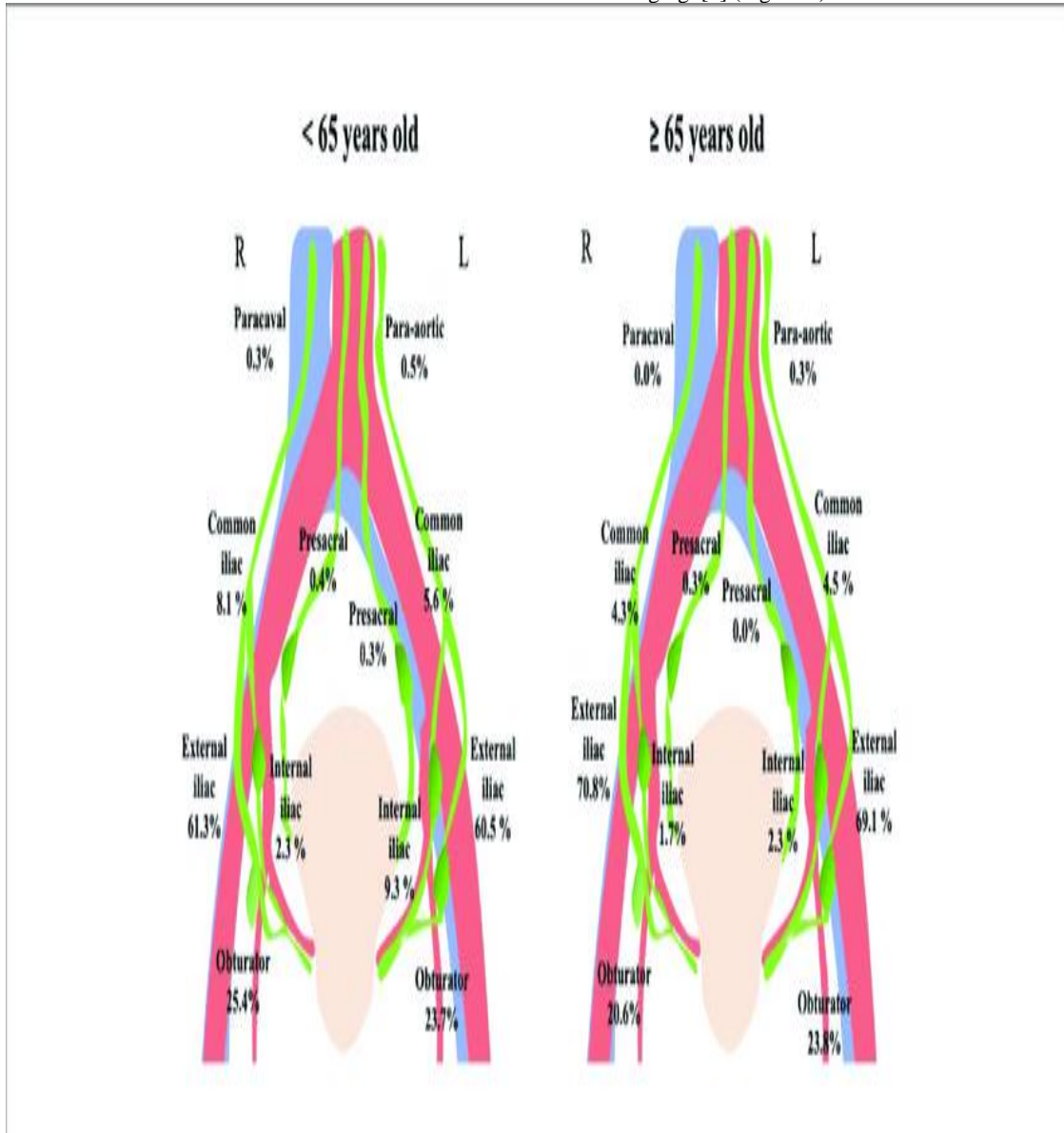
In many cases, skin and urine discoloration or allergic reactions were presented. Indocyanine green (ICG) consists an intravascular fluorescent dye, optimal tool concerning the visualization of retinal and choroid vascularization. [6]

**Discussion**

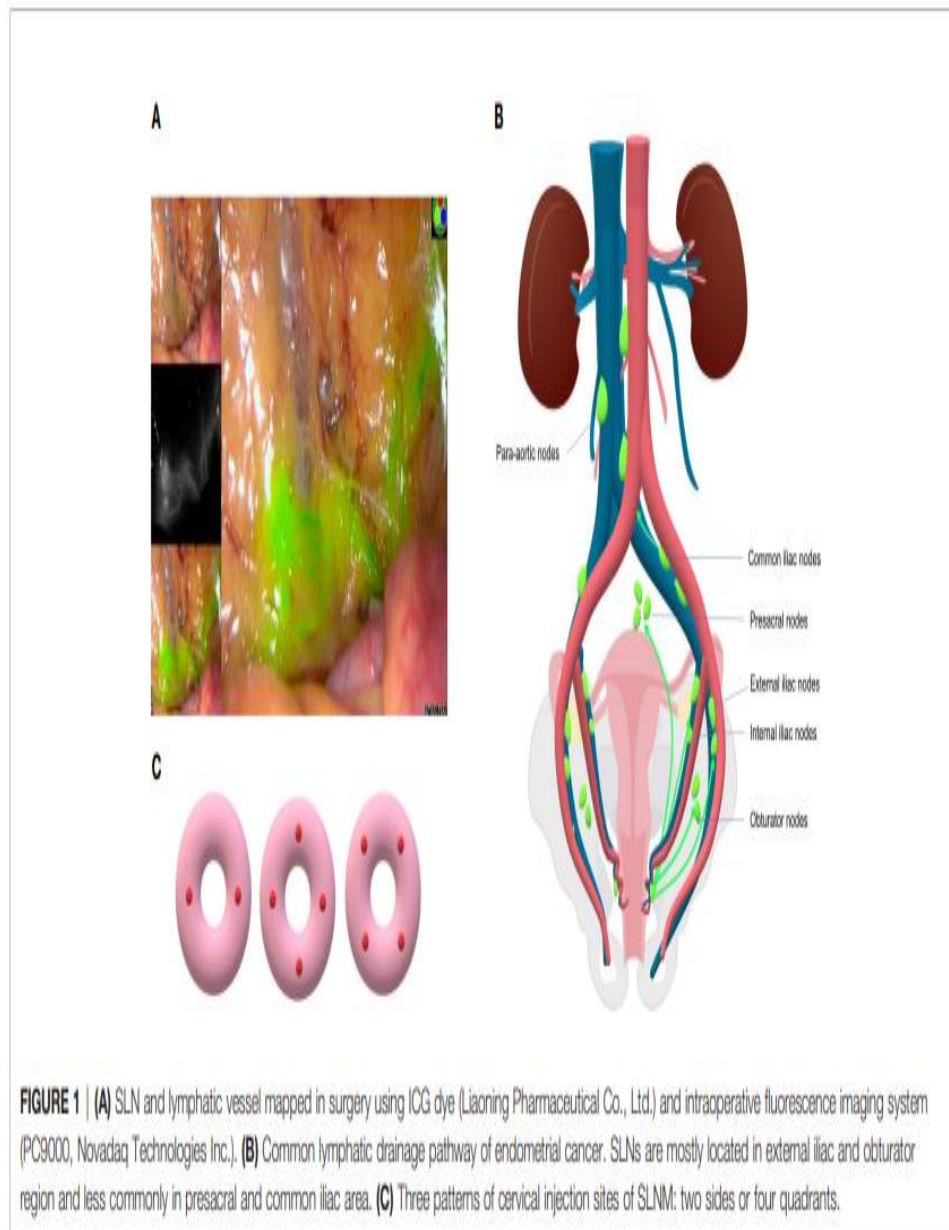
Many recent conducted studies, establish ICG as screening tracer regarding the SLN (Sentinel Node) mapping in endometrial cancer. Indocyanine green (ICG) consists a tricarbocyanine dye which can lead to emission of a fluorescent signal in the infrared light range capable of

detecting the first lymphatic drainage concerning cases of endometrial cancer. Fluorescence-guided imaging with ICG has a number of advantages, compared with conventional methods, including real-time lymphography, a low incidence of adverse reactions and an increased sensitivity, without requiring radiation.

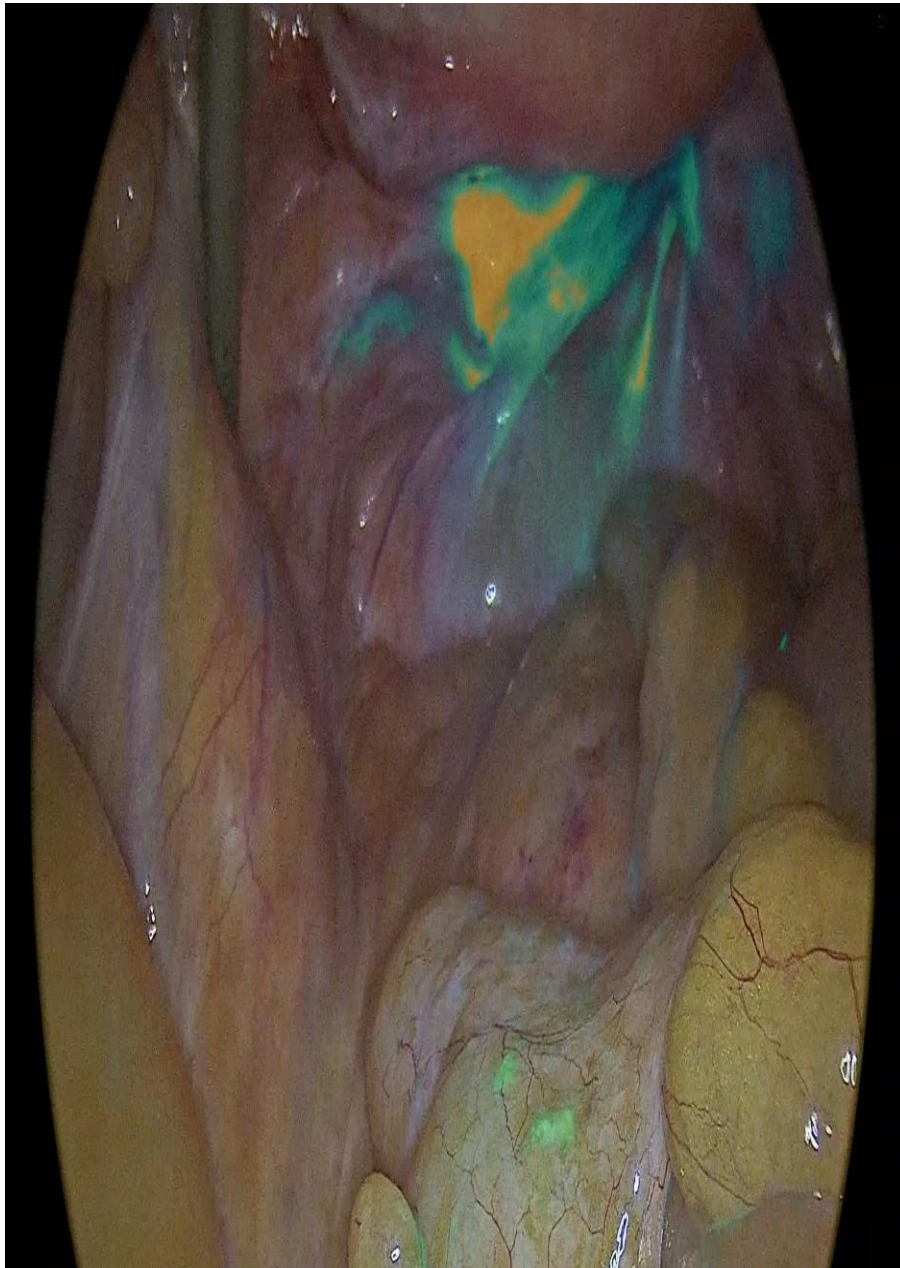
Isolation and detection of SLN biopsy enables complete mapping of potential lymphatic infiltration. [7] Besides the low rate of lymphatic invasion in early stages of endometrial malignancies, complete lymphadenectomy represents ultimate scope of precise endometrial cancer staging. [7] (Figure 1.)



**Figure 2:** Anatomic localizations of lymph nodes. Cianci S, Rosati A, Vargiu V, Capozzi VA, Sozzi G, Giò A, Gueli Alletti S, Ercoli A, Cosentino F, Berretta R, Chiantera V, Scambia G and Fanfani F (2021) Sentinel Lymph Node in Aged Endometrial Cancer Patients “The SAGE Study”: A Multicenter Experience. *Front. Oncol.* 11:737096.



**Figure 3:** Sentinel lymph node drainage in endometrial cancer. Sentinel Lymph node mapping in endometrial cancer: a comprehensive review. Zhai et al. *Front. Oncol.*, 29 June 2021



**Figure 4:** Sentinel node depiction after ICG application. Laparoscopic sentinel node mapping complicating endometrial cancer. Report of three cases and systematic review of the literature. Sofoudis C, Syrios K, Oikonomidis M, Betas P, Zioris K. *Obstet Gynecol Int J* 2022;13(2):135-138

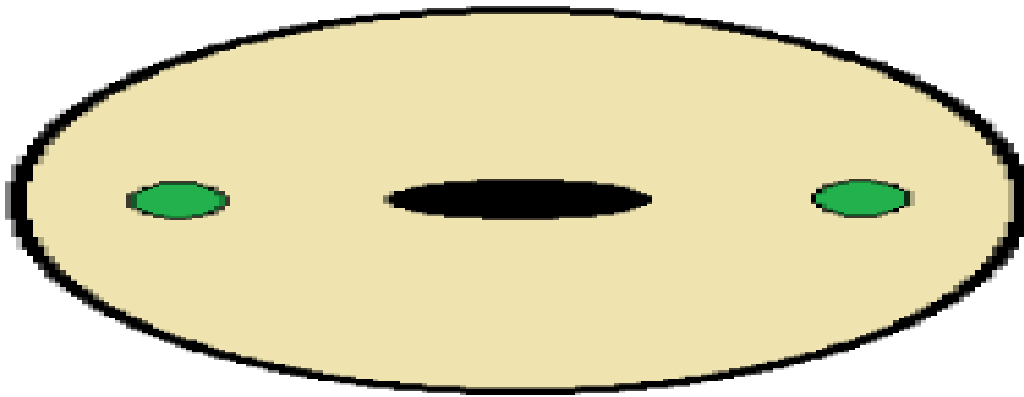
Lymph node staging and lymph vascular invasion and infiltration consist without doubt ultimate prognostic factors. [8]

Myometrial infiltration is strongly accompanied with nodal metastasis. Recent literature depicts nodal metastasis less than 3% in cases with less than 50% myometrium infiltration. [9]

Due to anatomic area of the uterus (midline structure), lymphatic spread divides into bilateral pelvic lymph nodes. On the other side, depiction of one at least SLN in every hemi pelvis area, underlies the significance of

SLN mapping. Many conducted studies raised from current literature, perform different ways of injecting ICG. Optimal decoding of these manuscripts underlies the significance of the pathophysiologic mechanism.

The injection is diffused around 3<sup>rd</sup> and 9<sup>th</sup> para cervical hour, before setting and beginning of the laparoscopic exploration. (0,5-1ml superficial/1-3mm) and (0,5-1ml in depth/1-2cm) (Figure III.) [10]

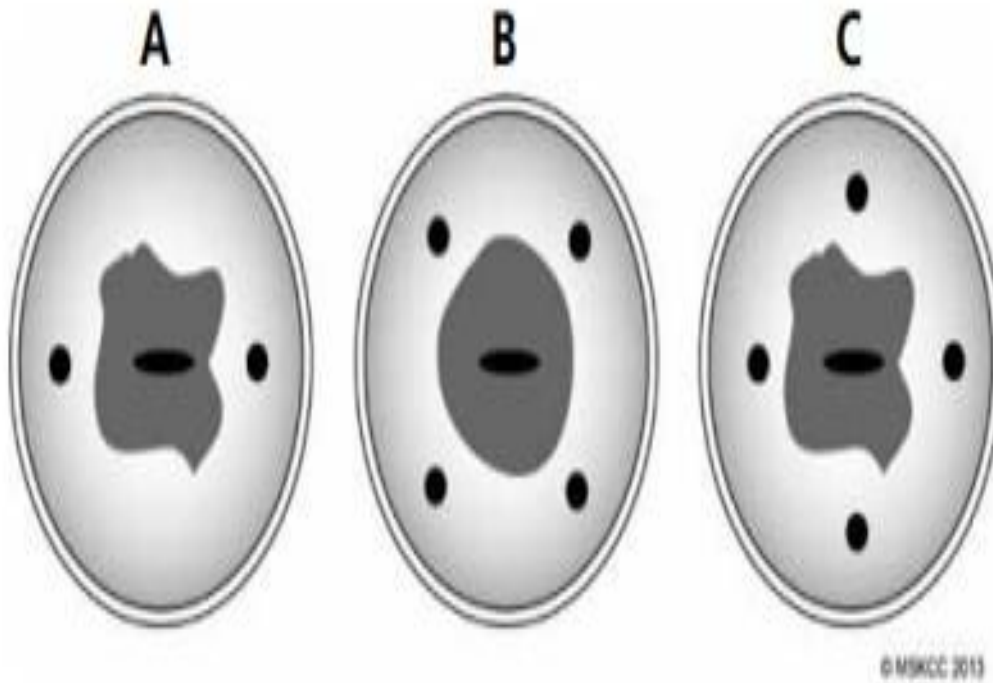


**Figure 5:** Tracer injection at 3 and 9 o'clock positions in the cervix. Alessandri F, Tantari M, Barra F, Vellone VG, Gustavino C, Ferrero S, Centurioni MG (2018) Images from sentinel lymph node mapping with near infrared fluorescence during robot-assisted laparoscopic hysterectomy for suspicious of cervical cancer. Surg Rehabil. 2: DOI: 10.15761/SRJ.1000151

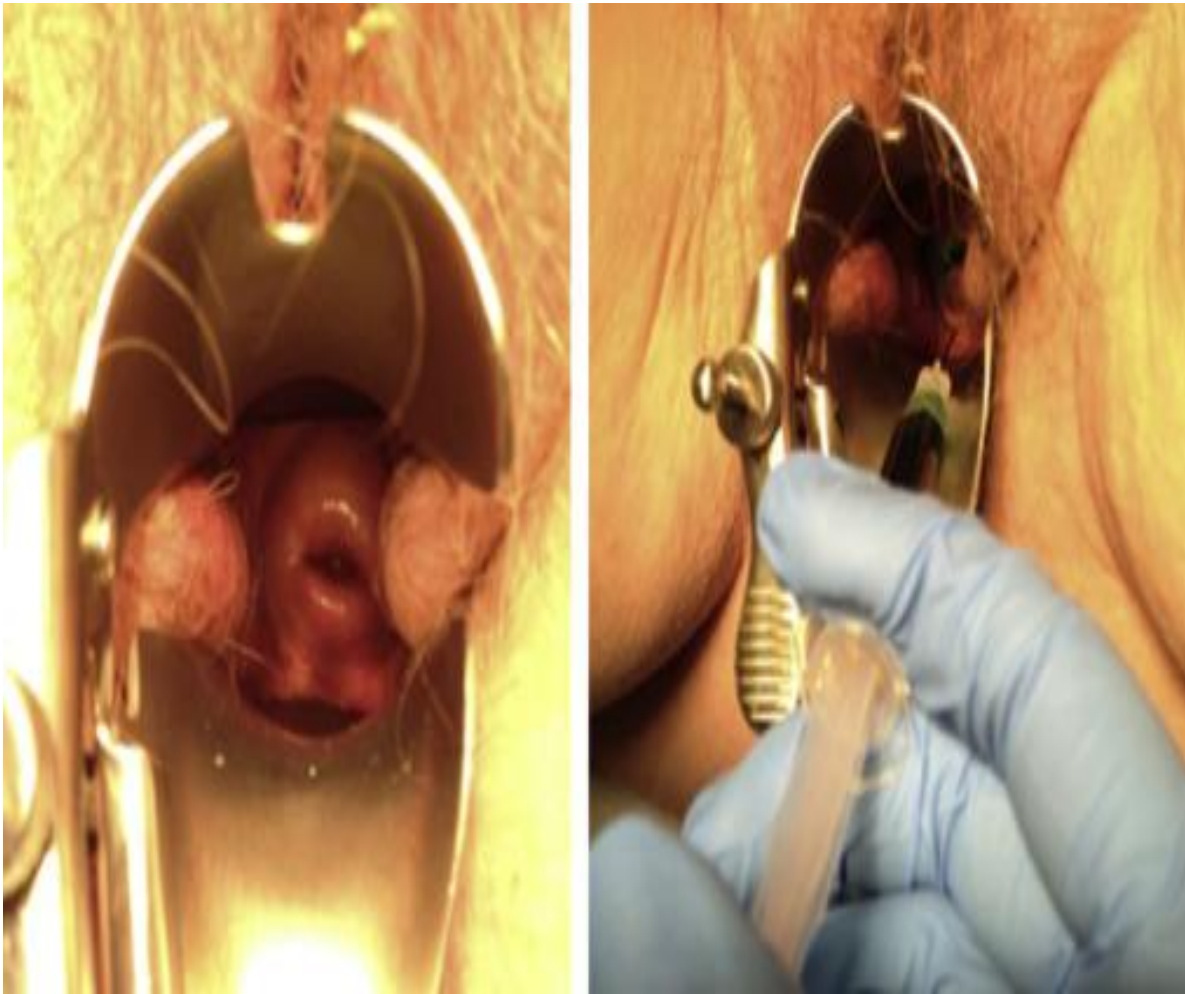
An alternative injection method represents the four clock positions. In many cases the injections were placed intracervical at 2,4,8,10 o'clock positions. (Figure IV.) [10]

Only obstacle presented by cervical method depicts the decreased para-aortic detection rate in comparison with the endometrial method via hysteroscopy. [11]

Pathophysiologic mechanism of this method reflects the avoidance of ICG into the cervical arteries which can lead to diffusion of the dye into the systematic circulation causing many operative complications. [12]



**Figure 6:** Three different options for direct cervical injection: a 2-sided option (A) and the 4-quadrant options (B and C). Courtesy of Abu-Rustum NR, Levine DA, Barakat RR, eds. Atlas of Procedures in Gynecologic Oncology, 3rd ed. London: Informa Healthcare; 2013. ©2013, Memorial Sloan-Kettering Cancer Center.



**Figure 7:** Sentinel Lymph Node mapping procedures in endometrial cancer. Boruta D.M, Chapter 12, Translational Advances in Gynecologic Cancer

ICG injection is strongly accompanied with patient's body mass index. In almost 20 min. complete lymphatic spread is being depicted.

Sentinel node consists the first lymph node infiltration concerning the lymphatic spread. Staging of the lesion is strongly accompanied with number and lymphatic penetration depth. [13]

Positive lymphatic spread of SLN consists with appearance of macro metastasis (tumor spread > 2mm), micro metastasis (tumor spread 0,2-2mm) and isolated tumor cells (tumor spread < 0,2mm). [14]

Classical surgical therapeutic mapping in cases of endometrial cancer consists total hysterectomy, bilateral salpingoopherectomy and complete pelvic lymphadenectomy due to staging of the lesion. [15]

Less radical mapping reflects in low risk cases (FIGO IA, grade 1-2).

Decoding current bibliography, lymph vascular dissection seems to be controversial. [16]

In cases of complete and assiduous bilateral lymphadenectomy, many potential operative and post-operative surgical complications can be performed. [17]

Lymphedema local or diffuse accompanied with abdominal pain, skin breakdown and severe increased patient's quality of life consist examples of postoperative complications.

Extended surgical intervention, nerve injury and potential blood loss in cases of complete lymphadenectomy, accelerate the entrance of SLN evaluation.

Focusing on SLN mapping as ultimate recurrence factor, depiction of lymph vascular infiltration, leads to postoperative strategy, such as adjuvant therapy.

Although in most of cases preferred SLN technique consists  $^{99m}$  Tc and preoperative lymphoscintigraphy, SLN detection with ICG reflects new diagnostic pathways. [18]

Many conducted studies suggest SLN mapping with ICG incidence of overall detection from 84% and 100% and more specific increased bilateral detection rate from 71% and 84%, without doubt higher than 58% and 75% of the classical technique ( $^{99m}$  Tc and blue dye). [19]

SLN mapping with ICG allows more increased drainage of the contrast substance and depicts visualization of the whole pelvic lymphatic route in real time.

IGC technique consists an easily medical intervention, independent from patient's BMI without adequate surgeon's experience.

SLN detection procedure is based on the SLN protocol of Memorial Sloan-Kettering Center with H& E stain and CKAE1/AE3 immunostaining (Table I.) [20]

All lymph nodes are routinely sectioned and stained with H&E. Our institution's pathology protocol in assessing SLNs is based on work by Yared et al., who determined that reexamining SLNs at two additional levels with H&E and IHC could reliably detect low volume micro metastases. SLNs are initially examined by routine H&E staining, and subsequent ultra-staging is performed if the initial H&E assessment is negative. SLN ultra staging is performed by cutting two adjacent 5- $\mu$ m sections at each of two levels, 50- $\mu$ m apart, from each paraffin block lacking metastatic carcinoma. At each level, one slide is stained with H&E and with IHC using the anti-cytokeratin AE1:AE3 (Ventana Medical Systems, Inc., Tucson, AZ) for a total of five slides per block.

**Table 1:** Memorial Sloan Kettering Cancer Centre SLN mapping. *Int. J. Gynecol Cancer* 2013 June 9;23(5:964-970)

Many conducted studies arise from current literature have adopted the Memorial Sloan Kettering Cancer Centre SLN mapping.

According to these studies, detection rate of SLN was calculated. Detection rate is equal with the ratio of number of patients with SLN positive to the number of patients who underwent SLN mapping.

Additionally, positive and negative prognostic value can be calculated.

Most significant prognostic factors concerning SLN consist sensitivity and specificity of the method. [21]

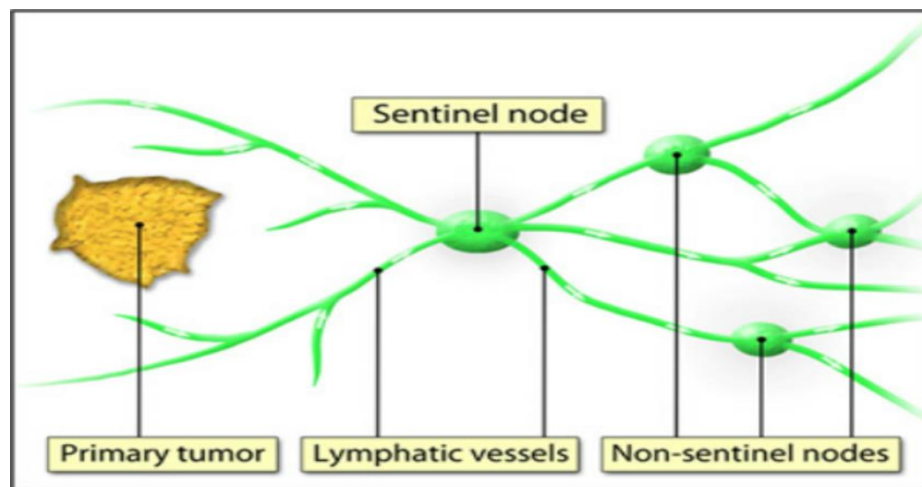
Many recent studies express higher sensitivity rather than specificity, concerning SLN mapping due to false negative cases.

On the contrary, in well-organized medical centers SLN mapping can lead to decrease of false negative patient numbers as well depiction of aortic metastatic lesions. [21]

With the assiduous studies of Abu-Rustum et al., a low curve of false negative patients was reflected.

According to recent bibliography, there are cases with SLN mapping failure.

Besides lack of medical expertise, lymphatic obstruction due to tumor infiltration, obesity and only use of contrast medium represent failure factors concerning SLN mapping. [22] (Figure VI.)

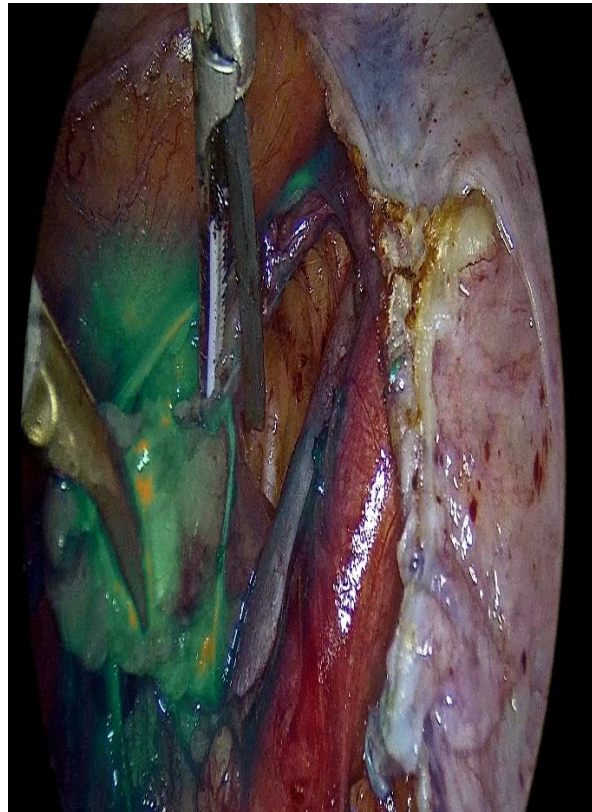

**Figure 8:** The sentinel lymph node (SLN) theory. The SLN is the first draining lymph node(s) from the tumor. Multispectral real-time fluorescence imaging for intraoperative detection of the SLN in gynecologic oncology. Crane MA, Themelis G, Buddihgh T, et al. *J Vis Exp.* 2010 Oct 20;(44):2225.

Many conducted studies are focusing on morbidity minimization due to SLN mapping.

In advanced stages of endometrial cancer, negative histopathologic evaluation of SLN can lead to lack of paraortic complete bilateral lymphadenectomy, down staging of the lesion and increase of overall survival, free disease survival and patient's quality of life. [23] (Figure VII.)

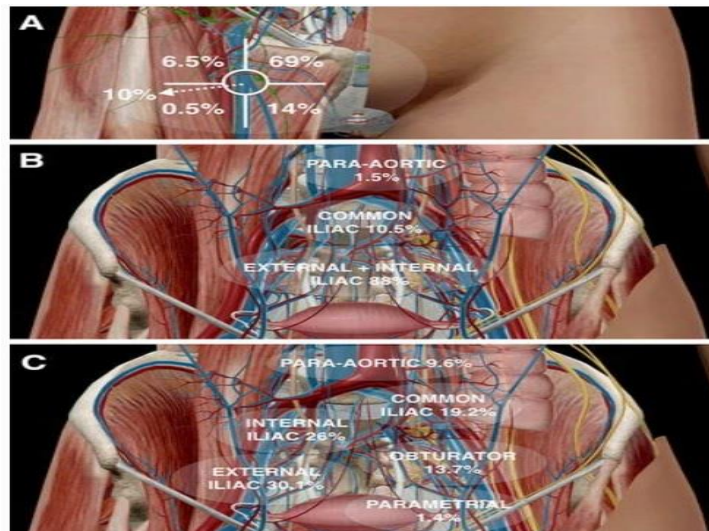




**Figure 9:** Laparoscopic right sentinel node dissection. Laparoscopic sentinel node mapping complicating endometrial cancer. Report of three cases and systematic review of the literature. Sofoudis C, Syrios K, Oikonomidis M, Betas P, Ziiris K. *Obstet Gynecol Int J* 2022;13(2):135-138

According to recent literature, many conducted studies suggest SLN mapping as alternative therapeutic strategy towards systematic pelvic and para-aortic lymph node dissection in cases with low grade endometrial cancer and second thinking for cases with high grade endometrial cancer. (Figure VIII.)

Many well organized surgical centers take advantage of increased medical equipment and manage to determine precise therapeutic alternatives towards premenopausal patients with endometrial cancer focusing on potential fertility preservation.



**Figure 10:** Anatomical sentinel lymph-node (SLN) distribution in gynecological malignancies. In vulvar cancer SLNs are limited to the groin and are predominantly found in the superior, central, and medial inferior inguinal Daseler’s zones (a). By contrast, in cervical cancer. (b) SLNs are mainly located along the iliac vessels whereas in endometrial cancer (c) also para-aortic drainage is frequently observed. Collarino A, Vidal-Sicart S, Perotti G, et al. *The sentinel node approach in gynecological malignancies. Clin Transl Imaging* (2016) 4:411–442

After the establishment of SLN mapping especially in cases of low risk endometrial cancer, critical question of all recent conducted studies remains what will be the crucial next step.

Focusing on histologic type in cases of endometrial cancer such as clear cell or serous endometrial cancer and staging of the lesion such as cases with grade three type, many organized centers across Europe or in the U.S. working towards a SLN protocol absolutely acceptable in order to establish more accurate and precise therapeutic strategy. [21]

Resulting in many conducted studies and algorithm proposals, surgical randomized trials with SLN mapping have been performed.

STATEC (Selective Targeting of Adjuvant Therapy in Endometrial Cancer) represents a randomized phase 3 study, which includes two independent groups. [24]

Study group depicting patients underwent total hysterectomy with pelvic and para-aortic node dissection with optional SLN mapping comparing with control group of patients underwent total hysterectomy without

pelvic and para-aortic dissection in cases of extended stages of endometrial cancer. [21]

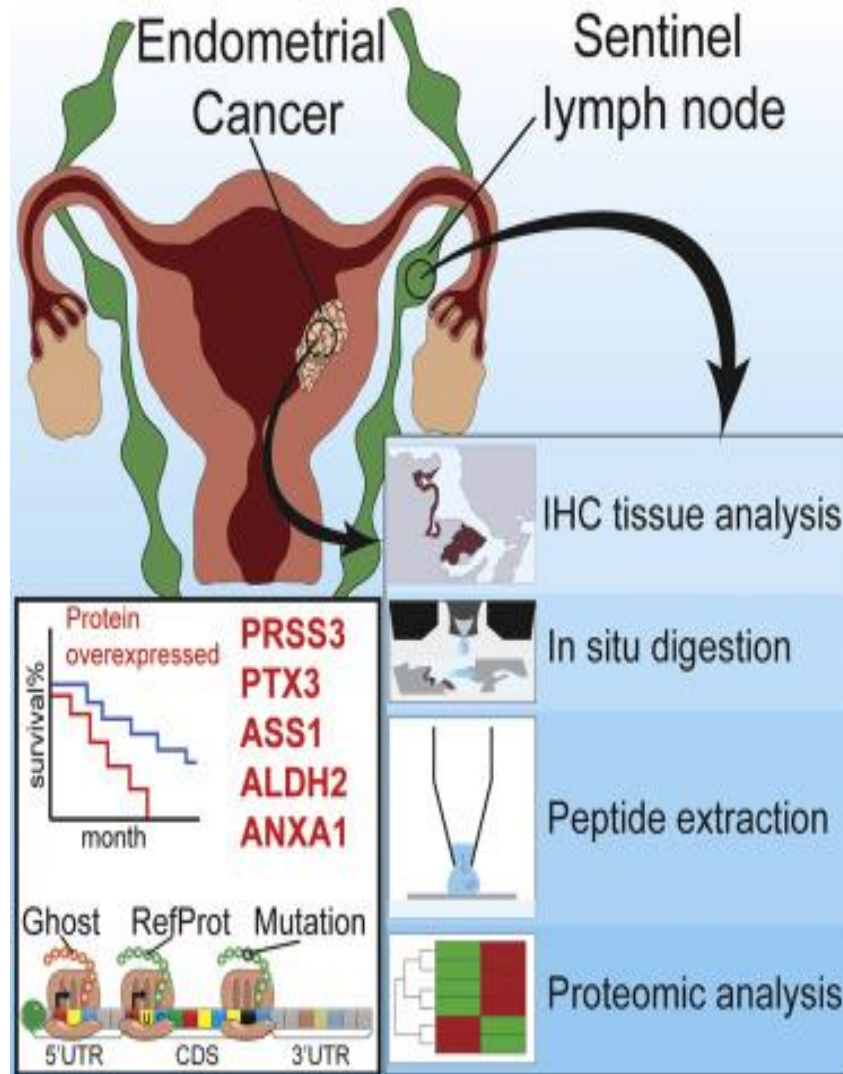
Focusing on the increased step of medical technology, molecular analysis of SLN mapping could provide promising information regarding early diagnosis of endometrial cancer cases. [21]

Aboulouard et al. suggested in depth molecular analysis of proteomics variations in SLN proteins, comparing with parallel analysis inside proteins of endometrial tumors. [25]

These protein variations depict potential markers with direct affection of overall survival.

Five major proteins for EC and SLN (PRSS3, PTX3, ASS1, ALDH2, and ANXA1) were identified in large-scale proteomics and validated by immunohistochemistry.

Study of Aboulouard et al. consists protein correlation of SLN mapping and endometrial cancer, optimal tool concerning early or advanced stages of endometrial cancer. (Figure IX.)



**Figure 11:** Over expression of SLN mapping proteins. Aboulouard S, Wisztorzski M, Duhamel M, et al. In depth proteomics of sentinel lymph nodes from individuals with endometrial cancer. Cell Rep Med. 2021 Jun 15;2(6):100318.

This conducted study reflects promising pathways in order to establish optimal therapeutic strategy in cases of endometrial cancer affecting especially premenopausal patients direct correlated with fertility preservation.

**Disclosure of interest**

Author declares any financial interest with respect to this manuscript.

## Conclusion

Endometrial cancer represents the 2<sup>nd</sup> most often gynecologic malignancy after cervix carcinoma among female population.

SLN mapping depicts first lymphatic drainage throughout lymphatic channels.

Increased sensitivity and decreased false negative rate lead to promising pathways concerning less surgical interventions and less intraoperative and postoperative potential complications.

## References

- Amant F, Moerman P, Neven P, Timmerman D, Van Limbergen E, Vergote I. Endometrial cancer. *Lancet*. 2005 Aug 6-12;366(9484):491-505.
- Torres ML, Weaver AL, Kumar S, Uccella S, Famuyide AO, Cliby WA, et al. Risk factors for developing endometrial cancer after benign endometrial sampling. *Obstet Gynecol*. 2012 Nov;120(5):998-1004.
- Ludwig H. Prognostic factors in endometrial cancer. *Int J Gynaecol Obstet*. 1995 Jul;49 Suppl: S1-7.
- Gompel A. Progesterone and endometrial cancer. *Best Pract Res Clin Obstet Gynaecol*. 2020 Nov;69:95-107.
- Bodurtha Smith AJ, Fader AN, Tanner EJ. Sentinel lymph node assessment in endometrial cancer: a systematic review and meta-analysis. *Am J Obstet Gynecol*. 2017 May;216(5):459-476.e10.
- Reinhart MB, Huntington CR, Blair LJ, Heniford BT, Augenstein VA. Indocyanine green: Historical context, current applications and future considerations. *Surg Innov*. 2016 Apr;23(2):166-175.
- Holloway RW, Abu-Rustum NR, Backes FJ, Boggess JF, Gotlieb WH, Jeffrey Lowery W, Rossi EC, Tanner EJ, Wolsky RJ. Sentinel lymph node mapping and staging in endometrial cancer: A society of Gynecologic Oncology literature review with consensus recommendations. *Gynecol Oncol*. 2017 Aug;146(2):405-415.
- Han KH, Kim HS, Lee M, Chung HH, Song YS. Prognostic factors for tumor recurrence in endometrioid endometrial cancer stages IA and IB. *Medicine (Baltimore)*. 2017 May;96(21):e6976.
- Casadio P, La Rosa M, Alletto A, Magnarelli G, Arena A, Fontana E, Fabbri M, Giovannico K, Virgilio A, Raimondo D, Guasina F, Paradisi R, Seracchioli R. Fertility sparing treatment of endometrial cancer with and without initial infiltration of myometrium: A single center experience. *Cancers (Basel)*. 2020 Nov 29;12(12):3571.
- How J, Gotlieb WH, Press JZ, Abitbol J, Pelmus M, Ferenczy A, et al. Comparing Indocyanine green, technetium and blue dye for sentinel lymph node mapping in endometrial cancer. *Gynecol Oncol*. 2015;137:436
- Persson J, Salehi S, Bollino M, Lönnerfors C, Falconer H, Geppert B. Pelvic sentinel lymph node detection in high risk endometrial cancer (SHREC trail)- the final step towards a paradigm shift in surgical staging. *Eur J Cancer*. 2019 Jul;116:77-85.
- How J, Lau S, Press J, Ferenczy A, Pelmus M, Stern J, et al. Accuracy of sentinel lymph node detection following intra-operative cervical injection for endometrial cancer. A prospective study. *Gynecol Oncol* 2012 ;127:332
- Killock D. Gynecological cancer. SLN staging for endometrial cancer. *Nat Rev Clin Oncol*. 2017 Apr;14(4):200.
- Bogani G, Mariani A, Paolini B, Ditto A, Raspagliesi F. Low volume disease in endometrial cancer. The role of micrometastasis and isolated tumor cells. *Gynecol Oncol*. 2019 Jun;153(3):670-675.
- Kovacevic N. Surgical treatment and fertility preservation in endometrial cancer. *Radiol Oncol*. 2021 Feb 11;55(2):144-149.
- Touhami O, Trinh XB, Gregoire J, Sebastianelli A, Renaud MC, Grondin K, et al. Predictors of non-sentinel lymph node metastasis in patients with sentinel lymph node metastasis in endometrial cancer =. *Gynecol Oncol*. 2015;138:41
- Giannini A, Di Donato V, Schiavi MC, May J, Panici PB, Congiu MA. Predictors of postoperative overall and severe complications after surgical treatment for endometrial cancer: The role of fragility index. *Int J Gynaecol Obstet*. 2020 Feb;148(2):174-180.
- Raimond E, Ballester M, Hundry D, Bendifallah S, Darai E, Graesslin O, et al. Impact of sentinel lymph node biopsy on the therapeutic management of early-stage endometrial cancer: Results of retrospective multicenter study. *Gynecol Oncol* 2011;123:522
- Maramai M, Achillarre MT, Aloisi A, Betella I, Bogliolo S, Garbi A, Maruccio M, Quatralo C, Aletti GD, Mariani A, Colombo N, Maggioni A, Multinu F, Zanagnolo V. Cervical re-injection of indocyanine green to improve sentinel lymph node detection in endometrial cancer. *Gynecol Oncol*. 2021 Jul;162(1):38-42.
- Holloway R, Abu Rustum NR, Backes F, et al. Sentinel lymph node mapping and staging in endometrial cancer: A society of gynecologic oncology literature review with consensus recommendations. *Gynecol Oncol* 2017;146(2):405-415
- van Hanegem N, Prins MM, Bongers MY, Opmeer BC, Sahota DS, Mol BW, Timmermans A. The accuracy of endometrial sampling in women with postmenopausal bleeding: A systematic review and meta-analysis. *Eur J Obstet Gynecol Reprod Biol*. 2016 Feb;197:147-155.
- Vatansever D, Giray B, Kumcular T, Ekemen S, Arvas M, Taskiran C. Failure of sentinel lymph node mapping in patient with endometrial cancer in chronic lymphocytic leukemia: A case report. *J Obstet Gynaecol Res*. 2019 Dec;45(12):2470-2473.
- Raffone A, Raimondo D, Travaglino A, Rovero G, Maletta M, Raimondo I, Petrillo M, Capobianco G, Casadio P, Seracchioli R, Mollo A. Sentinel lymph node biopsy in surgical staging for high risk groups of endometrial carcinoma patients. *Int J Environ Res Public Health*. 2022 Mar 21;19(6):3716.
- Mountzios G, Pectasides D, Bournakis E, Pectasides E, Bozas G, Dimopoulos MA, Papadimitriou CA. Developments in the systemic treatment of endometrial cancer. *Crit Rev Oncol Hematol*. 2011 Sep;79(3):278-292.
- Aboulouard S, Wisztorski M, Duhamel M, et al. In depth proteomics of sentinel lymph nodes from individuals with endometrial cancer. *Cell Rep Med*. 2021 Jun 15;2(6):100318.



This work is licensed under Creative Commons Attribution 4.0 License

To Submit Your Article Click Here:

**Submit Manuscript**

DOI: [10.31579/2768-2757/056](https://doi.org/10.31579/2768-2757/056)

**Ready to submit your research? Choose Auctores and benefit from:**

- fast, convenient online submission
- rigorous peer review by experienced research in your field
- rapid publication on acceptance
- authors retain copyrights
- unique DOI for all articles
- immediate, unrestricted online access

At Auctores, research is always in progress.

Learn more <https://www.auctoresonline.org/journals/journal-of-clinical-surgery-and-research>