

Counts of Damage Assessed following Head and Neck Cellulitis of Oral Origin

Nseme Etouckey Eric ^{1*}, Nokam Abena Marie Elvire ^{2*}, Tsayon Tiogoung Arnold ³, Ngaba Mambo Olive Nicole ⁴ and Bengondo Messanga Charles ²

¹Department of Morphological Sciences and Anatomopathology. Faculty of Medicine and Biomedical Sciences. University of Yaoundé I.

²Department of Oral, Maxillofacial and Periodontal Surgery. Faculty of Medicine and Biomedical Sciences. University of Yaoundé I.

³Faculty of Medicine and Biomedical Sciences. University of Yaoundé I.

⁴Department of Ophthalmology, ENT and Stomatology. Faculty of Medicine and Biomedical Sciences. University of Yaoundé I.

*Corresponding Authors: Nseme Etouckey Eric, Head of Department of Forensic Medicine. Tel 237 657110007. Yaoundé I.

NOKAM TAGUEMNE spouse ABENA Marie Elvire*, Head of Department of Odontostomatology Yaounde Center Hospital. Tel: 237 699975202.

Received date: April 18, 2022; Accepted date: June 13, 2022; Published date: June 28, 2022

Citation: Eric N E, Nokam A M Elvire, Arnold T T, Ngaba M O Nicole and Charles B M. (2022). Counts of damage assessed following head and neck cellulitis of oral origin. *J Dentistry and Oral Maxillofacial Surgery*, 5(3); DOI: [10.31579/2643-6612/033](https://doi.org/10.31579/2643-6612/033)

Copyright: © 2022, Nseme Etouckey Eric and Nokam Abena Marie Elvire. This is an open access article distributed under the Creative Commons Attribution License, which permits unrestricted use, distribution, and reproduction in any medium, provided the original work is properly cited.

Abstract

Introduction: Cellulite is an inflammatory process of bacterial origin of cellulo-adipose tissue. Its evolution and management can be marked by complications that can induce sequelae to patients. **The purpose** of the study was to determine the counts of harm assessed following surgical management of head and neck cellulitis of oral origin in three hospitals in Yaoundé.

Methodology: A descriptive and retrospective study was conducted in three hospitals in the city of Yaounde during 2021 for 7 months. Included in our research were patients surgically treated for head and neck cellulitis from January 2010 to December 2018. The data collection was done with a pre-designed sheet and the analysis of the results obtained using the EPI info 7.2.2.6 software.

Results: Out of 352 patients collected, male accounted for 63% of cases with a sex ratio of 1.69. The average age was 32.52 ± 11.4 years with extremes ranging from 1 to 73 years. About 46.88% worked in the informal sector. The main functional sequelae were edentulism (68.75%), and the average permanent functional deficit (PFD) was $1.61\% \pm 1.15$ with extremes between 0 and 7%. Permanent aesthetic damage (PEP) was mostly very mild, rated at 1/7 in 86.65% of cases. The suffering endured (SE) was mainly very mild, at 1/7 in 91.19% of cases.

Conclusion: The counts of harm assessed following odontogenic head and neck cellulitis were aesthetic harm, suffering endured and permanent functional deficit.

Keywords: head and neck cellulite; heads of harm; sequelae; evaluation; cellulo-fatty tissues

Introduction

Cellulite corresponds to an inflammatory condition of infectious origin of cellulo-fatty tissues. Its evolution can be marked by a gangrenous stage with very extensive losses of substances, local, loco-regional and general complications that can involve the patient's vital prognosis [1]. Treatment may require surgical management that is not without risk and can still be followed by sequelae affecting the health of patients in the short or even long term [2–4]. In order to compensate for these temporary and/or permanent sequelae, compensation may be granted to patients after a forensic examination [5,6]. The purpose of this article is to determine the

counts of harm assessed following the surgical management of cervicofacial cellulitis of oral origin.

Methodology

This was a descriptive and retrospective study that was conducted in the odontostomatology and ENT departments of the Yaounde Hospital and University Center, the Biyem-Assi District Hospital and the Yaoundé Central Hospital, from December 2020 to June 2021, a duration of 07 months. Included in our research were all records of living patients who had been surgically managed for oral cervicofacial cellulitis, from January 1, 2010 to December 31, 2018, a period of 08 years. The

assessment of aesthetic damage and suffering endured was done on a scale of 1 to 7, these scores corresponding respectively in ascending order to "very light, light, moderate, medium, important, quite important and very important". The permanent functional deficit was assessed using the indicative scale for the evaluation of disability rates in ordinary law of the Medical Competition published in 2001. The data collection was done using a pre-designed sheet for this purpose and taking into account the global ethical rules relating to the respect of confidentiality and the protection of patient-specific information. The data were entered and analyzed using epi info 7.2.2.6 software.

Results

Socio-demographic characteristics

We collected 352 cases of cervicofacial cellulite of oral origin. The male sex accounted for 63% or 221 cases, with a sex ratio of 1.69. The age group from 20 to 40 years accounted for 60.23% or 212 cases. The average age was 32.52 ± 11.4 years with extremes ranging from 1 and 73 years. Patients worked mainly in the informal sector in 46.88% or 165 cases as shown in Table 1.

Variables		Numbers (N=352)	Fréquence (%)
Sex	Man	221	63
	Wife	131	37
	Total	325	100
Age range	[20-40[212	60.23
	[40-60[65	18.47
	[0-20[48	13.64
	[60-80[27	7.66
Professions	Informal sector	165	46.88
	Student/Student	102	28.98
	Unemployed	50	14.20
	Formal sector	35	9.94

Table 1: Socio-demographic characteristics

Functional sequelae

Edentulism was present in most patients with 68.75% or 242 cases, followed by hypoesthesia with 17.05% or 60 patients, as shown in Table 2.

Functional sequelae	Numbers(N=352)	Fréquence (%)
Edentation	242	68.75
Neuralgia	3	0.85
Spasm	24	6.82
Hypoesthesia	60	17.05
Tearing	6	1.70
Sinusitis	7	1.99

Table 2: Functional sequelae

Harm assessment

Permanent Aesthetic Damage (PEP)

Our research showed that 68.47% or 241 cases had very mild aesthetic damage (Figure 2), or a PEP of 1/7. Figure 1 shows the distribution of our sample based on the PEP assessment.

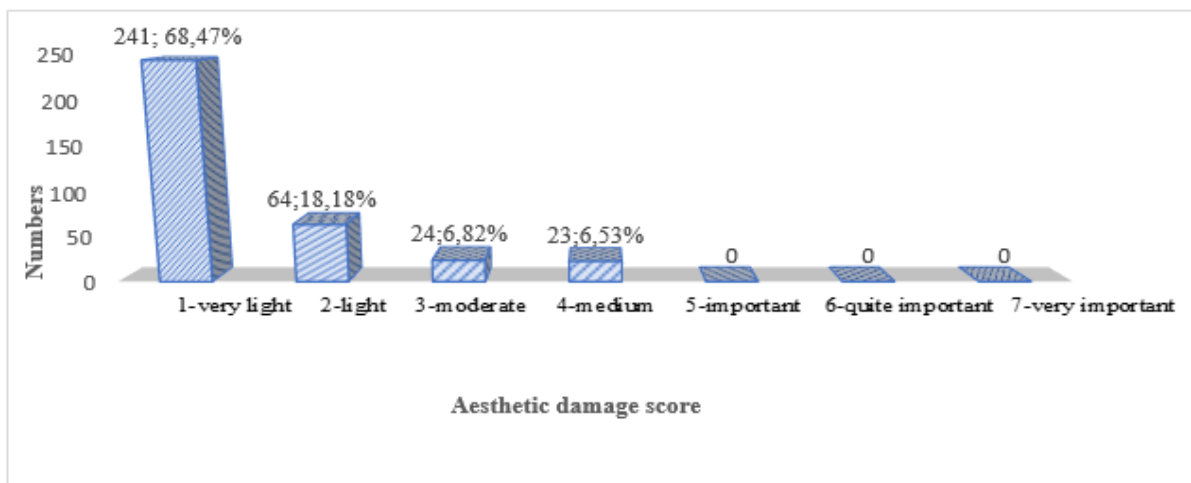


Figure 1: PEP Distribution

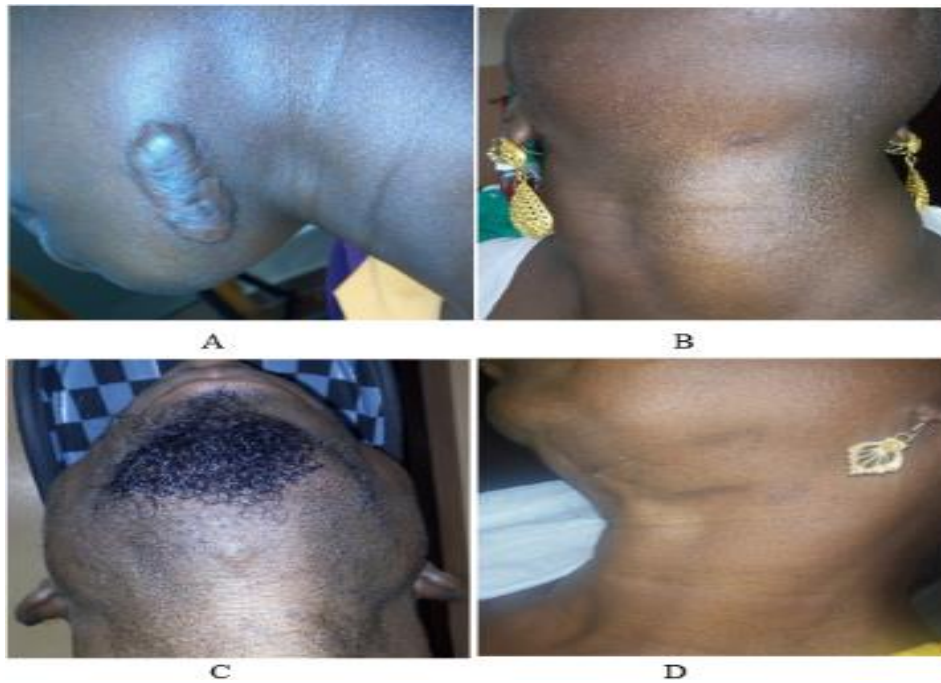

Figure 2: A) Keloid scar (B and C) hypertrophic scarring D) Depressed scar

Permanent Functional Deficit (PFD)

The average PFE was 1.61% ±1.15 with a median of 1.5% and extremes ranging from 1 to 7%. Figure 3 shows the assessment of PFE in our patients.

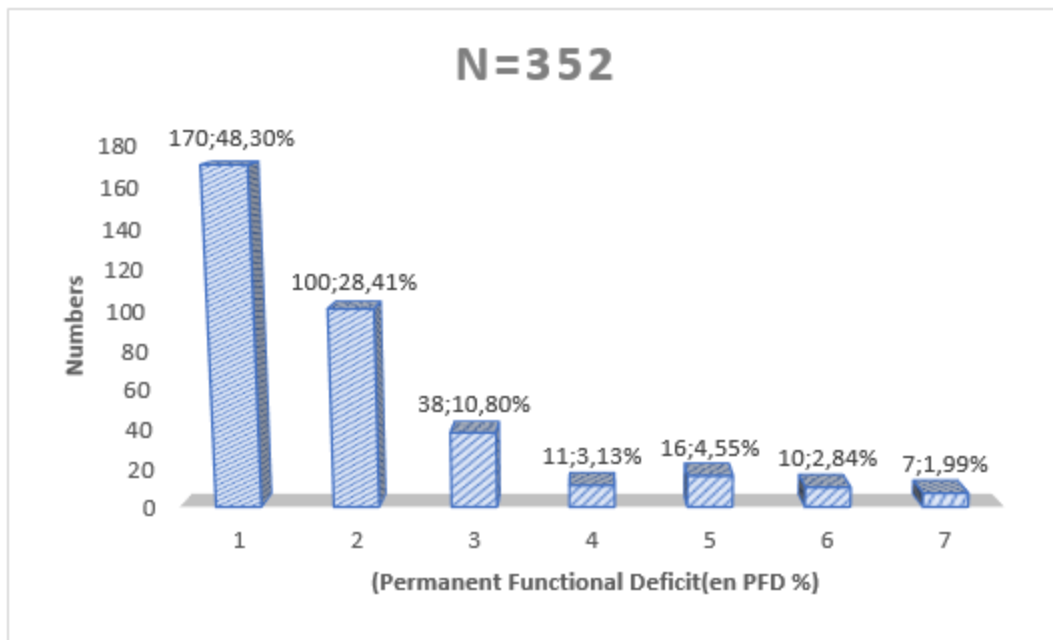


Figure 3: Distribution by Permanent Functional Deficit

Suffering endured (SE)

The majority of patients, 265 (75.28%) had suffering endured as very mild, a rating of 1/7, as shown in Figure 4.

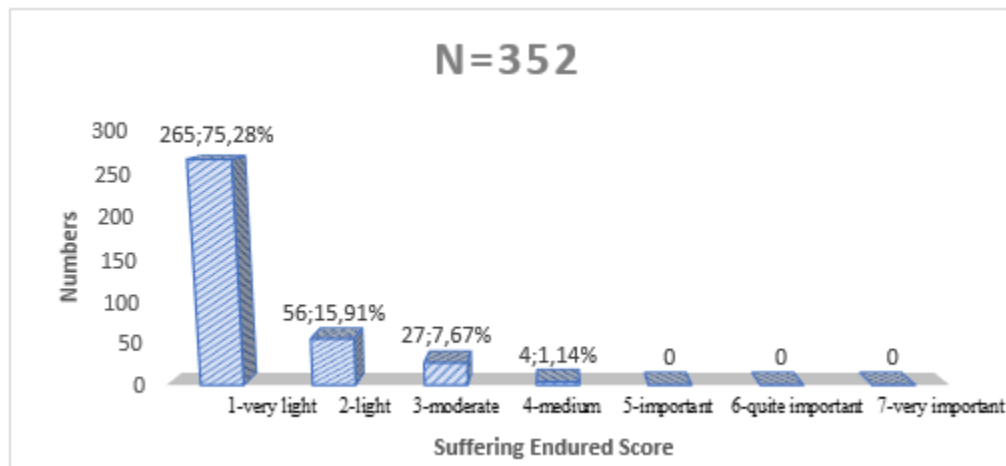


Figure 4: Distribution according to the suffering endured.

Discussion

Sex

The male sex dominated in 63% of cases, with a sex ratio of 1.69. Atanga et al., in 2020 in Yaounde, found a sex ratio of 1.4. This male superiority is generally reported in the literature [7] and can be explained by the fact that men have poor oral hygiene compared to women because they are less inclined to body care than women [8].

Age

Head and neck cellulite affects all age groups, but it is of particular interest to young subjects. In our study, the most represented age group was 20 to 40 years. This result is similar to that reported by Njifou et al. in 2014 in Douala who found an age range of 21 to 40 years [9]. This finding can be explained by the accident of evolution of the wisdom teeth that erupt during this age group [10,11].

Profession

The majority of patients worked in the informal sector (46.88%). Our result is similar to that of Bréhima et al. in 2014 in Mali which reported 31.48% of cases [12] and that of Zegbeh et al. in 2020 in Côte d'Ivoire which observed that 31.28% of cases were craftsmen [13]. This result could be explained in the context of the current economic crisis by the proliferation of small trades and the development of self-entrepreneurship in our country.

DFP

The average PFE was $1.61\% \pm 1.15$. This result is similar to that of Tran Ba Huy et al. in 2011 in France which found an average of $1.7\% \pm 2.4$. The main sequelae allowing the evaluation of PFE was edentulism, found in 68.75% of cases in our series. The scale used for the evaluation of the DFP was the indicative scale of evaluation of disability rates in ordinary law which is nevertheless similar with that of the Inter-African Conference of Insurance Markets (CIMA). Our result can be explained by the fact that the teeth most involved in the occurrence of this type of cellulitis were the molars.

Energy

In our study PEP in 68.47% of cases, or 241 patients, was rated as very mild. The main sequelae found were retractile and keloid scars. Ramilison et al. in 2017 in Malagasy, also found these same scars [14]. This resemblance could be explained by the similarity of technique used; indeed, the two teams made an incision followed by drainage to accelerate

the resorption of the purulent collection. However, this practice could be complicated by scars by poor evolution and / or malformation, which induce unsightly sequelae and sometimes require cosmetic correction surgery [15].

Suffering endured

The majority of patients, 75.28% (265 cases) had suffering endured as very mild, a rating of 1/7. The sequelae used for his assessment was pain, which was considered less through the use of anti-inflammatories and analgesics throughout management.

Conclusion

Moreover, head and neck cellulitis of oral origin was of particular interest to young men working in the informal sector. The main counts of harm assessed after surgical management of this cellulite were the suffering endured and the aesthetic damage which were qualified as very slight and the permanent functional deficit which was posed on the basis of edentulism.

Acknowledgments

We thank all the staff of the Odontostomatology and ENT departments of hcy, CHUY, HD Byem-Assi hospitals, for their collaboration.

Conflict of Interest

The authors declare no conflict of interest.

References

1. Togo S, Ouattara M, Saye J, Sangaré I, Touré M, Maiga I, et al. (2017). Necrotizing cervico-facial cellulitis of dental origin in a developing country. *Rev Evil Breathe*; 34(7):742-748.
2. Ramilison H, Rakotoarison R, Fare A, Razafindrabe J, Rakotoarison R, Rakoto F, et al (2017). Complications and sequelae of cervico-facial cellulitis seen in antsiranana, madagascar. 13:12.
3. Atanga L, Mballa N O, Bohimbo E J, Ottou M, Njock R. (2020). Diagnosis, Treatment and Prognosis of Cervico-Facial Cellulitis in Yaoundé. *Health Sci Dis*. 21(6).
4. Aldosa J, Gangloff P, Gallet P. (2016). Sequelae of severe cervico-facial cellulitis of dental origin: retrospective and prospective study. 64th SFCO.2 Congress.
5. Michaud J, Jourdain P, Chodkeiwicz J, Papelard A, Fournier C. (2001). Indicative scale for assessing rates of incapacity under common law.

6. Fais P, Viero A, Guido V, Giordano R, Raniero D, Kusstatscher S, et al. (2018). Necrotizing fasciitis: case series and review of the literature on clinical and medico-legal diagnostic challenges. *Int J Leg Med.*10.
7. Ramparany AC. (2017). Epidemiological, clinical and therapeutic aspects of severe odontogenic cervico-facial cellulitis [Thesis]. University of Antananarivo.
8. Ménard C, Grizeau-Clemens D, Wemaere J. (2016). *Adult Oral Health.* (35):10.
9. Njifou N. A, Kouotou E, Essama L, Moby H, Mapoure Y, Motah M, et al. (2014). Cervicofacial cellulitis in Cameroonian hospitals. *Health Sci Dis* 15(1):1.
10. Peron J-M. (2004). Accidents of evolution of wisdom teeth. *EMC - Dent.*1(2):147-158.
11. Diallo A. (2014). Cervicofacial cellulitis of oral origin: epidemiological, clinical and therapeutic aspects at the Yalgado Ouedraogo University Hospital Center: about 127 cases. [Thesis]. University of Ouagadougou.
12. Bréhima T, Mamadou L, Boubacar B. (2014). Acute circumscribed perimaxillary cellulitis of dental origin in the department of stomatology and maxillofacial surgery of the CHUOS of Bamako [Thesis]. University of Technical and Technological Sciences of Bamako.
13. Zegbeh N. E, Digbeu O. K, Béréte P. I, Teti F. L, Goulé A, Crezoit G. (2020). Facial Cellulitis of Dental Origin: Experiments from the University of Bouaké; *Open J Stomatol.*10(05):97-105.
14. Ramilison H, Rakotoarison R, Fare A, Razafindrabe J, Rakotoarison R, Rakoto F, et al. (2017). Complications and sequelae of cervico-facial cellulitis seen in antsiranana, madagascar. 13:12.
15. Canizares F, Chavoin J-P, Soubirac L, Foucras L, Fossat S, Mojallal A, et al. (2006). Defective skin scars. *EMC - Tech Chir - Chir Plast Reconstr Esthét.* Jan. 1(1):1-10.



This work is licensed under Creative Commons Attribution 4.0 License

To Submit Your Article Click Here:

Submit Manuscript

DOI: [10.31579/2643-6612/033](https://doi.org/10.31579/2643-6612/033)

Ready to submit your research? Choose Auctores and benefit from:

- fast, convenient online submission
- rigorous peer review by experienced research in your field
- rapid publication on acceptance
- authors retain copyrights
- unique DOI for all articles
- immediate, unrestricted online access

At Auctores, research is always in progress.

Learn more at: <https://www.auctoresonline.org/journals/dentistry-and-oral-maxillofacial-surgery->