

Late Aortic Insufficiency After Ventricular Device Closure: A Case Report

Marisha Aryal ^{1*}, Rabindra Timala ²

^{1,2} Shahid Gangalal National Heart Centre, Bansbari, Kathmandu, Nepal.

^{1,2} Department of Cardiac Surgery.

***Corresponding Author:** Marisha Aryal, Shahid Gangalal National Heart Centre, Bansbari, Kathmandu, Nepal.

Received Date: April 09, 2022; **Accepted Date:** May 06, 2022; **Published Date:** May 13, 2022

Citation: Marisha Aryal, Rabindra Timala (2022). Late Aortic Insufficiency After Ventricular Device Closure: A Case Report. *J. Clinical Cardiology and Cardiovascular Interventions*, 5(6); DOI:10.31579/2641-0419/263

Copyright: © 2022 Marisha Aryal, This is an open-access article distributed under the terms of the Creative Commons Attribution License, which permits unrestricted use, distribution, and reproduction in any medium, provided the original author and source are credited.

Abstract:

Device closure of isolated ventricular septal defect is taking precedence over surgical closure in current era. However, device closure in perimembranous and subarterial VSD is complicated by procedural acute aortic regurgitation. In this report we found late aortic regurgitation after four years of device closure of ventricular septal defect. This incident needs one to reconsider the choice of device in patients with perimembranous or subarterial ventricular septal defect as the rim of the occluder device is near the aortic cusp. Early intervention after the development of significant aortic regurgitation is beneficial for the patient.

Key Words: ventricular septal defect; device closure; aortic insufficiency; aortic regurgitation; amplatzer device occlude; case report

Introduction

Ventricular septal defect is the commonest congenital anomaly requiring surgical intervention. As transcatheter interventions have been advanced, device closure is used for most isolated VSDs. Immediate post-procedural complications of device closure include aortic regurgitation, right bundle branch block, residual shunt and device emboli. [1,2] Late onset of aortic regurgitation has been mentioned in literature and this mandates finding patients who are at risk of developing it.[3] This case report is of a patient who developed late aortic regurgitation due to perforation of the right coronary cusp following VSD device closure. High index of suspicion for aortic valve injury is necessary for patients with device closure developing late aortic regurgitation. This also mandates analyzing and deferring patients who are at risk. [4]

Ethical Statement

Patient's guardian had been informed about the nature of study. Informed written consent has been obtained for the publication of the case. Approval of the Institutional review board has been obtained.

Case Summary

A twelve-year-old boy was referred to surgical outpatient clinic after noticing new aortic regurgitation (AR) of moderate severity in a follow-

up transthoracic echocardiogram after VSD device closure. Patient had undergone VSD device closure 4 years back with amplatzer duct occluder (10/8mm). There was no AR in the previous follow-up echocardiography. Suspecting the device to be the culprit for the new onset significant aortic regurgitation patient was admitted for surgical retrieval of the device with VSD patch closure and repair/replacement of aortic valve.

Pre-operative transthoracic echocardiogram showed VSD device in-situ with no residual leak with moderate aortic regurgitation with any impingement of the aortic cusps.

After standard anesthesia and lines placement, transesophageal echocardiography (TEE) was done. The findings were similar to the pre-operative echo. After establishing cardiopulmonary bypass and cardioplegic arrest, right atriotomy was done. Device was in-situ. (Figure 1) Oblique aortotomy was done. There was a 4x4 mm perforation in the right coronary cusp (RCC). (Figure 2)

VSD device was carefully extracted through right atrial approach. The ventricular septal defect was closed with PTFE patch. The perforation in the RCC was patched with pericardium. After weaning off bypass, there was no aortic regurgitation in TEE. Postoperative hospital stay was uneventful. Three months follow-up showed no aortic regurgitation in transthoracic echocardiography.

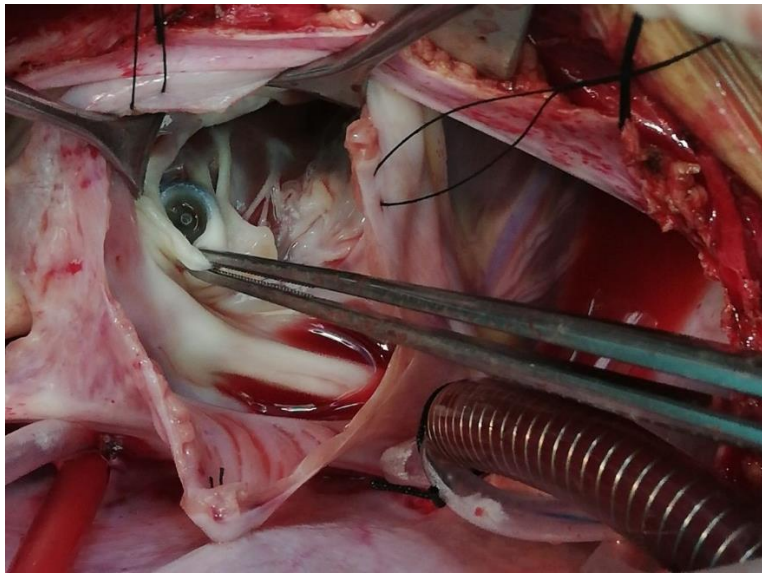


Figure 1: Intra-Operative Image with Device in-Situ

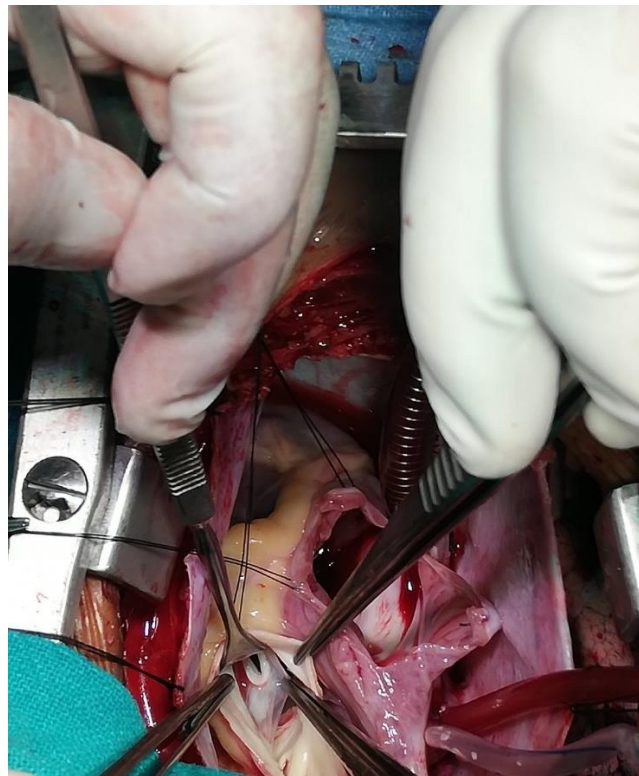

Figure 2: Perforation of Right Coronary Cusp

Discussion

Isolated congenital ventricular septal defect can be treated either surgically or by percutaneous transcatheter approach. As studies have

shown low mortality and morbidity with the percutaneous approach, device closure of VSDs has been gaining more attention. [4,5] With the availability of different devices, the range of closure had been expanded from muscular to perimembranous and subarterial VSDs. Among various complications associated with device closure, aortic regurgitation is

considered to be rare. [6] Though retrospective studies comment on procedural AR leading to abandonment of the procedure, data regarding late AR development is scarce. [1] In this study, the patient had developed aortic regurgitation of moderate severity 4 years after the device implantation with only mild AR in prior annual follow-up. This late development of AR due to perforation of right coronary cusp (RCC) is unusual. There are reports of involvement of RCC after device closure either diagnosed incidentally for management of hematuria or IE. [3,7] In

patients with perimembranous VSD, subaortic rim is short or deficient. This increases the risk of immediate aortic insufficiency after device placement. Late aortic regurgitation should prompt the physician to rule out cusp-related etiology to plan for early intervention.

Early management of aortic regurgitation should be done to prevent the detrimental effect of volume overload in left ventricle. This also decreases the possibility of replacement of aortic valve, when repair can be done at early stage [7].

Timely intervention on this child saved him from further damage to the aortic valve cusps, which might have resulted in aortic valve replacement otherwise.

Conclusion

Device closure of VSD has negated the complications related to cardiopulmonary bypass. However, the short distance between the VSD device in perimembranous position and right coronary cusp might increase the risk of aortic regurgitation due to cusp injury. A study involving the size of the perimembranous VSD, choice of device and its outcome in terms of aortic regurgitation would be beneficial for proper patient selection. Once the device is inserted, patient should be closely monitored and intervened if needed.

Authors' note

The patient's guardian and Institutional Review Committee have granted consent for publication of this case report.

Conflict of interest: none declared.

Funding: The authors received no financial support for the research, authorship, and/or publication of this article.

References

1. Liu J, Wang Z, Gao L, Tan H-L, Zheng Q, Zhang M-L. A Large Institutional Study on Outcomes and Complications after Transcatheter Closure of a Perimembranous-Type Ventricular Septal Defect in 890 Cases.
2. Holzer R, de Giovanni J, Walsh KP, Tometzki A, Goh T, Hakim F, et al. (2006). Transcatheter closure of perimembranous ventricular septal defects using the amplatzer membranous VSD occluder: Immediate and midterm results of an international registry. *Catheter Cardiovasc Interv.* Oct;68(4).
3. Negi S, Kumar A, Podder S, Mishra A. (2018) Percutaneous ventricular septal defect closure causing acute aortic regurgitation. *Egypt J Cardiothorac Anesth.* 12(1).
4. Hong Z-N, Chen Q, Huang L-Q, Cao H. A meta-analysis of periventricular device closure of perimembranous ventricular septal defect. *J Cardiothorac Surg.* 2019 Dec 27;14(1).
5. Adhikari CM, Shrestha M, Shah SC, Bogati A, Dhungel S, Acharya KP, et al. Device closure of ventricular septal defect: Initial experience in Nepal. *Asian J Med Sci.* 2019 Jun 21;10(4).
6. Knauth AL, Lock JE, Perry SB, McElhinney DB, Gauvreau K, Landzberg MJ, et al. Transcatheter Device Closure of Congenital and Postoperative Residual Ventricular Septal Defects. *Circulation.* 2004 Aug 3;110(5).
7. Tang C, Zhou K, Hua Y, Wang C. Very late-onset endocarditis complicated by non-significant aortic regurgitation after device closure of perimembranous ventricular septal defect. *Medicine (Baltimore).* 2020 May;99(19).



This work is licensed under Creative Commons Attribution 4.0 License

To Submit Your Article Click Here:

Submit Manuscript

DOI: [10.31579/2641-0419/263](https://doi.org/10.31579/2641-0419/263)

Ready to submit your research? Choose Auctores and benefit from:

- fast, convenient online submission
- rigorous peer review by experienced research in your field
- rapid publication on acceptance
- authors retain copyrights
- unique DOI for all articles
- immediate, unrestricted online access

At Auctores, research is always in progress.

Learn more <https://auctoresonline.org/journals/clinical-cardiology-and-cardiovascular-interventions->