

# Neurofibromatosis 1 Presence in Breast Tissue: Case Report

Oludamilola Olufosoye <sup>1</sup>, Samuel Lichtman-Mikol <sup>1\*</sup>, Biren A. Shah <sup>1</sup>

<sup>1</sup>The Sastry Foundation Advanced Imaging Laboratory, Wayne State School of Medicine, 4201 St Antoine, Detroit, MI 48201, USA.

**\*Corresponding Author:** Samuel Lichtman-Mikol, The Sastry Foundation Advanced Imaging Laboratory, Wayne State School of Medicine, 4201 St Antoine, Detroit, MI 48201, USA.

**Received date:** April 03, 2022; **Accepted date:** April 27, 2022; **Published date:** May 04, 2022

**Citation:** Oludamilola Olufosoye, Samuel L-Mikol, Biren A. Shah (2022). Neurofibromatosis 1 Presence in Breast Tissue: Case Report. *J. Women Health Care and Issues*. 5(3); DOI:10.31579/2642-9756/113

**Copyright:** © 2022 Samuel Lichtman-Mikol, This is an open access article distributed under the Creative Commons Attribution License, which permits unrestricted use, distribution, and reproduction in any medium, provided the original work is properly cited.

## Abstract

Neurofibromatosis 1, also known as Von Recklinghausen disease, is the most common of the three neurofibromatoses. It is a multi-organ disease that is characterized by the development of cutaneous neurofibromas, plexiform neurofibromas, optic nerve gliomas, astrocytomas, Lisch nodules, and pheochromocytomas. We present a case of 66-year-old woman with NF-1. The disease presents with multiple cutaneous neurofibromas in both breasts. People living with NF-1 disease might have a different course of malignancy or other associated symptoms than the average individual without NF-1. It is essential that patients presenting with NF-1 symptoms are followed longitudinally to ensure that the progression of their symptoms are appropriately treated.

**Keywords:** neurofibromatosis 1; neurofibromin; breast imaging; mammogram

## Introduction

Neurofibromatosis type 1 is the most common of the neurocutaneous syndromes (phakomatosis). Neurofibromatoses are nerve sheath tumors that include neurofibromatosis 1 (NF 1), neurofibromatosis 2 (NF 2), and schwannomatosis of which all are autosomal-dominant inherited genetic disorders [1]. Neurofibromatosis 1, also known as Von Recklinghausen disease, is the most common of the three neurofibromatoses. It is a multi-organ disease that is characterized by the development of cutaneous neurofibromas, plexiform neurofibromas, optic nerve gliomas, astrocytomas, Lisch nodules, and pheochromocytomas.

Neurofibromas are a major tumor associated with NF1. A neurofibroma is a benign nerve sheath tumor that consists of fibroblasts, mast cells, perineural like cells and Schwann cells. The NF1 gene is found on chromosome 17q11.2. [3] The NF1 gene produces neurofibromin which functions in the downregulation of the RAS, a proto-oncogene involved in cell growth and differentiation. [2] NF1 tumors can present with varying symptoms due to its expression in most tissues and different systems. [3] Patients presenting with this mutation are at an increased risk of cancer such as gliomas, malignant peripheral nerve sheath tumors, juvenile chronic myelomonocytic leukemia, rhabdomyosarcoma and pheochromocytoma. [1, 2] In addition, both NF1 and BRCA1 are found on chromosome 17q, which could indicate

a possible interaction, and women with NF1 have a 3.5-fold increase overall risk of developing breast cancer, and a 4.9-fold increased risk of developing breast cancer prior to age 50. [4] Patients with NF1, who present with any of the associated tumor manifestations, require a unique approach to patient care, as these findings may have a different clinical course as compared to sporadic occurring tumors. [2]

The purpose of this case study is to show a case of multiple cutaneous neurofibromas seen on mammography and how cutaneous neurofibromas can be distinguished from masses within the breast parenchyma.

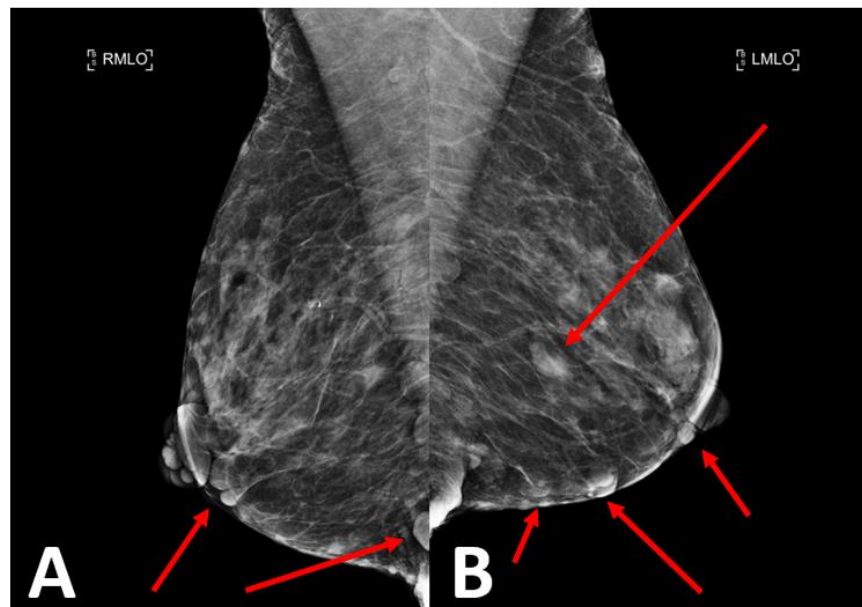
## Case Report:

### History:

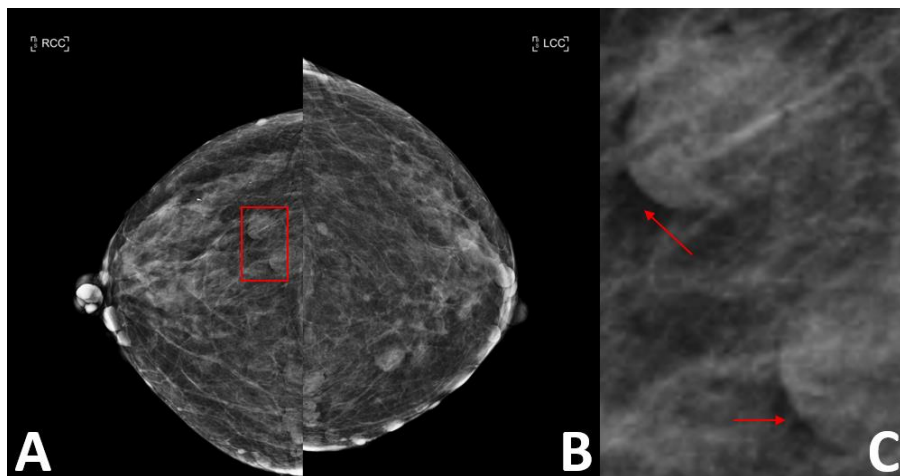
A 66-year-old woman presents to a breast imaging center for routine screening mammography. The patient has a known history of neurofibromatosis type 1, hypertension, and dyslipidemia.

### Imaging studies:

Mediolateral oblique and craniocaudal images of both breasts demonstrate multiple round and oval circumscribed cutaneous masses in both breasts of varying sizes.-(**Figure 1, 2**).



**Figure 1: Mediolateral oblique (MLO) view of the bilateral breasts.** A, right breast; B, left breast. There are multiple cutaneous masses visualized in both breasts (see red arrows) that represent neurofibromas.



**Figure 2: Craniocaudal view of the bilateral breasts.** A, right breast; B, left breast. There are multiple cutaneous masses visualized in both breasts bilaterally that represent neurofibromas. There are also 2 neurofibromas seen in the central left breast at posterior depth (red square), which is enlarged in panel C. Red arrows point to the radiolucent halos which are indicative of that these masses not within the breast parenchyma.

#### Diagnosis:

The multiple round and oval cutaneous masses in both breasts represented multiple neurofibromas in a patient with known history of NF1 rather than masses within the breast parenchyma.

#### Discussion:

NF-1 is one of the most common genetic disorders, it occurs in 90% of neurofibromatosis cases and has a prevalence of one in 3000 births [5]. The main clinical manifestations of NF-1 is café au lait which occurs within the first year of life and in most patients with the NF-1 mutation [6]. Lisch nodules, optic gliomas, neurological impairment, scoliosis, oral and maxillofacial abnormalities, malignant tumors of the nerve sheath, pheochromocytoma, and bone deformities being additional common clinical findings. [5,6]

Mutations to the gene occur during the embryonic period before neural crest differentiates. [3,5] Due to the large size of the NF1 gene, a high degree of sporadic mutations are observed along with an approximation of 50% familial NF1 mutation. The disorder displays a pattern of variable expressivity and a 100% penetrance. [3,4,7] By age 5, majority of NF1 patients start to exhibit clinical manifestations of the disorders while sporadic cases can remain undiagnosed through adult life. [4] The National Institute of Health created criteria for guiding the clinical diagnosis of the NF1, in which a patient presents with two or more of the following seven diagnostic standards:

1. Six or more café-au-lait macules over 5mm in diameter in prepubertal individuals and over 15mm in greatest diameter in post pubertal individuals

2. Freckling in the axillary or inguinal regions
3. Optic glioma
4. Two or more Lisch nodules (iris hamartomas)
5. Distinctive osseous lesion such as sphenoid dysplasia
6. Two or more neurofibromas of any type or one plexiform neurofibroma
7. Family history of the first-degree relative with neurofibromatosis<sup>8</sup>

Malignancy is a complication of NF1 most noted in the development of malignant peripheral nerve sheath tumors and optic gliomas. 2,3 NF1 and occurrence of breast cancer has been indicated in several studies. [4, 7, 9] The patient, presented with a past medical history of NF1, these masses pose a problem as they may mimic intramammary breast masses or obscure a superimposed breast lesion. One distinguishing feature of dermal masses is the presence of a radiolucency bordering the well circumscribed mass, termed a radiolucent halo (**Figure 2C**). This radiolucency indicates air trapping around the mass, suggesting a dermal location, rather than a mass within the breast tissue itself.

### Conclusion:

In cases of spontaneous NF1 mutations that present with neurofibromin tumors, it is crucial that physicians are aware of how the tumors might progress to prevent further complications, as they are at increased risk for developing cancers. Patients presenting with NF1 tumors should be monitored with systemic therapies and follow-up screening for development of new lesions and to ensure current tumors are not evolving. This can be achieved by annual screening mammography, with the radiologist paying close attention to detail to differentiate between cutaneous and intraparenchymal masses. Understanding the classic appearance of NF1 on mammography can help prevent unnecessary workup while also appropriately identifying suspicious findings requiring further evaluation.

### References:

1. Lu-Emerson C, Plotkin SR. The Neurofibromatoses. Part 1: NF1. *Reviews in Neurological Diseases*. 2009;6(2):47-53.
2. Sayah C, Benmahmoud M, Ait Yahia S, Soualili Z. Neurofibromatosis type 1 (NF1): Case report and review of literature. *Journal of Childhood & Developmental Disorders*. 2016;2(3).
3. Ly KI, Blakeley JO. The diagnosis and management of neurofibromatosis type 1. *Medical Clinics of North America*. 2019;103(6):1035-1054.
4. Sharif S, Moran A, Huson SM, et al. Women with neurofibromatosis 1 are at a moderately increased risk of developing breast cancer and should be considered for early screening. *Journal of Medical Genetics*. 2007;44(8):481-484.
5. Ghalayani P, Saberi Z, Sardari F. Neurofibromatosis type I (von Recklinghausen's disease): A family case report and literature review. *Dental Research Journal*. 2012;9(4):483-488.
6. Trovó-Marqui AB, Tajara EH. Neurofibromin: A general outlook. *Clinical Genetics*. 2006;70(1):1-13.
7. Suarez-Kelly LP, Yu L, Kline D, Schneider EB, Agnese DM, Carson WE. Increased breast cancer risk in women with neurofibromatosis type 1: A meta-analysis and systematic review of the literature. *Hereditary Cancer in Clinical Practice*. 2019;17(1).
8. Walsh M, Kresak J. Neurofibromatosis: A review of NF1, NF2, and schwannomatosis. *Journal of Pediatric Genetics*. 2016;05(02):098-104.
9. Wallace MD, Pfefferle AD, Shen L, et al. Comparative oncogenomics implicates the neurofibromin 1 gene (NF1) as a breast cancer driver. *Genetics*. 2012;192(2):385-396.



This work is licensed under Creative Commons Attribution 4.0 License

To Submit Your Article Click Here:

**Submit Manuscript**

DOI: [10.31579/2642-9756/113](https://doi.org/10.31579/2642-9756/113)

#### Ready to submit your research? Choose Auctores and benefit from:

- fast, convenient online submission
- rigorous peer review by experienced research in your field
- rapid publication on acceptance
- authors retain copyrights
- unique DOI for all articles
- immediate, unrestricted online access

At Auctores, research is always in progress.

Learn more <https://auctoresonline.org/journals/women-health-care-and-issues->