

# The Heart and Vessels Foreign Bodies. A 3-Year Review

Emmanuel Auchu Edafe <sup>1,2\*</sup>, Maclean Rumokere Akpa <sup>3</sup>

<sup>1</sup> Bayelsa Specialist Hospital, Yenagoa

<sup>2</sup> Niger Delta University Teaching Hospital, Okolobiri.

<sup>3</sup> University of Port Harcourt Teaching Hospital, Port Harcourt

\*Corresponding Author: Emmanuel Auchu Edafe, Bayelsa Specialist Hospital, Yenagoa.

Received Date: March 28, 2022; Accepted Date: April 11, 2022; Published Date: April 18, 2022

Citation: Emmanuel A. Edafe., Maclean R. Akpa (2022). The Heart and Vessels Foreign Bodies. A 3-Year Review. *J. Clinical Cardiology and Cardiovascular Interventions*, 5(5); DOI:10.31579/2641-0419/260

Copyright: © 2022 Emmanuel Auchu Edafe, This is an open-access article distributed under the terms of the Creative Commons Attribution License, which permits unrestricted use, distribution, and reproduction in any medium, provided the original author and source are credited.

## Abstract

### Introduction

Foreign bodies in the heart and vessels are rare. They are usually iatrogenic. They get to the heart through different ways. They may cause serious complication including embolism and arrhythmias. They can be diagnosed with X-ray, computerized tomography, and echocardiography. They are removed by endovascular percutaneous, surgical or conservative. In this four-year review, we analyzed and identified the treatment of foreign body referred to the Bayelsa Specialist Hospital.

### Methods

We searched the cardiac catheterization records of the hospitals and identified 11 foreign bodies referred for the period of 1st January 2018 and 30th April 2021. The site, etiology, clinical presentation, symptoms, complications and management modality, and outcome were noted.

### Results

The patients' mean age was 57. There were more women than men 8 versus 4 [P < 0.002]. The most common foreign bodies were parts of inferior vena cava filters and devices. Foreign bodies in the heart were symptomatic in 76% of patients. Right atrial chamber, inferior and superior vena-cava were occupied more often. A total of 78% presented within the first 24 hours. A majority of foreign bodies reached the heart by migration. There was no mortality among those treated with endovascular percutaneous therapy. All those treated in our center were by endovascular percutaneous and conservative therapy.

### Conclusion

Foreign bodies in the heart and vessels may be asymptomatic or present with a wide variety of symptoms. Health care providers should be aware of this rare event and act fast dealing with it.

**Keywords:** foreign body; heart; vessels; the percutaneous retrieval; intravascular foreign bodies

## Introduction

Foreign bodies in the heart and vessels are rare.[1] They are usually iatrogenic.[1] Embolism and arrhythmias may be part of the complications. [2,3] They can be diagnosed with X-ray, computerized tomography and echocardiography. They are removed by endovascular percutaneous or surgical methods. Conservative management is also an option. [3,4]

The objective of the study is to describe the pattern of treatment of foreign bodies referred to the Bayelsa Specialist Hospital.

## Methods:

It is a retrospective study. We searched the cardiac catheterization records of the hospital and identified 11 foreign bodies seen between 1st January 2018 and 30th April 2021. The site, etiology, clinical presentation, complications and management modalities and outcome were noted. Data were analyzed using SPSS version 25

## Results

The patients' mean age was 58. There were more women than men (7 versus 4 respectively). The most common foreign bodies were found in SVC, RA and inferior vena cava. [see Table 1]

Variable	Frequency	Percent (%)
Sex		
Female	7	63.4
Male	4	36.6
Total	11	100.0
Age (years)		
<60	5	45.5
≥60	6	54.5
Total	11	100.0
Median (Range)	58 (34)	

**Table 1:** Demography of Nigerians with Foreign body in the heart and vessels

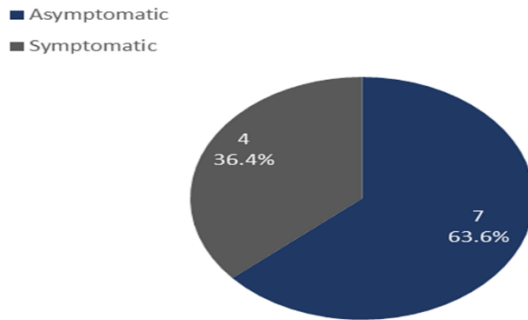
The mode of diagnosis of the heart and vessels foreign bodies are Computed Tomography, fluoroscopy and X-ray. This is shown in **Table 2**.

Aetiology	Site	Number of cases	Mode of diagnosis
Guidewire	IVC	2	Fluoroscopy
Guidewire	Radial artery	1	Fluoroscopy
IV Cannula	Left PA	2	CT angiogram
Dialysis catheter	RA	1	CXR (PA)
Tunnel catheter	SVC/RA	1	CXR (PA)
Chemotherapy pot	RCA & RV	2	CXR (PA)
IVC filter	IVC	2	CXR (PA)/Fluoroscopy
<b>Total</b>		11	

**Table 2:** Foreign body, site of occurrence, and mode of diagnosis

Foreign bodies in the heart were symptomatic in 36.4% [4 of the 11 patients]. The documented symptoms included palpitation, intermittent chest pain. Right atrial chamber, inferior and superior vena cava were

more sites. This is probably due to the source of migration of foreign bodies from femoral vein, jugular vein or the subclavian vein. [See figure 1]

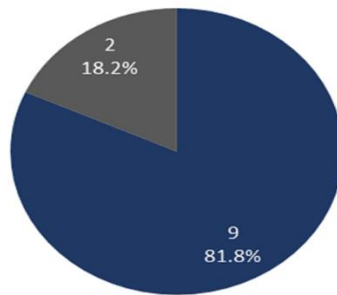


**Figure 1: Symptomatology in patients with foreign body in the heart and vessels**

A total of 81.8% [9 out of the 11 patients] presented within the first 24 hours. A majority of foreign bodies reached the heart by migration. There was no mortality among those treated with endovascular percutaneous therapy. All those treated in our center were by endovascular

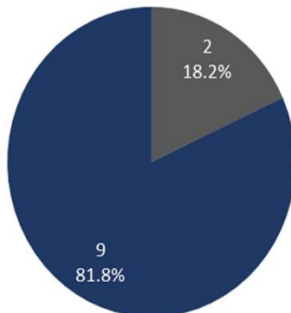
percutaneous and conservative therapy. The complication recorded were atrial and ventricular ectopics and non-sustained ventricular tachycardia on Electrocardiography. [see figure 2 and 3]

■ Within 24 hours  
■ After 24 hours



**Figure 2: Time of presentation**

■ Present  
■ Absent



**Figure 3: Complications from foreign body in the heart and vessels**

Nine patients received endovascular treatment while 2 were managed conservatively. They endovascular therapy with snare retrieval devices. The nine were successfully treated. There were no complications. The two patients with fractured cannulas were managed conservatively, they were asymptomatic. The fracture cannulas were in the distal

pulmonary artery. They were diagnosed with computed tomography but cardiac catheterization laboratory did not identified the fractured part of the cannulas. [see figure 4 and 5]

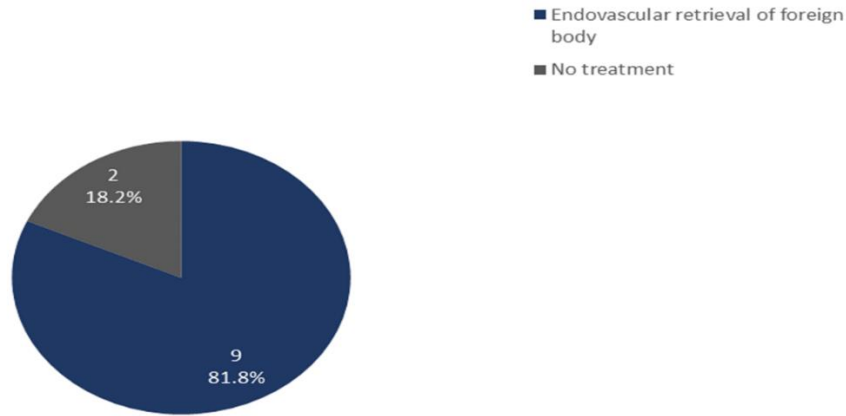
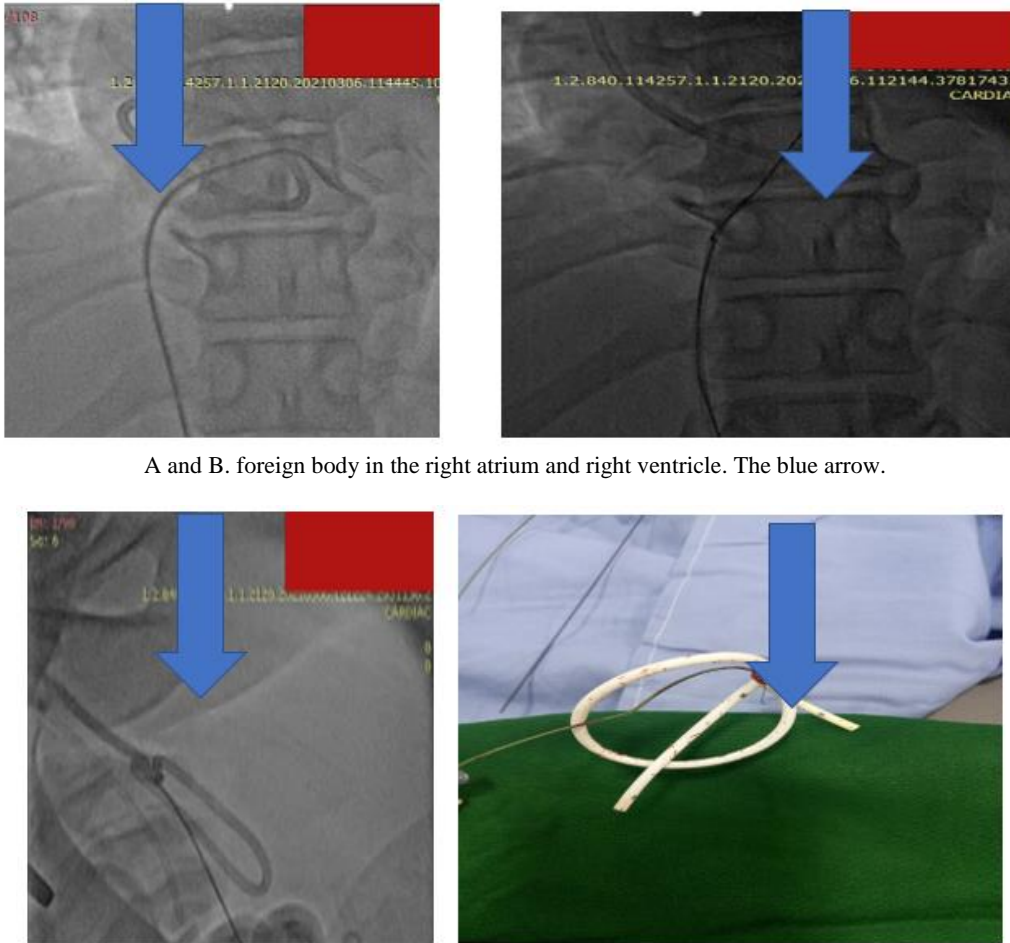


Figure 4: Modality of treatment



A and B. foreign body in the right atrium and right ventricle. The blue arrow.

C and D. During snaring and retrieval of foreign body



E. foreign body measured 28cm in length.

**Figure 5:** foreign body retrieval

## Discussion

The management of foreign bodies in the heart should be individualized. [3-4] Symptomatic foreign bodies should be removed by endovascular or surgical therapy. [5] In our review, we retrieved 9 of the 11 patients. The remaining 2 unretrieved were conservatively managed after a team review. Asymptomatic foreign bodies diagnosed immediately after the injury with associated risk factors should also be removed should be removed by endovascular or surgical therapy. [5] Asymptomatic foreign bodies that are incidental findings may be managed conservatively or removed.

### Classification of heart and vessel foreign bodies

There is no uniform classification of heart and vessel foreign bodies. However, we suggest that FB can be grouped as venous and arterial foreign bodies. Venous foreign bodies migrate and embolize to the right atrium, right ventricle and pulmonary artery. Arterial foreign bodies follow the direction of blood flow. Limb arterial foreign bodies embolize to the end of the extremities. Our review had one left radial artery that occurred during radial puncture. The fragmented guidewire embolized to the distal radial artery. It was retrieved through the femoral route.

The left ventricle can also harbor foreign bodies from penetrating injuries, or fragmented part of wires or catheter during percutaneous procedures within the cavity. Ayx and his colleagues in a review of the interventional removal of intravascular Medical Devices noted that a guide wire could not be extracted as it was already adhered with the vessel wall. [6] Our review noted two fragmented intravenous cannulas that migrated to the distal pulmonary artery. They were managed conservatively.

### Sites of heart and vessel foreign bodies

Surov et al in a systemic review of intravascular embolization of venous catheter-causes, clinical signs, and management the sites of catheter fragments following embolization were the superior vena cava or peripheral veins (15.4%), the right atrium (27.6%), right ventricle (22%), and pulmonary arteries (35%). [7] Our study also found SVC, IVC, and RA as more common sites of venous foreign bodies.

The present study found two guidewires were in the IVC; one guide wire is found in the distal left radial artery; two cannulas were found in the in the distal pulmonary arteries. A fractured dialysis catheter embolized to the right atrium. Another fractured tunnel catheter migrated to the right atrium and right ventricle. Two chemotherapy pots embolized to the RA. Another two IVC filter migrated to proximal IVC.

### Clinical presentation of foreign bodies

A systemic review by Soruv et al found clinical signs of catheter embolization to include catheter malfunction (56.3%), arrhythmia (13%),

pulmonary symptoms (4.7%), and septic syndromes (1.8%), and 24.2% of cases were asymptomatic. [7] The symptoms may include thrombosis, atrial and ventricular arrhythmias, infections and depressive-anxiety manifestation. Other complication may include endocarditis. The present study found 4 (36.4%) symptomatic and 7 (63.6%) were asymptomatic. Among the symptoms in our study were atrial and ventricular ectopics and non-sustained ventricular tachycardia.

### Diagnostic modalities

Heart and vessels foreign bodies could be diagnosed with echocardiography, X-ray, CT angiography, and fluoroscopy. In our study, diagnosis were made by CT angiogram, X-ray and fluoroscopy.

### Treatment of foreign bodies

The treatment could be conservative, endovascular and surgical removal. [8-12] Indication for surgical therapy is based on assessing the risk caused by the foreign in body compared with the risk of surgical intervention itself. [13-15] It is generally accepted that small, smooth, asymptomatic, noncontaminated foreign bodies embedded deep in the myocardium or arterial walls are not indicated for removal. [7] in the present study, the treated cases were by endovascular therapy. This is because percutaneous retrieval of intravascular foreign bodies is considered gold standard treatment as it is minimally invasive, relatively simple, safe procedure, with low complication rates compared to conventional surgical treatment.

### Conclusion

Foreign bodies in the heart and vessels may be asymptomatic or symptomatic. They are usually iatrogenic and should be referred for appropriate management. Bulker and lengthier devices may result in more severe complications.

### Abbreviations

SVC, Superior vena-cava  
RA, right atrium  
RV, right ventricle  
IVC, inferior venacava  
FB, foreign body

### Acknowledgements

Management of Bayelsa Specialist Hospital for the kind cooperation during the data collection.

### Authors' contributions

EAE review the patients at admission and confirmed the diagnosis. EAE performed the endovascular procedure, drafted the work and collected the data. RMA participated in the data collection and analysis. The authors read and approved the final manuscript.

### Funding

None.

### Availability of data and materials

All data generated or analyzed during this review are included in this publication.

### Ethics approval and consent to participate

Ethical approval was sort from the hospital ethical committee. Consent was sort from the patients that the data will be used for research without their names.

### Consent for publication

A written informed consent of all details/images or videos relating to the patient for publication was obtained from the patients

### Competing interests

The authors declare that they have no competing interests.

### References

- Leitman M, Vered Z. Foreign bodies in the heart. *Echocardiography*. 2015;32(2):365-371
- Carroll MI, Ahanchi SS, Kim JH, Panneton JM. Endovascular foreign body retrieval, *J Vasc Surg*.2013, 57:459-463
- Wang X, Zhao X, Du D, Xiang X. Management of metallic foreign bodies in the heart, *J Card Surg*. 2012, 27:70470-6
- Agarwal A, Quraishi MB, Mufti OI. Retained nail in the heart, *J Am Coll Cardiol*. 2012, 60:75-80
- Mainar V, Picó Aracil F, Bordes P, Ruiz Ros JA. Percutaneous extraction of intravascular foreign bodies: a series of 38 cases. *Campos Peris JV, Marín F. Rev Esp Cardiol*. 1996 Jan;49(1):41-47.
- Ayx I, Goessmann H, Hubauer H et al. Interventional Removal of Intravascular Medical Devices: Methods and Technical Success. *Fortschr Röntgenstr* 2016; 188: 566 - 573.
- Surov A, Wienke A, Carter JM, et al. Intravascular embolization of venous catheter--causes, clinical signs, and management: a systematic review. *JPEN J Parenter Enteral Nutr*. 2009;33(6):677-685
- Rodrigues R, Agostinho A, Anacleto G, Branco P, Gonçalves Ó. Endovascular Removal of Foreign Bodies. *Rev Port Cir Cardiorac Vasc*. 2017 Jul-Dec;24(3-4):109.
- Schechter MA, O'Brien PJ, Cox MW.Retrieval of iatrogenic intravascular foreign bodies. *J Vasc Surg*. 2013 Jan;57(1):276-281
- Koirala B, Shrestha KR, Thapa B, Sayami P. Migration of a piece of shrapnel: femoral vein to superior vena cava-azygous junction, *Eur J Cardiothorac Surg*, 2012,42: 584-586
- Wang X, Zhao X, Du D, Xiang X. Management of metallic foreign bodies in the hear, *J Card Surg*, 2012, 27:704-6
- Filho JMdML, Carnevale FC, Nasser F, Santos ACB, Sousa WOJ, Zurstrassen CE, Affonso BB. Endovascular techniques and procedures, methods for removal of intravascular foreign bodies. *Rev Bras Cir Cardiovasc*. 2010;25(2):202-8
- Yang X, Shen XA. Piece of glass in the heart. *Ann Thorac Surg*2006;81:335–336.6.
- Seipelt RG, Vazquez-Jimenez JF, Messmer BJ. Missiles in theheart causing coronary artery disease 44 years after injury.*Ann Thorac Surg* 2000;70:979–80.7. 15. Durpekt R, Vojacek J, Lischke R, Burkert J, Spatenka J.Kirschner wire migration from the right sternoclavicular jointto the heart: a case report. *Heart Surg Forum* 2006;9:840–842.



This work is licensed under Creative Commons Attribution 4.0 License

To Submit Your Article Click Here:

[Submit Manuscript](#)

DOI: [10.31579/2641-0419/260](https://doi.org/10.31579/2641-0419/260)

#### Ready to submit your research? Choose Auctores and benefit from:

- fast, convenient online submission
- rigorous peer review by experienced research in your field
- rapid publication on acceptance
- authors retain copyrights
- unique DOI for all articles
- immediate, unrestricted online access

At Auctores, research is always in progress.

Learn more <https://auctoresonline.org/journals/clinical-cardiology-and-cardiovascular-interventions>