

Cerebral Localization of Waldenstrom's Macroglobulinemia: Bing Neel Syndrome a Case Report

K. Khalfi^{1*}, N. Habchi¹, I. Ikhlef², M. Djafer¹

¹Neurosurgery Department, Mustapha Pacha University Hospital, Algiers, Algeria

²Anesthesia resuscitation department, Mustapha Pacha University Hospital, Algiers, Algeria

*Corresponding Author: K. Khalfi, Neurosurgery Department, Mustapha Pacha University Hospital, Algiers, Algeria.

Received Date: December 31, 2021; Accepted Date: February 04, 2022; Published Date: February 11, 2022

Citation: K. Khalfi, N. Habchi, I. Ikhlef, M. Djafer. (2022). cerebral localization of Waldenstrom's macroglobulinemia: Bing Neel syndrome a case report. Cancer Research and Cellular Therapeutics. 6(2); DOI: [10.31579/2640-1053/107](https://doi.org/10.31579/2640-1053/107)

Copyright: © 2022 K. Khalfi, This is an open-access article distributed under the terms of the Creative Commons Attribution License, which permits unrestricted use, distribution, and reproduction in any medium, provided the original author and source are credited.

Abstract

In Waldenström's disease, direct involvement of the nervous system by tumor infiltration is rare and exceptional, forming Bing-Neel syndrome, which groups together the central neurological damage of this disease.

It is associated with neurological manifestations with confusion, temporo-spatial disorientation or motor impairment.

The Bing and Néel syndrome must be differentiated and discussed in the face of affections of the central nervous system such as multiform glioblastomas or multifocal leukoencephalopathies as well as primary brain lymphoma.

Keywords: dysglobulinemia; bing-neel syndrome; waldenström; monoclonal immunoglobulin

Introduction

Waldenström's macroglobulinemia (WM) is, according to the WHO classification, a lymphoplasmacytic lymphoma in which the bone marrow is infiltrated by clonal lymphoplasmatic cells associated with M immunoglobulin (Ig) [1].

The cerebral localization of **Waldenstrom's dysglobelinemia** is extremely rare. it results from the infiltration of the central nervous system by malignant lymphocytes. In 1936 BING AND NEEL described a syndrome made of association with hyperglobulinemia; signs of CNS involvement and infiltration of the brain by malignant lymphocytes. Since BING-NEEL syndrome is used to define rare cases of localization of Waldenstrom's disease in the central nervous system.

Case report

Reporting to us the case report of an 80-year-old patient who was admitted

to our department for management of hydrocephalus in a double cerebral location.

The patient is known and monitored for WALDENSTROM disease in the hematology department. The treatment followed at home is based on polychemotherapy with good clinical and biological improvement.

The patient is hospitalized at our department for consciousness disorders

On examination we find:

- an unconscious patient (GCS = 8/15)
- the pupils are reactive
- left hemiparesis

As part of the exploration report; a cerebral CT scan performed in him found a left temporal tumor process probably intra ventricular. (Fig 1)

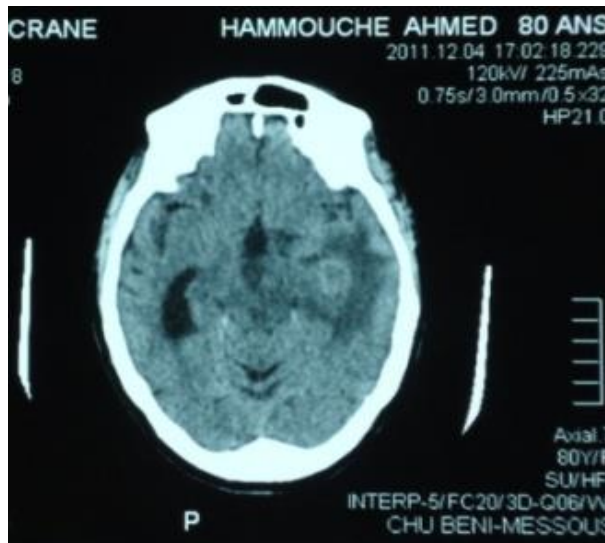


Figure 1: CT image of a deep tumor nodule

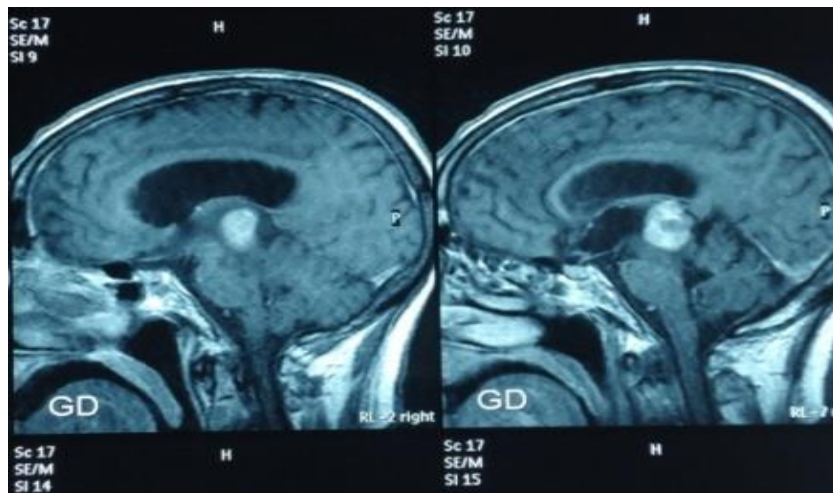


Figure 2: MRI appearance of the tumor nodule taking the contrast

Brain MRI revealed a nodular process straddling the post wall of the third ventricle and TECTUM, obliterating the midbrain aqueduct and responsible for active upstream hydrocephalus (Fig 2).

A second nodule of the same nature in projection of the left hippocampus measuring 20mm (Fig 3)

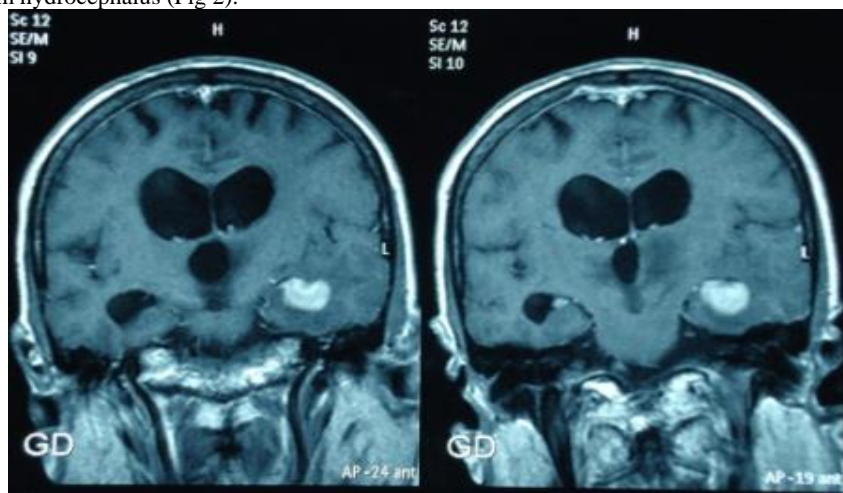


Figure 3: Appearance of the 2nd tumor nodule in the left hippocampus

A secondary nature is mentioned first. Faced with the disturbance of consciousness, the patient received a frontal puncture as part of the emergency.

The course is marked by the onset of an epileptic seizure in the upper right limb which became generalized secondarily.

The indication of VCS (ventriculo-cisternostomy) was discussed in our patient in order to treat both hydrocephalus and to perform biopsies of tumor nodules.

CSF immunoelectrophoretic analysis for IGM peaks in CSF was performed. The results confirm the presence of a monoclonal component in the gamma position at a concentration equal to 9.84 g / 1 CM already typed. This is a lambda light chain IGM.

The course is marked by the death of the patient following complications of his disease.

Discussion

Waldenstrom's disease is a rare condition. It represents 2% of monoclonal gammopathies [2]. Neurological complications are seen in 25% of patients with the disease. The most frequent manifestation is poly sensitivomotor neuropathy.

BING AND NEEL syndrome is the neurological complication of WALDENSTROM disease. It is due to lympho-plasma cell infiltration and deposition of IGM in the brain. It is an extremely rare complication [3].

The clinical presentations of the syndrome are varied, and the diagnosis is often difficult. BING-NEEL syndrome exists in 02 forms [4].

- The infiltrating and diffuse form
- The tumor form

In the diffuse form: lymphoid infiltration which is diffuse to the nervous system which may be expressed by signs of diffuse encephalopathy or signs of meningeal and meningo-radicular involvement)

In the tumor form: it corresponds to an intracranial expansive process which can be single or multi-focal and generally is localized in hemispherical regions under deep cortical. The most frequently encountered clinical signs are intracranial hypertension, focal deficit, partial or generalized seizures [4].



This work is licensed under Creative Commons Attribution 4.0 License

To Submit Your Article Click Here:

[Submit Manuscript](#)

DOI: [10.31579/2640-1053/107](https://doi.org/10.31579/2640-1053/107)

On brain CT and MRI, cerebral localization appears in the form of contrast enhancement and / or thickening in the meninges.

To raise the diagnosis of BING AND NEEL syndrome, in the first place, it is necessary to confirm WALDENSTROM'S disease. Cytological analysis of the CSF, supplemented by immunostaining on a slide, is essential. cortico-meningeal or cerebral biopsy is sometimes necessary for confirmation of the diagnosis in 15% of cases, and MRI is essential to exclude vascular symptoms linked to hyperviscosity, in particular using diffusion sequences (in case of hyperviscosity-related ischemic disease) [5].

Conclusion

BING AND NEEL syndrome must be differentiated and discussed in the face of central nervous system affections such as multiform glioblastomas or multifocal leukoencephalopathies as well as primary brain lymphoma.

The cerebral location of Waldenstrom's disease must be taken into consideration and discussed with pathologies of the central nervous system, especially in a patient with this condition despite its rarity.

References

- Harris NL, Jaffe ES, Diebold J, Flandrin G, Muller-Hermelink HK, Vardiman J, et al. (1999). World Health Organization Classification of neoplastic diseases of the hematopoietic and lymphoid tissues: report of the Clinical Advisory Committee meeting Airlie House, Virginia, November 1997. *J Clin Oncol*. 17:3835-3849.
- Drouet t, Behin a, Psimaras d, Choquet s, Guillevin r, Hoang xuan k. (2010). [bing-neel syndrome revealing waldenström's macroglobulinemia]. *Rev Neurol (paris)*. 166(1):66-75.
- neau jp, Guilhot f, Dumas p, Besson i, Rivasseau-Jonveaux t, Gilr. (1991). Central nervous system involvement in Waldenstrom's disease.bing-neel syndrome. 3 cases. *rev neurol (paris)*. 147:56-60.
- Drouet T, Behin A, Psimaras D et al. (2010). Syndrome de Bing-Neel révélateur d'une maladie de Waldenström : étude d'un cas et revue de la littérature. *Rev Neurol (Paris)*. 166(1):66-75.
- A. Morin, L. Musset, M. Costopoulos, K. Mokhtari, F. Charlotte, S. Choquet, K. Hoang-Xuan. (2015). Le syndrome de Bing-Neel .Correspondances en Onco-Hématologie - Vol. X - n° 1 - janvier-fevrier.

Ready to submit your research? Choose Auctores and benefit from:

- fast, convenient online submission
- rigorous peer review by experienced research in your field
- rapid publication on acceptance
- authors retain copyrights
- unique DOI for all articles
- immediate, unrestricted online access

At Auctores, research is always in progress.

Learn more <https://auctoresonline.org/journals/cancer-research-and-cellular-therapeutics>