

Mandibular AV Malformation: Life-Threatening Bleeding from the Mouth managed by Endovascular Intervention Complicated by Acute Ischemic Stroke on table. Case Report

Mohammed Habib^{1*}, Mohammed Hillis², Aghayed Almobayed³, Mohammed Alhadad⁴, Khaled Alkhodari⁵

¹Head of Cardiology Department. Alshifa hospital, Qatar.

²Consultant Congenital Cardiovascular Anomaly. Alshifa Hospital, Qatar.

³Head of Maxillofacial Surgery Department, Alshifa hospital, Qatar.

⁴Vascular Surgery Department. Alshifa Hospital, Qatar.

⁵Cardiology resident. Alshifa hospital, Qatar.

***Corresponding Author:** Mohammed Habib, Head of Cardiology Department. Alshifa hospital, Qatar.

Received date: November 25, 2021; **Accepted date:** December 25, 2021; **Published date:** February 18, 2022

Citation: Mohammed Habib, Mohammed Hillis, Aghayed Almobayed, Mohammed Alhadad, Khaled Alkhodari (2022) Mandibular AV Malformation: Life-Threatening Bleeding from the Mouth managed by Endovascular Intervention Complicated by Acute Ischemic Stroke on table. Case Report *J. Cardiology Research and Reports* 4(2); DOI: [10.31579/2692-9759/041](https://doi.org/10.31579/2692-9759/041)

Copyright: © 2022, Mohammed Habib, This is an open access article distributed under the Creative Commons Attribution License, which permits unrestricted use, distribution, and reproduction in any medium, provided the original work is properly cited.

Abstract

Arteriovenous malformations (AVM) of mandibula are rare abnormal congenital vascular condition that can result in serious complications. Although, various treatment options have been advocated in the literature, there seems to be no complete consensus on a suitable treatment option in these cases. Here, we describe a case of mandibular AVM, who has presented with massive oral bleeding, treated successfully by embolization of the bilateral external carotid arteries and the left superior thyroid artery. During the procedure, the patient developed symptoms of acute ischemic stroke that was diagnosed and managed during the same session by endovascular techniques.

Keywords: arteriovenous malformations; endovascular intervention; acute ischemic stroke

Introduction

Mandibular arteriovenous malformations (AVMs) are very rare congenital vascular anomalies. The incidence of vascular anomalies accounting about 1% of all vascular lesions, and only 5% of them occur in the mandibula (1). The major symptoms are massive bleeding after tooth extraction or recurrent spontaneous bleedings (2). While treatment is unneeded for small and asymptomatic mandibular AVMs, the symptomatic AVMs should be treated with surgery, embolization, or both (3). We present a case with recurrent spontaneous bleedings due to a large mandibular AVM refractory to surgical ligation of left proximal external carotid artery four years ago.

Case Presentation

A 27-year-old male dentist who has a huge mandibular AVM for the last five years. During this period, the patient had his first bleeding four years ago that was managed by the left external carotid artery ligation. After that, he had a CT angiography that showed a huge left mandibular AVM.

The patient was advised to totally control the AVM by endovascular intervention, yet he did not seek advanced management for his case.

This time, the patient has presented to the emergency room of Al-Shifa Hospital (Gaza, Palestine) due to a sudden massive mouth bleeding. He was controlling the bleeding by clenching his mouth. Upon arrival, the patient was hemodynamically unstable, the blood pressure was 85/40 mmHg and heart rate of 120 beat per minute. Subsequently, two large-pore IV cannulas were inserted and blood samples was drawn. Hemoglobin level was measured at 7.2 g/dL and blood transfusion was given (6 Units of RBC), creatinine level:1.7, IV fluids was started. As a result, maxillofacial and vascular surgeons were called to control the bleeding and they preferred the urgent head and neck Angiography CT and endovascular management.

Urgent CT angiography confirmed the presence of a large AVM fed by a branch of the right and left external carotid arteries branches and left thyroid artery (figure 1)

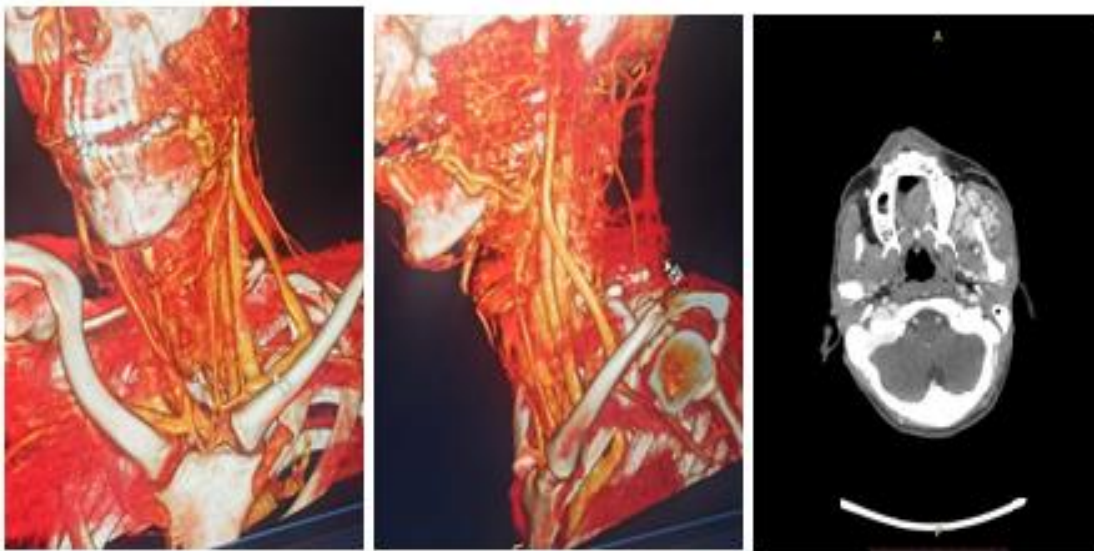


Figure 1: CT of head and neck: huge left mandibula AVM with multiple collateral from left and right external carotid arteries branches and left thyroid artery.

The patient Urgently patient transferred to endovascular catheterization unit. After insertion 6 French femoral sheath in the right femoral artery access, the left common carotid artery was engaged by Right Judkin's catheter. Then, selective cannulation of the left external carotid artery was done followed first selective angiography of the left external carotid angiography suggested huge AVM in left mandibular was seen (figure

2a). Due to previous ligation and multiple branches and large nidus, micro-catheter could not be selectively placed in the nidus. (figure 2b). So, the left maxillary artery branches were embolized by multiple coils (figure 2c). and the origin of the left external carotid artery was occluded using Patent Ductus Arteriosus (PDA) (4/6 mm amplatzer) device (figure 2d)

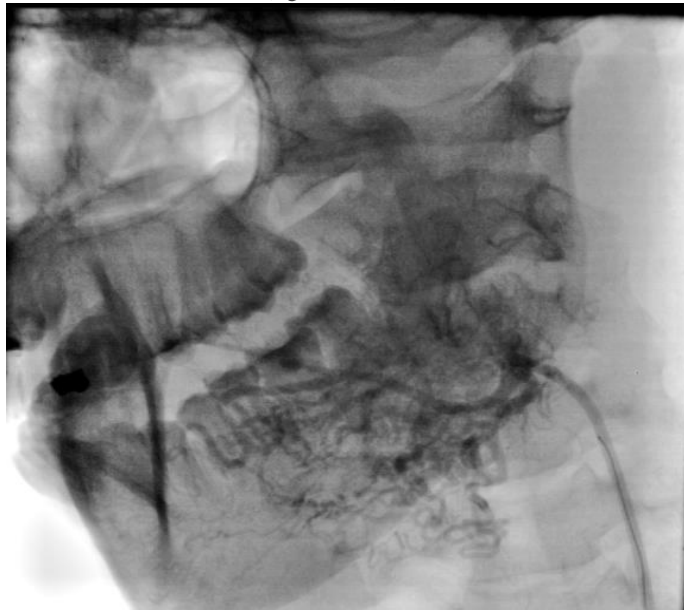

Figure 2a: AVM in left mandibular

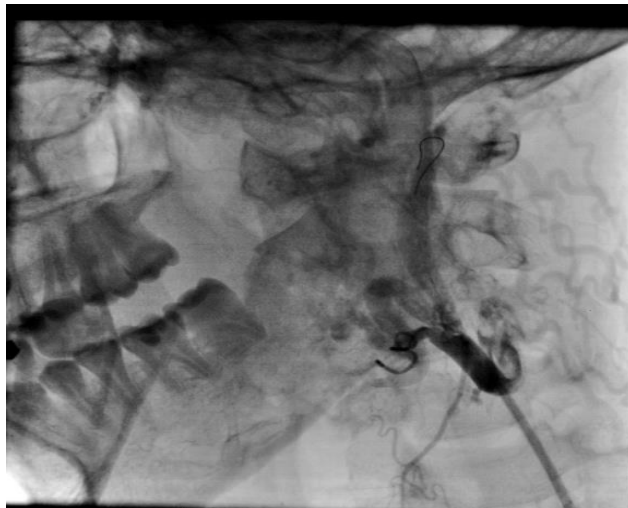


Figure 2b: previous ligation in external carotid artery

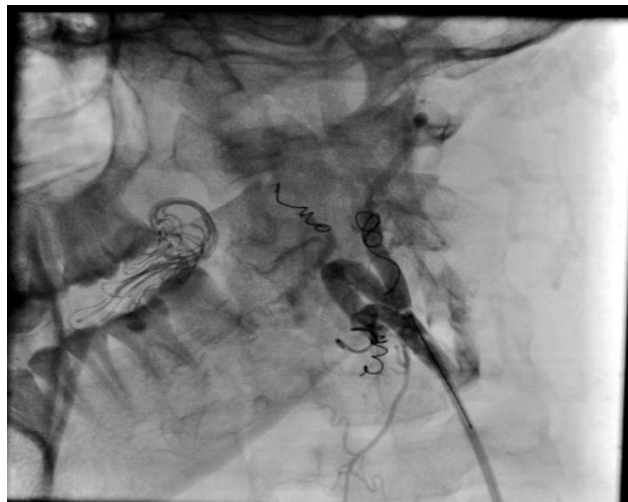


Figure 3c: multiple coils in left External carotid artery branches

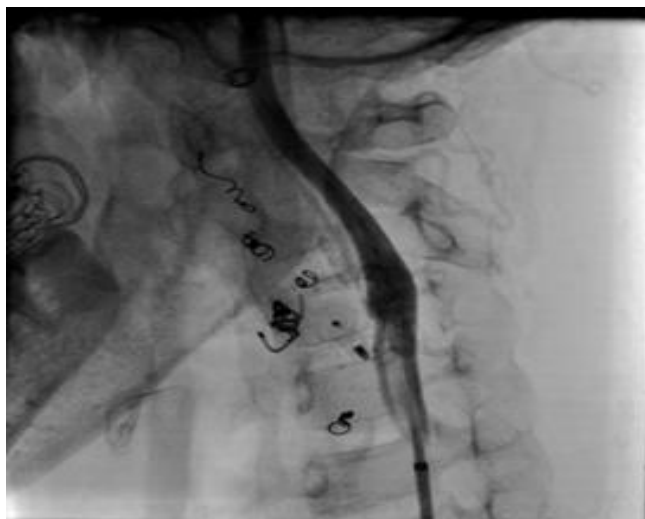

Figure 3d: PDA device in ostial left External carotid artery

Then bleeding still continue and embolization insufficient left superior thyroid artery was embolized by coil (figure 2e).

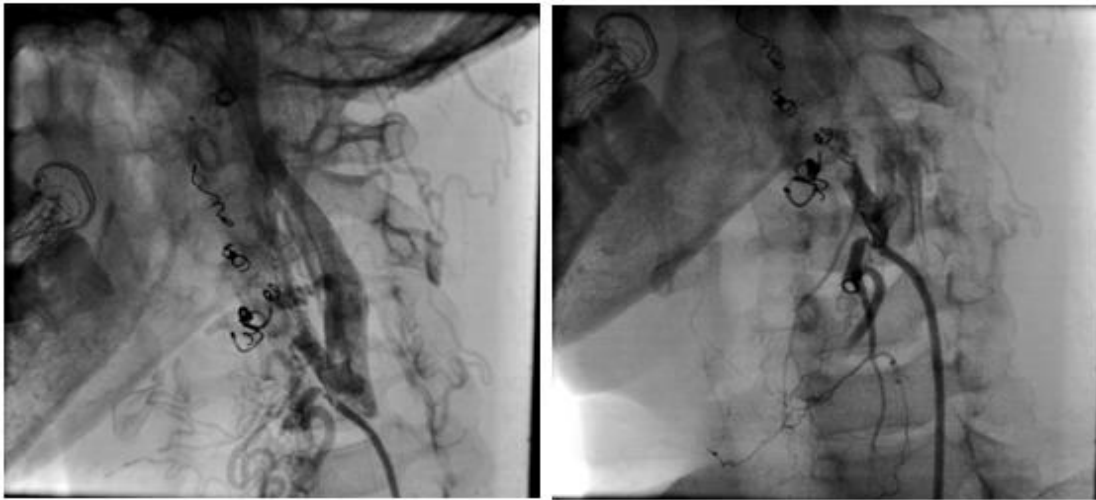


Figure 2e: left superior thyroid artery collateral to left mandibular artery and successful coil embolization

Then bleeding still continue and embolization insufficient. So that Right carotid artery angiography was done and suggested that the AVM in the left mandibula was also fed from the right facial artery. As a result, the

right external carotid artery was occluded using PDA (6/4mm amplatzer) device (figure 2f, 2g)

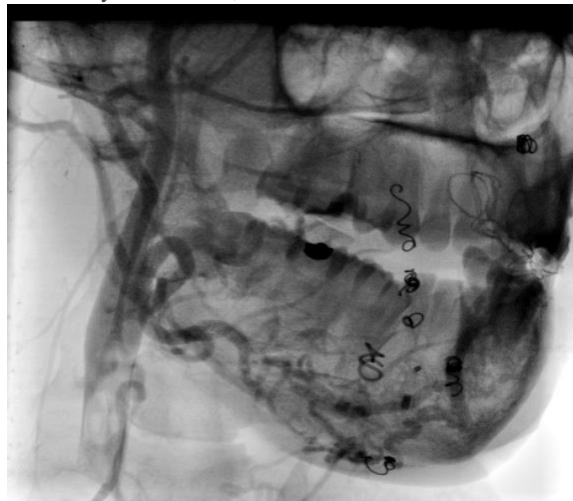


Figure 2f: Selective right carotid angiography suggested collateral from right mandibular artery to left mandibular artery.

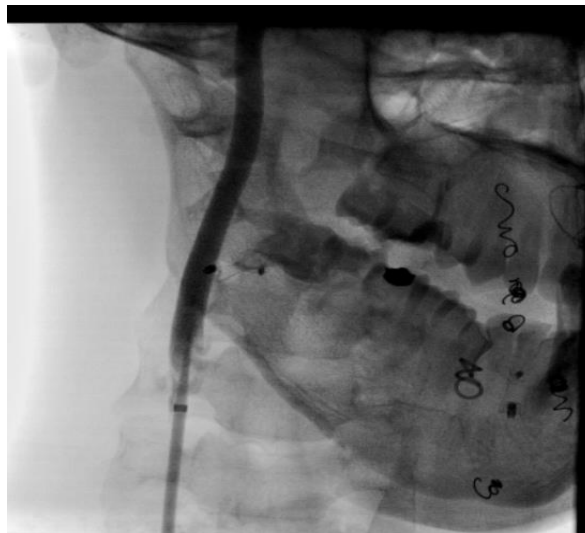

Figure 2g: PDA device in deployed at ostial Right External carotid artery.

Control Brain CT angiography in the next day suggested totally occluded in bilateral external carotid arteries. (figure 3)

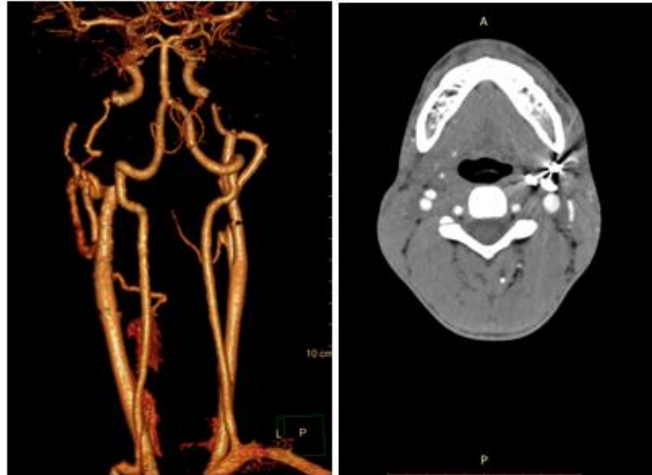


Figure 3 Control Brain CT angiography: totally occluded in bilateral external carotid arteries.

During the procedure, the bleeding did not stop, and it was controlled by the assistance of the patient by clinching his mouth, and pRBCs transfusion was continuous along the procedure and a total of six units were transfused. Additionally, the patient developed right side hemiplegia and he was diagnosed with acute ischemic stroke; thus, mechanical thrombectomy in the same session was done to remove small thrombus from left middle cerebral artery and complete reversal of symptoms was noted.

Discussion

To the best of our knowledge this is the first case in literature that was treated successfully using PDA device to control life treating bleeding from the mouth due to left mandible AVM by occlusion of bilateral external carotid arteries and coil embolization for the left superior thyroid artery after previous ligation of the proximal left external carotid artery. On the other hand, the procedure was complicated by acute ischemic stroke that was managed by thrombus aspiration from the left middle cerebral artery.

AVMs are the most common high-flow lesions, frequently identified in the limbs, head and neck. However, lesions of the oral and maxillofacial regions are very rare. AVMs have been reported in the maxilla, but at half the frequency of AVMs in the mandible. AVMs of the mandibula are relatively rare, with fewer than 200 cases reported in the literature [4].

Mandible is much denser and thicker than that the maxilla, so blood pressure in the varix of mandible is higher. So that, there is a difficulty in controlling emergency bleeding in the AVM of the mandible by local pressure only [5]. If the AV shunts exists, embolic material could pass through the internal jugular vein, resulting in pulmonary embolism [6-10]. As a result, embolization using coils or vascular plug accompanied with endovascular embolization is more effective.

In our case we used the embolization material, coils and PDA device, and we did not use alcohol particles that have a risk of passing through the internal jugular vein leading to pulmonary embolism. Despite that during embolization of left external carotid artery left sided hemiplegia was happened and treated urgently by aspiration of thrombus from left middle cerebral artery.

Wu et al. [11] show that proximal ligation in 9 (~30%) of 29 patients treated for AVM of the auricle but that the condition was exacerbated in all patients with 8 requiring auricular resection and 1 requiring additional treatment. They excluded proximal ligation from treatment options for AVM, because it makes subsequent trans-catheter treatments difficult and failure.

Slaba et al. [12] evaluated 25 patients with AVM of the tongue and reported that 3 (25%) of the 12 symptomatic patients who underwent ipsilateral external carotid artery ligation at another facility showed marked development of collateral network.

In addition, Yamamoto et al. [13] reported a case in which TAE was performed for AVM of the mandible via the maxillary artery, facial artery, lingual artery, and ocular artery but was not effective due to the development of collateral network from the internal carotid artery and vertebral artery

Although surgery alone is not recommended, a combination of surgery with endovascular embolization (including sclerotherapy) can be recommended depending on the case.

Conclusion

Endovascular treatment by embolization is performed using various approaches and embolic agents selected depending on the facility and the patient's characteristics. There are a wide variety of surgical treatment options, yet proximal surgical ligation alone is not effective to treat AVM. Therefore, we see that the treatment may be performed by combining many options of surgery and interventions. AVM of the mandible should be treated at main hospitals where multidisciplinary treatment can be performed by experienced physicians.

Consent:

Verbal informed consent was obtained from the patient for the publication of this report and any accompanying images.

Conflict of interests: We disclose no conflict of interests.

References

1. Theologie-Lygidakis N, Schoinohoriti o, Tzermpos F, Christopoulos P, Iatrou I. (2015) Management of Intraosseous Vascular Malformations of the Jaws in Children and Adolescents: Report of 6 Cases and Literature Review. *J Oral Maxillofac Res*, 6: e5.
2. Fathi M, Manafi A, Ghenaati H, Mohebbi H. (1997) Large arteriovenous high-flow manibular malformation with exsanguinating dental socket haemorrhage: a case report. *J Craniomaxillofac Surg*, 25: 228-31.
3. Svane TJ, Smith BR, Wolford LM, Pace LL. (1989) Arteriovenous malformation of the mandible and its treatment: a case report. *Oral Surg Oral Med Oral Pathol*, 67: 379-83
4. Fan X, Qiu W, Zhang Z, Mao Q. (2002) Comparative study of clinical manifestation, plain-film radiography, and computed tomography scan in arteriovenous malformations of the jaws. Oral Arteriovenous malformation of the mandible SR Shailaja et al. *Dentomaxillofacial Radiology Surg Oral Med Oral Pathol Oral Radiol Endod*, 94:503–509
5. Siu WWY, Weill A, Garipey JL, Moret J, Marotta T: (2001) Arteriovenous Malformation of the Mandible: Embolization and Direct Injection Therapy. *J Vasc Interv Radiol*, 12:1095-1098
6. Yoshiga K, Tanimoto K, Okui T, Kobayashi M: (2003) High-flow arteriovenous malformation of the mandible: treatment and 7-year follow-up. *British J Oral Maxillofac Surg* 41:348-350.
7. Giaoui L, Princ G, Chiras J, Guilbert F, Bertrand JC: Treatment of vascular malformations of the mandible: a description of 12 cases. *Int J Oral Maxillofac Surg* 2003;32:132-136
8. Siu WWY, Weill A, Garipey JL, Moret J, Marotta T: (2001) Arterio-venous Malformation of the Mandible: Embolization and Direct Injection Therapy. *J Vasc Interv Radiol* 12:1095-1098.
9. Corsten L, Bashir Q, Thornton J, Aletich V: (2001) Treatment of a Giant Mandibular Arteriovenous Malformation With Percutaneous Embolization Using Histoacrylic Glue: A Case Report. *J Oral Maxillofac Surg*; 59:828-832.
10. Persky MS, Yoo HJ, (2003) Berenstein A: Management of Vascular Malformations of the Mandible and Maxilla. *Laryngoscope*, 113:1885-1892
11. Wu JK, Bisdorff A, Gelbert F, Enjolras O, Burrows PE, Mulliken JB. (2005) Auricular arteriovenous malformation: evaluation, management, and outcome. *Plast Reconstr Surg*. 115:985–95
12. Slaba S, Herbretreau D, Jhaveri HS, Casasco A, Aymard A, Houdart E, et al. (1998) Therapeutic approach to arteriovenous malformations of the tongue. *Eur Radiol*. 8:280–5
13. Yamamoto T, Kanamura N, Tsukitani K, Hori N, Iehara T, Fukushima Y, et al. (1999) Direct embolization for a life-threatening mandibular arteriovenous malformation by means of hypothermic cardio-pulmonary arrest. *Kyoto Furitsu Ika Daigaku Zasshi*. 108:981–94.



This work is licensed under Creative Commons Attribution 4.0 License

To Submit Your Article Click Here:

Submit Manuscript

DOI: [10.31579/2692-9759/040](https://doi.org/10.31579/2692-9759/040)

Ready to submit your research? Choose Auctores and benefit from:

- fast, convenient online submission
- rigorous peer review by experienced research in your field
- rapid publication on acceptance
- authors retain copyrights
- unique DOI for all articles
- immediate, unrestricted online access

At Auctores, research is always in progress.

Learn more <https://auctoresonline.org/journals/cardiology-research-and-reports->