

Exercise Transcutaneous Oxygen Pressure (Extcpo2) Measurement is a Reliable Method of Evaluation of Internal Iliac Artery flow Compromise

Indrani Sen MBBS^{1*}, Manju Kalra MBBS¹, David A Liedl RN², Guillaume Mahe MD,PhD³, Pierre Abraham MD,PhD⁴, William Harmsen MS⁵ and Paul W Wennberg MD²

¹Division of Vascular and Endovascular Surgery, Mayo Clinic College of Medicine, Rochester, MN, USA.

²Gonda Vascular Center, Mayo Clinic, Rochester, MN, USA.

³INSERM Clinical Investigation Center CIC 1414, Rennes, France.

⁴Laboratory of Vascular Investigations, University Hospital, Angers, France; and Faculty of Medicine, LUNAM University, Angers, France.

⁵Department of Biostatistics, Mayo Clinic College of Medicine, Rochester, MN, USA.

***Corresponding Author:** Indrani Sen, Division of Vascular and Endovascular Surgery, Mayo Clinic College of Medicine, 200 First Street SW, Rochester, MN 55905, USA.

Received Date: 27 October 2021 | **Accepted Date:** 03 January 2022 | **Published Date:** 14 January 2022

Citation: I Sen, M Kalra, David A Liedl, G Mahe, P Abraham, et al. (2022). Exercise Transcutaneous Oxygen Pressure (Extcpo2) Measurement is a Reliable Method of Evaluation of Internal Iliac Artery flow Compromise. *Journal of Clinical Surgery and Research*. 3(2); DOI: [10.31579/2768-2757/036](https://doi.org/10.31579/2768-2757/036)

Copyright: ©2022 Indrani Sen, This is an open-access article distributed under the terms of the Creative Commons Attribution License, which permits unrestricted use, distribution, and reproduction in any medium, provided the original author and source are credited.

Abstract:

Clinical differentiation of buttock claudication from pseudo-claudication (neuromuscular etiology) is often challenging and cannot be diagnosed non-invasively using standard ankle-brachial index (ABI) with exercise. The aim of this study was to evaluate the reliability of exercise transcutaneous oximetry (ExTcPO₂) to accurately detect significant internal iliac artery (IIA) inflow stenosis.

Methods: Data from a prospectively maintained registry of consecutive patients undergoing ExTcPO₂ for evaluation of buttock and hip exertional discomfort as well as arterial imaging within 12 months were retrospectively analyzed. ExTcPO₂ was performed on a treadmill (10% slope; 2 mph speed); measured at buttocks, upper back and calf (rest, with exercise) to document the baseline normal, degree of change with exercise and recovery patterns. A Delta from Resting Oxygen Pressure (DROP) (buttock- back TcPO₂ mmHg) ≥ 15 mm Hg was considered significant. A blinded physician performed aorto-iliac arterial stenosis quantification and receiver operating characteristic (ROC) curve analysis was used to determine sensitivity and specificity to diagnose severe inflow reduction ($\geq 70\%$) based upon a diagnostic DROP ≥ 15 mm Hg.

Results: One hundred and eleven patients (M:F::79:32, mean age 70, range 18-90 years) with available concomitant imaging (CTA 90, DUS 21) were included in the study. Indications for testing were suspected vascular (82), or neuromuscular (29) symptoms. ExTcPO₂ study confirmed the clinical suspicion of the state of IAA inflow in 81% (91/111) of patients. DROP ≥ 15 mm Hg had a sensitivity, specificity, PPV, NPV of 56, 80, 70, and 68% respectively for prediction of severe IIA inflow reduction (p value < 0.001 ; OR 1.116, 95% CI 1.057-1.157; C- statistic 0.76, SE=0.03).

Aorto-iliac arterial reconstruction to treat severe IIA flow compromise was performed in 16 patients. Revascularization was **Direct Antegrade** in 12 patients (IIA PTA /stenting – 4, aorto-iliac stenting /endarterectomy – 9), **Direct Retrograde** (aorto-biiliac bypass) in 1 and **Indirect** via increased collateral flow (profundoplasty) in 3. Post-operatively symptom relief was noted in 15/16 patients and objectively demonstrated on ExTcPo₂ in 6/7 (Figure 2). One patient did not improve clinically, or on EXTcPO₂ following **Indirect** revascularization.

Conclusion: Exercise transcutaneous oximetry can reliably diagnose significant IIA inflow stenosis. It is simple, non-invasive and can serve as a valuable screening tool to differentiate buttock claudication from other neuromuscular causes of low back, buttock and hip discomfort as well as post-operatively to confirm adequacy of aorto-iliac revascularization in conjunction with standard, noninvasive vascular evaluation with ABI.

Keywords: buttock claudication; peripheral artery disease; exercise test; oximetry; transcutaneous oxygen pressure

Introduction

Low back pain associated with hip, buttock, or thigh pain is a common problem in the elderly. Causation is often multifactorial; secondary to peripheral arterial disease (PAD) or other diseases such as lumbar spinal stenosis, sciatica, or hip osteoarthritis. True claudication (pain that is absent at rest, appears during exercise, reproducible and relieved by rest) is easier to differentiate from pseudo-claudication when it occurs in the calf or thigh in the lower limb (distal claudication) [1]. Even so, it necessitates the use of noninvasive physiological assessments. The American College of Cardiology/American Heart Association (ACC/AHA) statements suggest measuring ankle-brachial indices (ABIs), pulse volume recordings, segmental pressures, duplex ultrasound and/or exercising testing with ABI to evaluate claudication versus pseudo-claudication to integrate the clinical and physiologic information [2]. However, these tests are used mainly in the diagnosis and management of distal claudication; these and other tests like Near Infra-Red Spectroscopy (NIRS) and penile-brachial index have not proven reliable in diagnosing proximal claudication as they do not directly assess the arterial beds involved in causation of the latter [3, 4].

Exercise-TcPO₂ has been used in France to diagnose proximal claudication due to PAD with a good sensitivity (79%) and specificity (86%) to detect significant lesions (stenosis ≥75%) in the arterial tree of the pelvic circulation when compared to angiography as a gold standard [5]. We adopted a technique of exercise transcutaneous oxygen pressure measurement (exercise-TcPO₂) since 2003 and had previously reported the first case in the United States of a patient with proximal claudication being evaluated by an exercise-TcPO₂ protocol both before and after angioplasty [6]. In this study we report our results on the role of exercise-TcPO₂ in the diagnosis and follow up of patients with proximal claudication due to PAD and the clinical- imaging correlation demonstrating its utility.

Methods

Study design and population

Data from a prospectively maintained registry of consecutive patients undergoing ExTcPO₂ between January 2013 to January 2017 for evaluation of buttock and hip exertional discomfort as well as arterial imaging within 12 months were retrospectively analyzed. Patients being referred to the lab were those who needed differentiation of vasculogenic from neurogenic claudication and to evaluate the relative severity of buttock vs calf claudication. Demographic characteristics such as age,

gender, nature of symptoms, location and laterality of symptoms, nature of vascular intervention and post procedure outcome were recorded. Procedural details of revascularization were noted. Aorto-iliac arterial reconstruction to treat severe IIA flow compromise was classified as direct antegrade (IIA PTA /stenting; aorto-iliac stenting /femoral endarterectomy), direct retrograde (aorto-biiliac/femoral bypass) and Indirect via increased collateral flow (profundoplasty). The study was approved by the Institutional Review Board.

ExTcPO₂ testing protocol

Exercise-TcPO₂ was performed according to the published French algorithm using calibrated TcPO₂ probes (TCOM/TcPO₂;PF 5040 TcPO₂/CO₂ Unit; Perimed®; Jarfalla, Sweden) using a 5-electrode system. The temperature of each probe was set to 45°C, which allows maximal vasodilation and decreases the arterial to skin surface oxygen pressure gradient. A reference electrode (chest probe) was placed between the scapulae to measure systemic changes in TcPO₂ during exercise. One electrode was positioned on each buttock, 4 to 5 cm behind the bony prominence of the trochanter, and on the calf (Figure 2). Once the electrodes were in position, baseline values were obtained with the patient standing for 10 minutes. Exercise was performed on a treadmill at a 10% slope and a speed of up to 2mph. A 12-lead ECG monitored heart rate and rhythm for ischemic changes during the exercise test procedure. The patient was encouraged to walk for the longest time possible to mimic symptoms. Exercise was discontinued at the patient's request (or, by protocol, up to maximum exercise duration of 12 minutes). The measurements from the TcPO₂ electrodes were used to calculate the Delta from Resting Oxygen Pressure (DROP) index (expressed in mmHg), the absolute change in TcPO₂ from resting value in each of the three limb probes, corrected for the absolute change in TcPO₂ at the chest electrode. The equation for the DROP index is as follows:

$$\text{DROP}_{(\text{site})} = [\text{PO}_2(\text{site})_t - \text{PO}_2(\text{site})_{t_0}] - [\text{PO}_2(\text{chest})_t - \text{PO}_2(\text{chest})_{t_0}]$$

PO₂(site)_t is the oxygen pressure at a measurement site at time t, PO₂(site)_{t0} is the mean oxygen pressure at a measurement site over the baseline resting period; PO₂(chest)_t is the oxygen pressure at a chest site at time t and PO₂(chest)_{t0} is the mean oxygen pressure at a chest site over the resting period. The DROP index was automatically calculated and displayed graphically by a dedicated software package that allowed real-time monitoring of DROP values at the levels where the probes were placed. The recovery pattern of the TCO₂ was also noted. A Delta from Resting Oxygen Pressure (DROP) (buttock- back TcPO₂ mmHg) ≥15 mm Hg was considered significant.

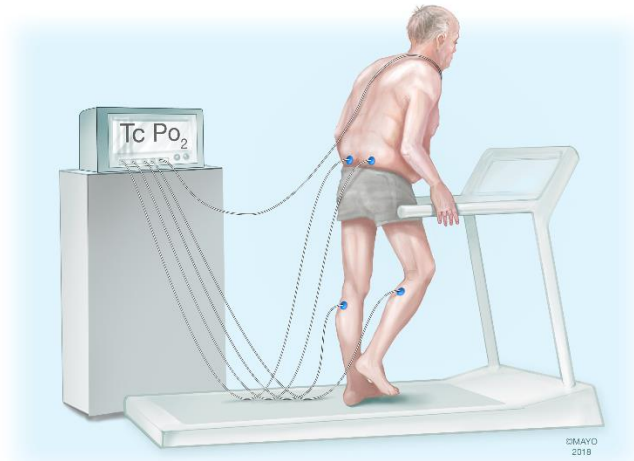


Figure 2: Illustration depicting placement of tco2 probes during Exercise transcutaneous oxygen pressure (ExTcPO2) measurement. Electrodes positioned on chest, each buttock and on the calf.

Imaging

A physician blinded to the results of the ExTcPO2 performed the aorto-iliac arterial stenosis quantification. Imaging characteristics were reviewed to classify aortic, common iliac (CIA), internal iliac (IIA), external iliac (EIA), common femoral (CFA), profunda (PFA) and superficial femoral (SFA) lesions into nil (less than 30%), mild (31-50%), moderate (51-70%) or severe stenosis (greater than 70% stenosis or occlusion). Based on a composite result of the inflow characteristics, a total score was assigned to the degree of inflow compromise at the internal iliac on either limb. Patients with a mild internal iliac stenosis with two tandem proximal CIA or aortic lesions were assigned a higher grade, e.g. if the proximal aortic and CIA lesions were both severe/ occluded, the resultant IIA inflow reduction was graded as severe (Figure 1). In patients

with a mild internal iliac stenosis with a single proximal moderate CIA/ aortic lesion the resultant IIA inflow reduction was graded as moderate. In those with isolated internal iliac artery stenosis, the lesion was graded based on the IIA disease alone. In the presence of multiple tandem lesions upstream from the internal iliac artery, the degree of IIA inflow reduction was upgraded. Thus, a composite internal iliac inflow reduction grade: nil (less than 30%), mild (<50%), moderate (51 - 70%) or severe (greater than 70% stenosis or occlusion): was calculated for each limb. In those patients where only ultrasound results were available, the degree of stenosis mentioned in the report was used if definite information was provided based on the flow characteristics in the internal iliac arteries on direct visualization. Patients who did not have adequate or concomitant imaging were excluded.

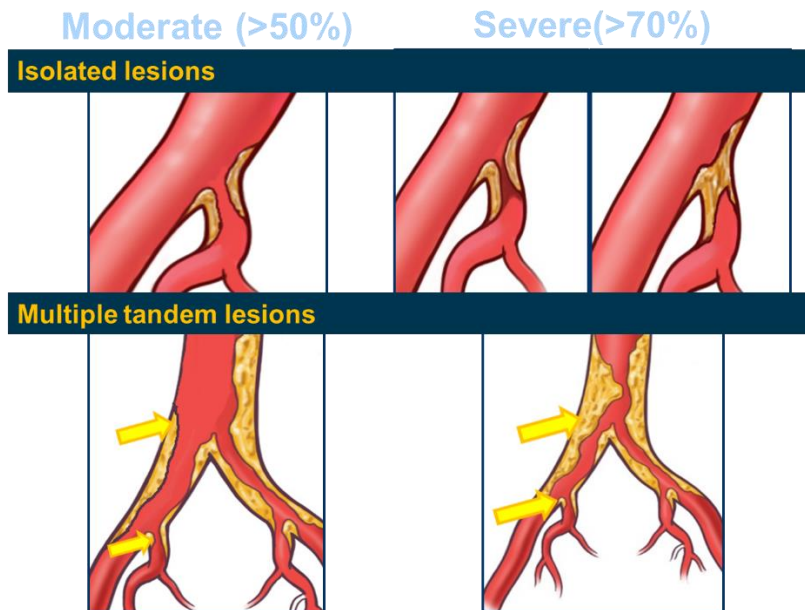


Figure 1: Severe internal iliac artery flow compromise diagnosed based on a composite result of the inflow characteristics on that limb, illustrations depicting severe internal iliac flow compromise. A) Secondary to a high grade ipsilateral ostial lesion (dark blue arrow) B. Secondary to high grade aortic/ common iliac occlusion (dark blue arrows) with moderate ostial disease.

Statistical Analysis

A physician blinded to the results of Ex-TcPO2 performed aorto-iliac arterial stenosis quantification and receiver operating characteristic (ROC) curve analysis was used to determine sensitivity and specificity to diagnose severe inflow reduction ($\geq 70\%$) based upon a diagnostic DROP ≥ 15 mm Hg. Data from patients who underwent revascularization and had a post procedure ExTcPO2 was also analyzed to study its role in outcome assessment. The clinical correlation of the DROP results was noted for the entire study cohort.

Results

One hundred and eleven patients (M: F:79:32, mean age 70, range 18-90 years) with available concomitant imaging (CTA 90, DUS 21) were

included in the study. The Exercise-TcPO2 study was performed for clinical suspicion of vascular claudication in 82 patients (120 limbs) and neuromuscular/ multifactorial symptoms in the remaining 29 patients (42 limbs). The Exercise-TcPO2 study was positive in 56 patients (85 limbs); 45/82 patients with vascular claudication and 11/29 patients with suspected neuromuscular symptoms. ExTcPO2 study confirmed the clinical suspicion of the etiology of the pelvic discomfort being exercise induced reduction of IIA inflow in 81% (91/111) of patients. Arterial imaging included CT angiogram in 90 patients (180limbs) and ultrasound in 21 patients (41 limbs). Patients were classified into mild, moderate or severe depending on the distribution of the stenosis (Table1). Twenty nine patients who did not undergo arterial imaging were excluded from the study.

Degrees of arterial stenosis Site,	Nil (0-30%) no, %	Mild (<50%) no, %	Moderate (50- 70%) no, %	Severe (>70% or occlusion) no, %
Aorta	97 (87)	2(2)	4(4)	8(7)
Common iliac	148(68)	7(3)	22(10)	42(19)
Internal iliac	93(42)	29(13)	26(12)	71(33)
External Iliac	185(85)	7(3)	2(1)	25(11)
Common femoral	208 (95)	6 (3)	2(1)	3(1)
Profunda	199 (91)	5(2)	2(1)	13 (6)
Superficial femoral	173 (79)	6 (3)	16 (7)	24(11)

Table1: Distribution of the stenosis assessed by imaging.

On receiver operating characteristic (ROC) curve analysis DROP ≥ 15 mm Hg had a sensitivity, specificity, PPV, NPV of 56, 80, 70, and 68% respectively for prediction of severe IIA inflow reduction (p value <0.001; OR 1.116, 95% CI 1.057-1.157; C- statistic 0.76, SE=0.03, Figure 3). The

comparative diagnostic accuracy for moderate IIA inflow reduction had a sensitivity, specificity, PPV, NPV of 50, 80, 76, and 55% respectively (p value <0.001; OR 1.107, 95% CI 1.066-1.150; C- statistic 0.73, SE=0.03) is presented in Table. 2.

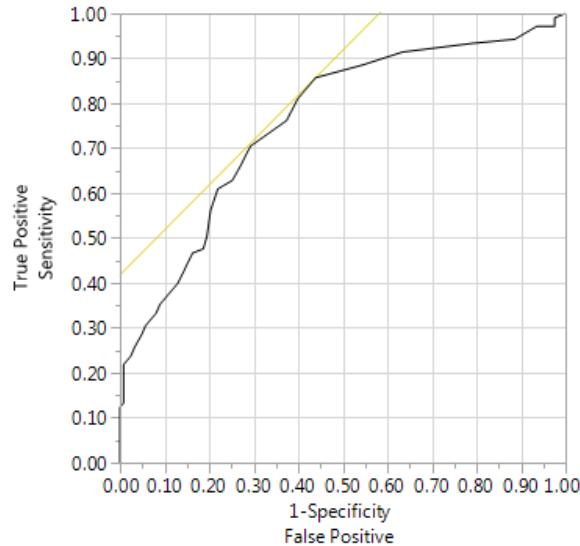


Figure 3: ROC curve demonstrating sensitivity and specificity of ExTcO2 to diagnose severe inflow reduction ($\geq 70\%$) based upon a diagnostic DROP ≥ 15 mm Hg.

Arterial stenosis	Moderate (>50% inflow reduction)	Severe (>70% inflow reduction)
Cutoff point, mm Hg	-15	-15
C-Statistic[95% CI], SE	0.73, [1.066-1.150], 0.03	0.76 [1.057-1.157] , 0.03
Sensitivity % [95% CI]	50 [41.0,59.0]	56 [46.2,65.9]
Specificity % [95% CI]	80 [70.8,87.3]	80 [71.5,86.4]
PPV % [95% CI]	76 [65.6,84.8]	70 [59.3,79.7]
NPV % [95% CI]	55 [47.0,63.8]	68 [59.8,75.6]

Table 2: Diagnostic accuracy of DROP to detect moderate IIA inflow reduction.

In 27 patients (34 limbs) on imaging studies significant stenosis limiting IIA inflow was noted but ExTcPO2 was negative. The study was limited by severe dyspnea in 2 and lower extremity claudication in the calf/ thigh in 9 that preceded the onset of buttock claudication, symptoms that limited

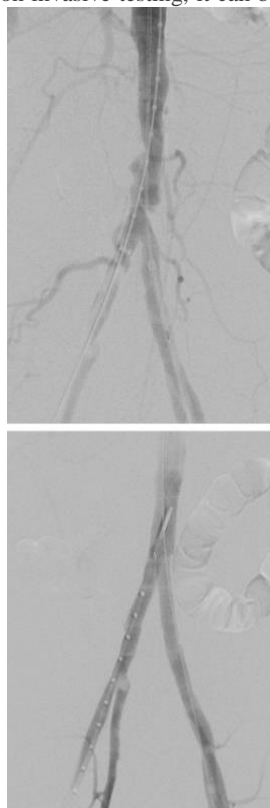
the walking distance and led to early termination of the study before buttock claudication could develop. Subgroup analysis excluding those with ultrasound imaging alone or those patients unable to complete the protocol revealed an improvement in all results (Table 3).

	CTA (excluding US n=21)		Protocol completed* (excluding n=24)	
	>50%	>70%	>50%	>70%
Sensitivity	80	69	64	78
Specificity	68	80	91	88
PPV %	73	80	75	87
NPV %	75	70	69	71
C-Statistic	0.75	0.78	0.81	0.82

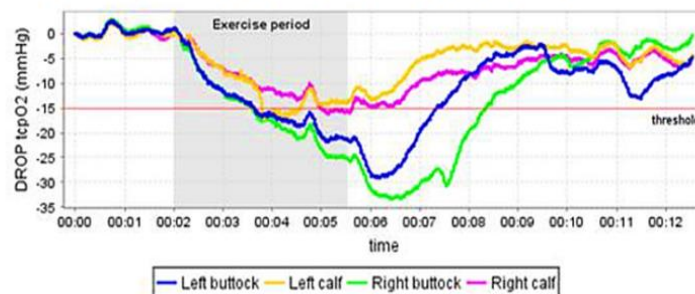
Table 3: Subgroup analysis

Aorto-iliac arterial reconstruction to treat severe IIA flow compromise was performed in 16 patients. Revascularization was Direct Antegrade in 12 patients (IIA PTA /stenting – 4, aorto-ilac stenting /femoral endarterectomy – 9), Direct Retrograde (aorto-bifemoral bypass) in 1 and Indirect via increased collateral flow (profundoplasty) in 3. Post-operatively symptom relief was noted in 15/16 patients and objectively demonstrated on ExTcPo2 in 6/7. This was useful for its ability to evaluate comparative severity of calf vs buttock claudication (Figure 4). Similar to standard non invasive testing, it can be used post-operatively

to confirm adequacy of aorto-iliac revascularization (Figure 5). One patient did not improve clinically, or on ExTcPO2 following Indirect retrograde revascularization. This patient underwent profundoplasty for disabling thigh and buttock claudication (imaging had revealed long segment occlusion of the IIA with poor distal reformation and occlusion of the profunda). Post procedure, he had improvement of the thigh claudication but no improvement in the buttock claudication which could be explained by the poor improvement in collateral flow secondary to the long segment IIA occlusion.



A. Pre-intervention angio and ExTcPO2 DROP study



B. Post-intervention angio and ExTcPO2 DROP study

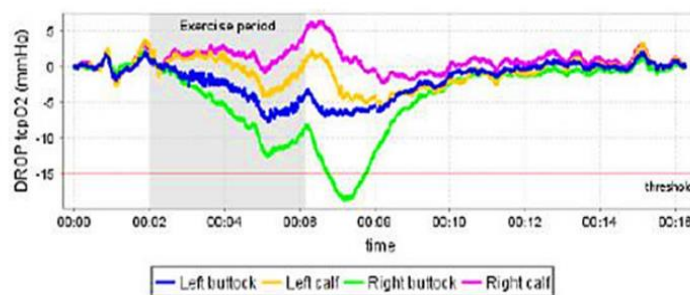


Figure 4: Results of vascular laboratory investigations. A: Pre-intervention angiogram and Extc2 DROP study revealing distal aortic and bilateral common iliac high grade occlusive disease, blue and green curves demonstrating DROP more than -15; significantly worse B/L buttock claudication shown by blue and green curves compared to bilateral calves in pink and yellow. B: Post-intervention angiogram and Extc2 DROP study: a direct antegrade revascularization (aortic and bilateral common iliac stenting) performed; all curves improved with mild residual right buttock ischemia secondary to untreated right internal iliac ostial stenosis.

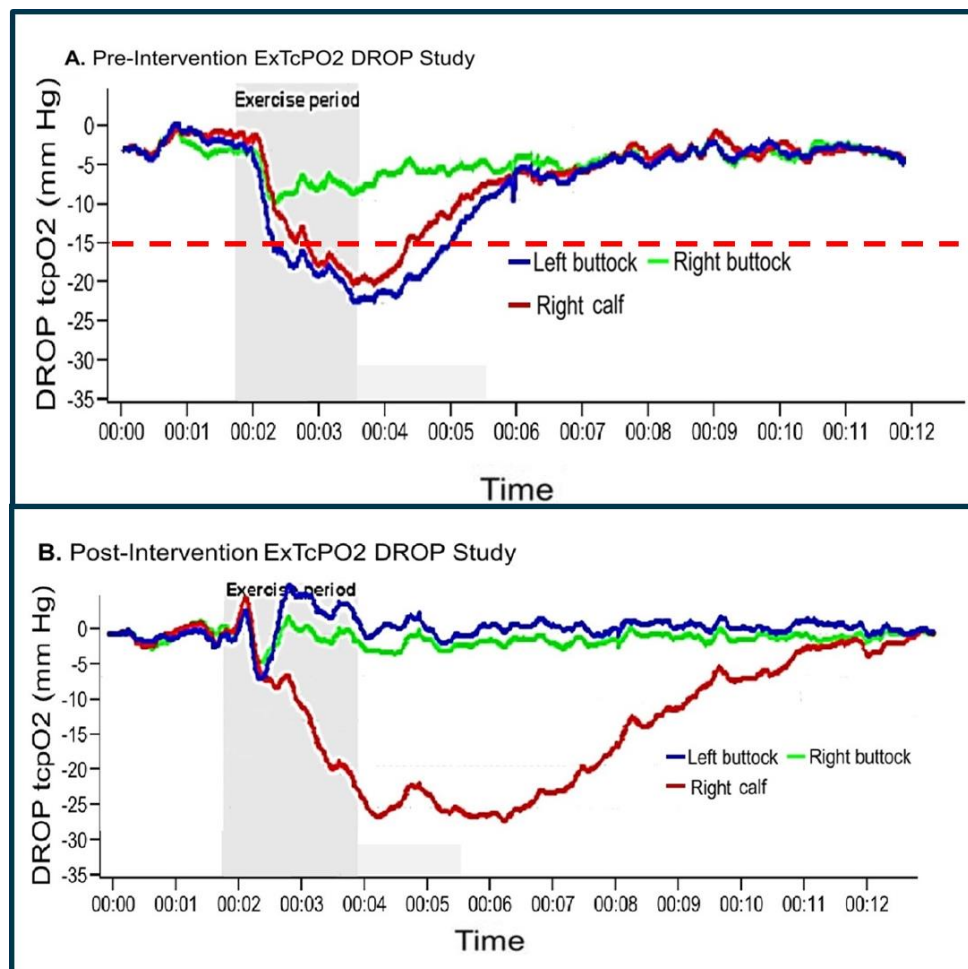


Figure 5: A. Pre-intervention ExTcO₂ DROP study in a 71 year old male with left buttock and right calf claudication shows a positive DROP in the left buttock seen in blue and the right calf seen in red. B. Post-intervention ExTcO₂ study following left common iliac stenting and unsuccessful right popliteal intervention shows normalization of the buttock tracing but persistent DROP in the calf tracing.

Discussion

The prevalence of proximal vascular claudication or buttock claudication has come to light in the post EVAR era when internal iliac artery sacrifice was performed frequently. Similar symptoms can be caused by various orthopaedic disorders and a combination of these frequently exist in elderly patients. Clinical differentiation of buttock claudication from pseudo-claudication (neuromuscular etiology) is often challenging. Patients are typically older and present with atypical lower back, hip, buttock, or thigh pain arising from common iliac and/or internal iliac flow limiting lesions. Many patients present with atypical symptoms not typical of claudication or with concomitant neuromuscular and orthopedic conditions that may also give rise to pain (pseudo-claudication) indistinguishable from that produced by arterial disease [1]. It is usually asymptomatic, as worsening in claudication may be masked by a compensatory decline in functional performance in spite of disease progression [7]. Evaluation of proximal claudication is challenging. Standard noninvasive vascular tests measure axial lower extremity but not direct internal iliac or abdominal-pelvic collateral flow. Visualization of the internal iliac arteries using duplex may be difficult secondary to its location, and inflow abnormalities cannot be diagnosed non-invasively using standard tests like ankle-brachial index (ABI) with exercise that are designed to test axial blood flow. Transcutaneous oxygen tension measurement reflects the metabolic state of target tissues and exercise transcutaneous oxygen pressure (Exercise-TcPO₂) has previously been

reported to be useful in the diagnosis of proximal claudication due to PAD [6]. This study demonstrates the utility of ExTcO₂ in diagnosing the role of internal iliac artery flow compromise as the significant contributing cause of proximal walking induced pain, even while multiple potential other etiologies are present.

Patients often present with concomitant lower limb claudication and conventional non-invasive testing with ABI/ exercise ABI/Toe pressure/ Pulse volume recordings remain first line. Non-invasive testing using transcutaneous oxygen tension measurements in the lower limb has a better sensitivity/specificity in diagnosing severe flow limiting lesions, its role in diagnosing moderate or mild lesions is thought to be poor. This may not be a limitation in the internal iliac bed; as intervention is most often offered only for those with critical lesions. Also, the gluteal skin and underlying muscle beds have a common supply from the internal iliac and the calculation of the DROP index helps in cancelling out the effect of an exercise induced drop in skin TcO₂ purely due to shunting of blood by dilatation of intramuscular vessels similar to what is seen in the pedal circulation.

In such patients with both proximal (buttock) and distal (axial) vascular compromise the use of a 5-electrode system also allows for 4 different sites can be evaluated in the same time. This also allows for calculation of a proximal and distal DROP; those with a proximal DROP that is higher than the distal are more likely to have an internal iliac artery flow limiting proximal lesion [8]. As demonstrated by our study, Ex-TcPO₂

with calculation of a DROP index allows for functional assessment of the internal iliac artery and distal lower extremity circulation during walking and helps determine the area with the greater arterial inflow compromise that is responsible for limiting ambulation, helping guide the location and extent of revascularization that is most likely to provide symptom relief.

In the final analysis identification of internal iliac artery flow compromise with ExTcPo2 is especially relevant for three reasons: first, it allows for the assessment of blood flow during exercise; which is a more accurate assessment of the underlying physiology as during exercise is when symptoms occur, helps determine the maximal walking distance and reveals other causes of exercise limitation. This is particularly useful in patients with a combination of etiologies that limit ambulation; Ex-TcPo2 helps determine the more severe etiology thereby guiding evaluation and treatment. Second, it also allows for assessment of the arterial physiology in those with calcified or non-compressible vessels (diabetes, renal insufficiency, advanced age) where ABPI may be falsely elevated. Ex-TcPo2 is accurate to detect IIA flow compromise $\geq 70\%$ that is similar to ultrasound to detect aorto-iliac stenoses. [9, 10] We thus included the imaging results of those with ultrasound imaging alone as this is a more realistic clinical scenario in this patient cohort. Third, the degree of DROP in each area helps guide the site and extent of vascular intervention that the patient may benefit from.

Ex-TcPO2 has been validated against angiography in two previous studies [5, 11] and CT-angiogram in one study [8] with a good sensitivity/specificity of this method to detect proximal arterial stenosis. This is the first report of validation of this technique in the United States. Abraham et.al reported on the utility of Ex-TcPo2 with a cutoff point of -15 mm Hg DROP demonstrating a 79%/86% sensitivity/specificity in the diagnosis of internal iliac flow compromise; but they did not grade the degree or laterality of the internal iliac stenosis [5]. The study by Koch et. al included 34 patients with suspected claudication and noted that exercise-TcPo2 using a proximal minimal DROP value ≤ -15 mm Hg or a distal minimal DROP value ≤ -16 mm Hg is accurate to diagnose arterial stenosis especially stenosis $\geq 60\%$ on the lower limbs. However this study, stenosis was assessed at a single level (aortic/ CIA/IIA) was used for analysis and did not analyze the effect of a combined aortic/ common iliac lesion. We used an algorithm to account for tandem lesions and tried to correlate the potential physiologic significance of lesions by correlating it to ex-TcPo2. Koch et.al reported a specificity of 76% for a high grade ($>70\%$) stenosis which is similar to our results. Our sensitivity is lower, this may be because the study was negative in those patients who developed early calf/ thigh claudication or dyspnea that limited the walking distance and led to early termination of the study. The high specificity of the study is similar to that reported by other authors and supports the utility of Ex-TcPO2 in diagnosing proximal claudication.

We demonstrate that ExTCo2 improves after treatment and is useful in assessing outcome, follow up and surveillance following these procedures. The importance of preserving the pelvic circulation to prevent gluteal claudication is well recognized [12]. Both open and endovascular intervention may be necessary for symptom relief; with a good 5 year patency and freedom from buttock claudication (both around 80%) [12-15]. In addition, an improvement in the ExTCo2 following intervention in a patient with persistent symptoms of hip pain should prompt more aggressive evaluation and management of non-vascular etiologies.

Our study has some limitations, the overall numbers remain small and we have not analyzed the effect of the pretest probability based on the nature of symptoms and its correlation with internal iliac disease based on imaging. It is time consuming, automation is essential, current software is proprietary. However, this does not affect its obvious utility in diagnosis or follow up as those without a higher pretest probability are not likely to be advised this test due to its niche utility. Also, a drift correction to

correct a potential drift of the O2 pressure measurement with time at each electrode was not used in all patients.

Conclusion

Exercise transcutaneous oximetry can reliably diagnose significant IIA inflow stenosis. It is a simple, non-invasive and can serve as a valuable screening tool to differentiate buttock claudication from other neuromuscular causes of low back, buttock and hip discomfort as well as the ability to evaluate comparative severity of calf vs buttock claudication. Similar to standard noninvasive testing, it can be used post-operatively to confirm adequacy of aorto-iliac revascularization and for surveillance.

Author contributions

IS, DL: Data collection, analysis, statistics, drafting manuscript

WH: PW: Analysis, statistics, drafting manuscript

GM, PA, MK: Concept, data collection, analysis, statistics, drafting manuscript, final approval

References

1. Kauppila LI. (2009). Atherosclerosis and disc degeneration/low-back pain--a systematic review. *European journal of vascular and endovascular surgery : the official journal of the European Society for Vascular Surgery.* 37(6):661-670.
2. Rooke TW, Hirsch AT, Misra S, Sidawy AN, Beckman JA, Findeiss L, et al. (2013). Management of patients with peripheral artery disease (compilation of 2005 and 2011 ACCF/AHA Guideline Recommendations): a report of the American College of Cardiology Foundation/American Heart Association Task Force on Practice Guidelines. *Journal of the American College of Cardiology.* 61(14):1555-1570.
3. Sugano N, Inoue Y, Iwai T. (2003). Evaluation of buttock claudication with hypogastric artery stump pressure measurement and near infrared spectroscopy after abdominal aortic aneurysm repair. *European journal of vascular and endovascular surgery : the official journal of the European Society for Vascular Surgery.* 26(1):45-51.
4. Mahe G, Leftheriotis G, Picquet J, Jaquinandi V, Saumet JL, Abraham P. (2009). A normal penile pressure cannot rule out the presence of lesions on the arteries supplying the hypogastric circulation in patients with arterial claudication. *Vascular medicine (London, England).* 14(4):331-338.
5. Abraham P, Picquet J, Vielle B, Sigaudou-Roussel D, Paisant-Thouveny F, Enon B, et al. (2003). Transcutaneous oxygen pressure measurements on the buttocks during exercise to detect proximal arterial ischemia: comparison with arteriography. *Circulation.* 107(14):1896-1900.
6. Mahe G, Kalra M, Abraham P, Liedl DA, Wennberg PW. (2015). Application of exercise transcutaneous oxygen pressure measurements for detection of proximal lower extremity arterial disease: a case report. *Vascular medicine (London, England).* 20(3):251-255.
7. McDermott MM, Liu K, Greenland P, Guralnik JM, Criqui MH, Chan C, et al. (2004). Functional decline in peripheral arterial disease: associations with the ankle brachial index and leg symptoms. *Jama.* 292(4):453-461.
8. Koch C, Chauve E, Chaudru S, Le Faucheur A, Jaquinandi V, Mahé G. (2016). Exercise transcutaneous oxygen pressure measurement has good sensitivity and specificity to detect lower extremity arterial stenosis assessed by computed tomography angiography. *Medicine.* 95(36).

9. de Smet AA, Ermers EJ, Kitslaar PJ. (1996). Duplex velocity characteristics of aortoiliac stenoses. *J Vasc Surg.* 23(4):628-636.
10. Ouedraogo N, Barbeau C, Legrand M, Marchand J, Leftheriotis G, Abraham P. (2013). "Routine" arterial echo-Doppler is not sufficient to exclude an arterial origin of exercise-induced proximal lower limb pain. *International journal of cardiology.* 167(3):1053-1054.
11. Abraham P, Picquet J, Bouye P, L'Hoste P, Enon B, Vielle B, et al. (2005). Transcutaneous oxygen pressure measurements (tcpO2) at ankle during exercise in arterial claudication. *Int Angiol.* 24(1):80-88.
12. Rana MA, Kalra M, Oderich GS, de Grandis E, Glociczki P, Duncan AA, et al. (2014). Outcomes of open and endovascular repair for ruptured and nonruptured internal iliac artery aneurysms. *J Vasc Surg.* 59(3):634-644.
13. Klein AJ, Feldman DN, Aronow HD, Gray BH, Gupta K, Gigliotti OS, et al. (2014). SCAI expert consensus statement for aorto-iliac arterial intervention appropriate use. *Catheterization and cardiovascular interventions : official journal of the Society for Cardiac Angiography & Interventions.* 84(4):520-528.
14. Mahe G, Kaladji A, Le Faucheur A, Jaquinandi V. (2015). Internal Iliac Artery Stenosis: Diagnosis and How to Manage it in 2015. *Frontiers in cardiovascular medicine.* 2:33.
15. Paumier A, Abraham P, Mahe G, Maugin E, Enon B, Leftheriotis G, et al. (2010). Functional outcome of hypogastric revascularisation for prevention of buttock claudication in patients with peripheral artery occlusive disease. *European journal of vascular and endovascular surgery : the official journal of the European Society for Vascular Surgery.* 39(3):323-329.



This work is licensed under Creative Commons Attribution 4.0 License

To Submit Your Article Click Here:

Submit Manuscript

DOI: [10.31579/2768-2757/036](https://doi.org/10.31579/2768-2757/036)

Ready to submit your research? Choose Auctores and benefit from:

- fast, convenient online submission
- rigorous peer review by experienced research in your field
- rapid publication on acceptance
- authors retain copyrights
- unique DOI for all articles
- immediate, unrestricted online access

At Auctores, research is always in progress.

Learn more <https://auctoresonline.org/journals/journal-of-clinical-surgery-and-research>