

A Case Report: Electrophysiological Findings in Degenerative Myopia

Bilge Başçiftçi ^{1*}, Mualla Şahin Hamurcu ²

^{1,2} Department of Ophthalmology, University of Health Sciences, Ankara City Hospital, Ankara, Turkey

*Corresponding Author: Bilge Başçiftçi, Department of Ophthalmology, University of Health Sciences, Ankara City Hospital, Ankara, Turkey.

Received date: January 10, 2022; Accepted date: January 17, 2022; Published date: January 28, 2022

Citation: Bilge Başçiftçi, Mualla Şahin Hamurcu (2022) A Case Report: Electrophysiological Findings in Degenerative Myopia. *J. Archives of Medical Case Reports and Case Study*, 5(3); DOI:10.31579/2692-9392/105

Copyright: © 2022 Bilge Başçiftçi, This is an open access article distributed under the Creative Commons Attribution License, which permits unrestricted use, distribution, and reproduction in any medium, provided the original work is properly cited.

Abstract

We report electrophysiological findings in a patient that has degenerative myopia. The visual acuity of a 48 years old male patient was counting fingers from 0.1 with refraction (-11.00, -1.00 x115) in the right eye and 0.6 with refraction (-5.00, -1.50 x35) in the left eye. Bilateral anterior segment examination was normal however; on the fundus examination, there were atrophic scar area in the macula and pigmented degenerative areas in the inferior on the right, while there were chorioretinal atrophy and degenerative areas in the peripheric retina on the left. Normal latency response was obtained in VEP. In the right eye, a low amplitude and long latency response was obtained with the 120' pattern, but no response was obtained with the other patterns. In the left eye, there was a response to patterns shrinking to 15', the p100 wave was minimally low for age, and its latency was within normal limits. 7' pattern could not be answered. With ERG, bilateral rod b wave responses were subnormal for age, and cone b wave responses were low. Oscillatory responses were obtained bilaterally low.

Key words: myopia; degenerative myopia; VEP; ERG

1. INTRODUCTION

Myopia as a refractive disorder is quite common in many parts of the world, with a prevalence of approximately 80% [1,2]. Its frequency is increasing fast with growing screen exposure and close fixation, all over the world. High myopia is one of the important causes of vision loss, especially in the young population and it is described as refractive error of minimum -6.00 D spherical or an axial length which is greater than 26.5 mm [3,4]. Myopia is a refractive problem that can be easily resolved with optical correction; however degenerative myopia is considered as a disease in which changes occur in the entire eye, that may be concluded in damaged retinal activity and conclusively modify the visual performance. [5,6,7]. Degenerative myopia or pathological myopia is characterized by high axial myopia accompanied by characteristic pathological changes such as chorioretinal atrophy which can be diffuse or patchy, posterior staphyloma, lacquer cracks. Also, choroidal neovascular membrane, Fuchs spots, macular hole and foveoschisis may also evolve [8,9]. These pathologic findings usually bring about accelerated vision loss [10]. Visual evoked potential (VEP) and electroretinogram (ERG) are important diagnostic tools that assist the clinician in the evaluation of visual functions. With this case report, the effect of degenerative myopia on optic nerve and retinal functions was emphasized with visual evoked potential (VEP) and flash electroretinogram (ERG).

2. METHODS AND MATERIALS:

In this case report; the best corrected visual acuity with Snellen chart, anterior and posterior segment examination with slit lamp, visual evoked potential (VEP) and flash electroretinogram (ERG) examinations were examined.

3. CASE REPORT:

The visual acuity of a 48 years old male patient was counting fingers from 0.1 with refraction (-11.00, -1.00 x115) in the right eye and 0.6 with refraction (-5.00, -1.50 x35) in the left eye. Bilateral anterior segment examination was found normal in the slit lamp examination. On the fundus examination, there were atrophic scar area in the macula and pigmented degenerative areas in the inferior on the right eye, while there were chorioretinal atrophy and degenerative areas in the peripheric retina on the left eye.

Normal latency response was obtained in VEP. In the right eye, a low amplitude and long latency response was obtained with the 120' pattern, but no response was obtained with the other patterns. In the left eye; there was a response to patterns shrinking to 15', where the p100 wave was minimally low for age, and its latency was within normal limits. 7' pattern could not be answered. Bilateral p wave latencies were symmetrical and within normal limits, but p amplitude was low on the right

With ERG, bilateral rod b wave responses were subnormal for age and cone b wave responses were low. Oscillatory responses were obtained bilaterally low.

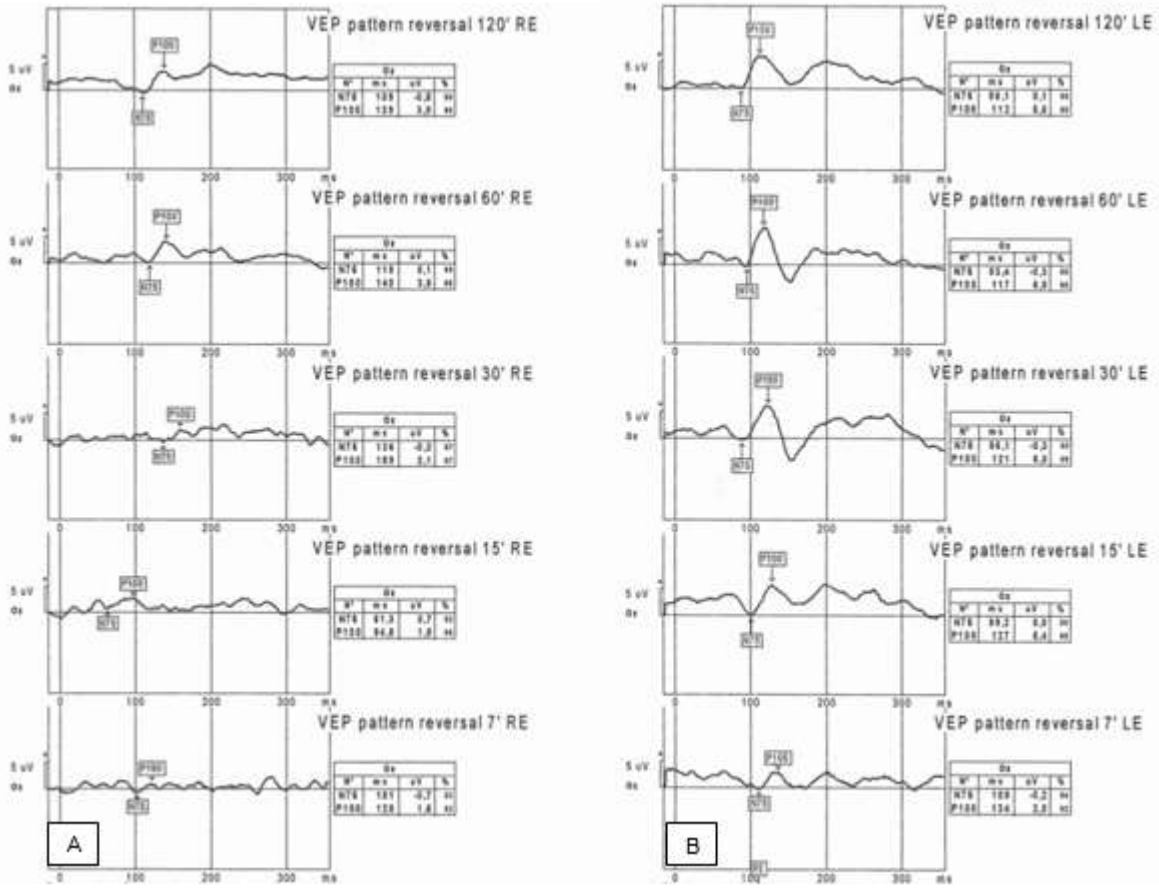


Figure 1A: Pattern VEP of the right eye, **B.** Pattern VEP of the left eye

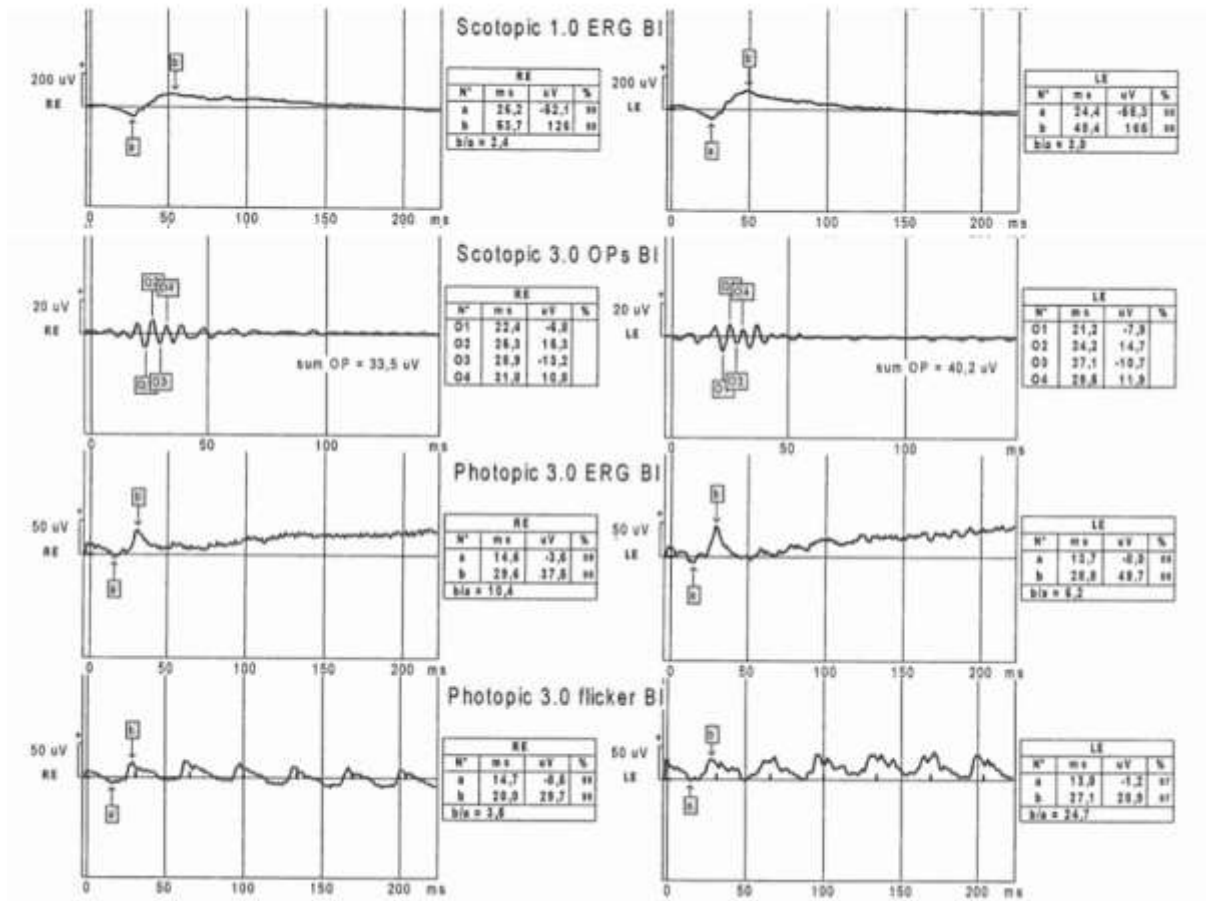


Figure 2: ERG of the right and left eye

4. DISCUSSION:

EP is a sensitive test used to evaluate optic nerve function and is a helpful test for the clinician in the diagnosis of optic nerve diseases such as demyelinating diseases, optic neuritis and optic neuropathy. It is also used in the evaluation of visual function by transmitting the ganglion cell response generated by flash or pattern stimulation to the occipital cortex. While VEP wave responses are generally not affected in refractive myopia; in patients with degenerative myopia, there may be a decrease in the amplitude of the positive wave and a prolongation of the latency period in VEP due to the involvement of optic nerve and ganglion cells [11,12,13,14]. In our case, with the decrease in visual acuity; in VEP, the latency time was normal; in pattern VEP, the amplitude of the p100 wave obtained with a 120' pattern was low and the latency period was long in the right eye; no response was obtained with other patterns. In the left eye, there was a response to patterns that decreased by 15', the amplitude of the p100 wave was minimally low for age, and the latency period was within normal limits. 7' pattern could not be answered.

ERG is a documentation of a common electrical response produced by neural and non-neuronal cells within the retina. In patients with retinal degeneration and affected retinal nerve fiber layer, ERG responses are also impaired [14]. In our case, too; with ERG, bilateral rod b wave responses were subnormal for age and cone b wave responses were low. Oscillatory responses were obtained bilaterally low.

5. CONCLUSION

Visual acuity as well as visual quality and visual function are affected in degenerative myopia. Depending on the degeneration, VEP responses starting from retinal ganglion cells and ERG wave responses showing retinal functions are also affected.

6. REFERENCES:

1. Lin LL, Shin YF, Tsoi CB. Epidemiologic study of ocular refraction among school children in Taiwan in 1995. *Invest Ophthalmol Vis Sci* 1999;76:275–281.
2. Wu HM, Seet B, Yap EP. Does education explain ethnic differences in myopia prevalence? A population based study of young adult males in Singapore. *Invest Ophthalmol Vis Sci* 2001;78:234–239.
3. Morgan IG, Ohno-Matsui K, Saw SM. Myopia. *Lancet*. 2012 May 5;379(9827):1739-1748.
4. Miller DG, Singerman LJ. Natural history of choroidal neovascularization in high myopia. *Curr Opin Ophthalmol*. 2001 Jun;12(3):222-224.
5. Gozum N, Cakir M, Sezen F. Relationship between retinal lesions and axial length, age and sex in high myopia. *Eur J Ophthalmol* 1997;7:277–282.

6. Chui TYP, Yap MKH, chan HHL. Retinal stretching limited peripheral visual acuity in myopia. *Vis Res* 2005(5);593–595.
7. Subbaram MV, Bullimore MA. Visual acuity and the accuracy of the accommodative response. *Ophthal Physiol Optics* 2002;22(4):312–318.
8. Grossniklaus HE, Green WR. Pathologic findings in pathologic myopia. *Retina*. 1992;12(2):127-133.
9. Ohno-Matsui K, Kawasaki R, Jonas JB, Cheung CM, Saw SM, Verhoeven VJ, Klaver CC, Moriyama M, Shinohara K, Kawasaki Y, Yamazaki M, Meuer S, Ishibashi T, Yasuda M, Yamashita H, Sugano A, Wang JJ, Mitchell P, Wong TY; META-analysis for Pathologic Myopia (META-PM) Study Group. International photographic classification and grading system for myopic maculopathy. *Am J Ophthalmol*. 2015 May;159(5):877-883.e7.
10. Saw SM. How blinding is pathological myopia? *Br J Ophthalmol*. 2006 May;90(5):525-526.
11. Hamurcu M, Çelik A, M. Sinan Sarıcaoğlu MS, Bulut AK. Electrophysiologic evaluation of amblyopia. *Eye Care Vis*, 2017 Volume 1(2): 1-4, doi: 10.15761/ECV.1000112.
12. Hamilton R, Bach M, Heinrich SP, Hoffmann MB, Odom JV, McCulloch DL, Thompson DA. VEP estimation of visual acuity: a systematic review. *Doc Ophthalmol*. 2021 Feb;142(1):25-74.
13. Hamilton R, Bach M, Heinrich SP, Hoffmann MB, Odom JV, McCulloch DL, Thompson DA. ISCEV extended protocol for VEP methods of estimation of visual acuity. *Doc Ophthalmol*. 2021 Feb;142(1):17-24.
14. Kader MA. Electrophysiological study of myopia. *Saudi J Ophthalmol*. 2012 Jan;26(1):91-99.



This work is licensed under Creative Commons Attribution 4.0 License

To Submit Your Article Click Here: [Submit Manuscript](#)

DOI: [10.31579/2692-9392/105](https://doi.org/10.31579/2692-9392/105)

Ready to submit your research? Choose Auctores and benefit from:

- ❖ fast, convenient online submission
- ❖ rigorous peer review by experienced research in your field
- ❖ rapid publication on acceptance
- ❖ authors retain copyrights
- ❖ unique DOI for all articles
- ❖ immediate, unrestricted online access

At Auctores, research is always in progress.

Learn more www.auctoresonline.org/journals/archives-of-medical-case-reports-and-case-study