

# A Huge Benign Phyllodes Tumor in 37 Year Old / Middle Aged Woman: A Case Report

Pranav Kumar Dave<sup>1\*</sup>, Vivek Gupta<sup>1</sup>, R Mishra<sup>1</sup>, Manish Swarnkar<sup>2</sup>, V Agarwal<sup>3</sup>, M Jain<sup>4</sup>, M Bapat<sup>5</sup>, Khendelwal<sup>6</sup>, P Gupta<sup>7</sup>, P Rajpalli<sup>7</sup>, R Nichhlani<sup>8</sup>

<sup>1</sup>Deptt. Of Radiology, L N Medical College and J K Hospital, Kolar Road, Bhopal-MP, India.

<sup>2</sup>Surgery, L N Medical College and J K Hospital, Kolar Road, Bhopal-MP, India.

<sup>3</sup>Path. L N Medical College and J K Hospital, Kolar Road, Bhopal-MP, India.

<sup>4</sup>HOD Radiology, L N Medical College and J K Hospital, Kolar Road, Bhopal-MP, India.

<sup>5</sup>L N Medical College and J K Hospital, Kolar Road, Bhopal-MP, India.

<sup>6</sup>Radiology, L N Medical College and J K Hospital, Kolar Road, Bhopal-MP, India.

<sup>7</sup>Resident,-Department of Radio diagnosis, L N Medical College & J K Hospital, Bhopal

<sup>8</sup>Chirayu Med College Bhopal, MP, India.

**\*Corresponding Author:** Dr Pranav K Dave, Dept. of Radiology, L N Medical College and J K Hospital, Kolar Road, Bhopal-MP, India.

**Received date: October 25, 2021; Accepted date: November 15, 2021; Published date: November 22, 2021**

**Citation:** Pranav Kumar Dave, Vivek Gupta, R Mishra, Manish Swarnkar, V Agarwal, M Jain, M Bapat, K Khendelwal, P Gupta, P Rajpalli and R Nichhlani (2021). A Huge Benign Phyllodes Tumor in 37 Year Old / Middle Aged Woman, A Case Report. *Clinical Research Notes*. 2(3). DOI: 10.31579/2690-8816/042

**Copyright:** © 2021 Pranav Kumar Dave. This is an open access article distributed under the Creative Commons Attribution License, which permits unrestricted use, distribution, and reproduction in any medium, provided the original work is properly cited.

## Abstract

Phyllodes tumor is uncommon benign tumor of breast with a risk of malignant transformation. Malignant phylloides tumors originate from the connective tissue of the breast therefore these tumors are sarcomas on histology. A 37-year-old married woman presented with painless slowly progressive enlargement of right breast for two years duration. On physical examination confirmed the presence of a large size lobulated well-defined mass lesion occupying in UIQ, UOQ & LOQ of right breast. Ultrasonography of breast and Mammography revealed mass lesion. FNAC from the lesion & subsequently histopathology confirmed the diagnosis of benign phyllodes tumor of breast.

Overlying skin was normal. There was no discharge from the nipple. No lymph nodes were palpable in right axilla. Left breast and left axilla were unremarkable. Her systemic examination was normal. The present case report describes a case of benign phyllodes tumor of breast in a 37-year-old female and its clinical, ultrasonographic, cytological and histopathological correlation.

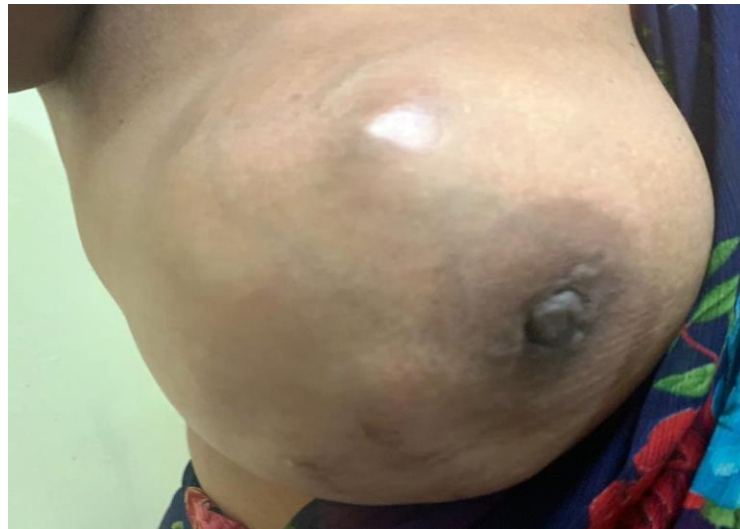**Keywords:** phyllodes tumor; malignancy breast; primary sarcoma breast; cystic lymphangioma cl; cystic hygroma ch; macrocystic lymphatic malformation abdominal wall

## Introduction

### Case Presentation:

A middle-aged woman presented with complaints of progressive enlargement of right breast of 2 years duration, not associated with pain. No H/O- oral contraceptive intake with normal menstrual cycle. No positive family history for breast neoplasms. Had history of normal

vaginal delivery of 2 children. On local examination, enlargement of right breast as compared to left breast with bulge on contour. Nipple areola was normal. Skin appeared normal with livid discoloration. Large sized approximately 12 x 8 cm, mass lesion felt on palpation involving all quadrants of right breast mainly upper outer quadrant. Lesion was mobile and non-tender. No palpable lymph nodes in axilla. Systemic examination was insignificant.

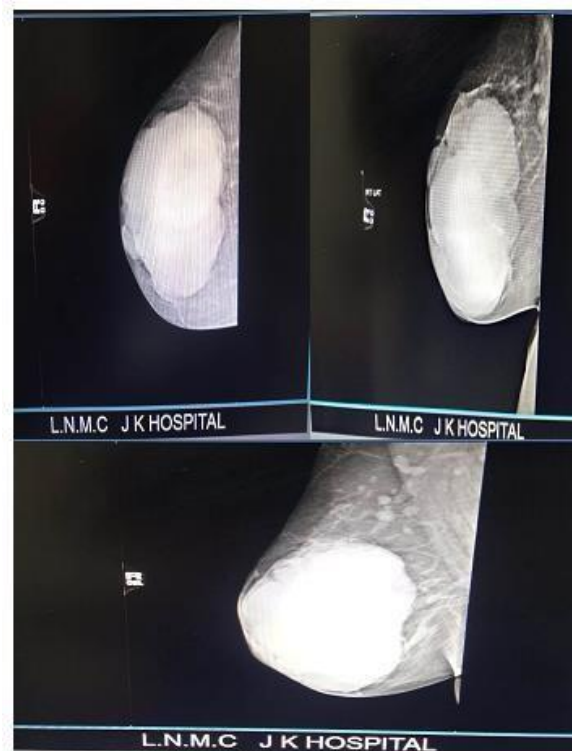

**Figure 1:** clinical image showing enlargement and disfigurement of right breast.

**Imaging findings:**

**Mammographic findings:**

Well defined large sized encapsulated, lobulated high density mass lesion with well-defined margins occupying right breast. A radiolucent halo is seen around the lesion.No evidence of pleomorphic microcalcifications seen.

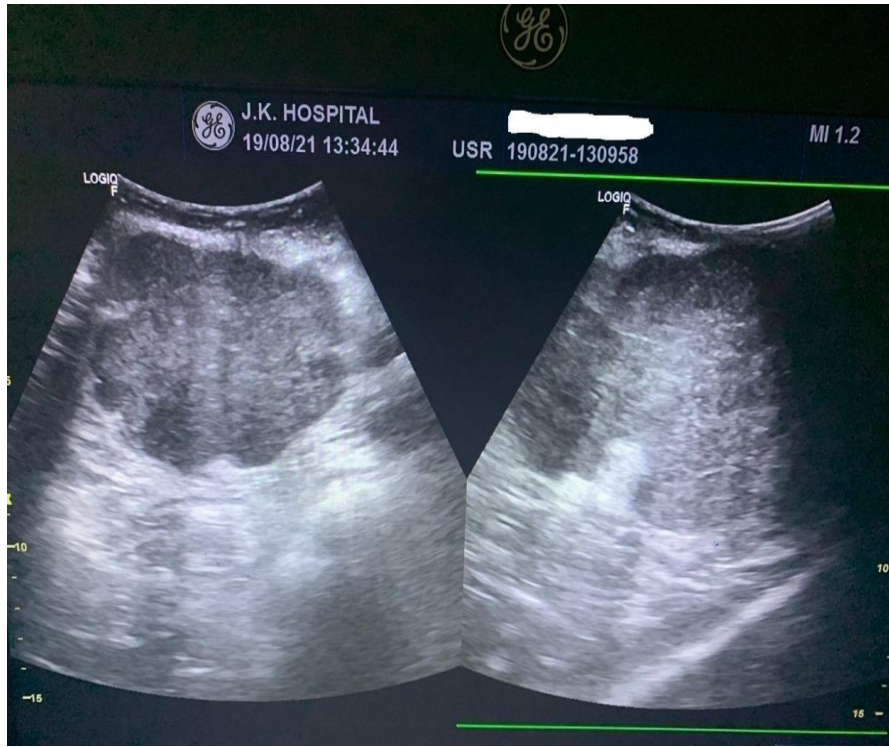

**Figure 2, 3, 4:** mammographic CC, LAT & OBL projections showing well defined, encapsulated, lobulated high density lesion in right breast.

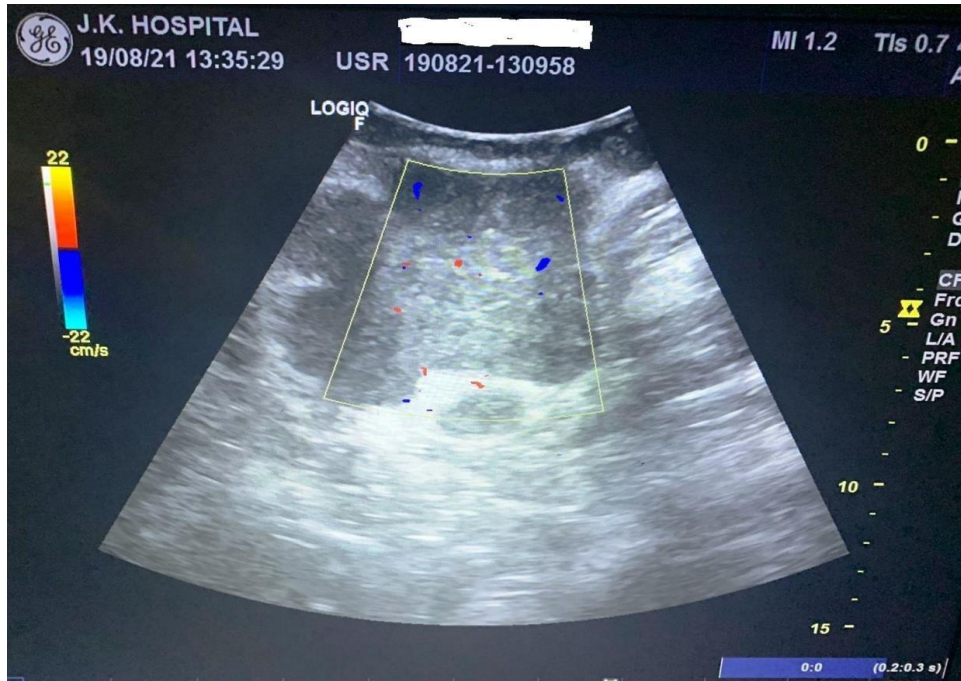**Breast Ultrasonographic findings:**

Well defined heterogenous hypoechoic mass lesion with clefts occupying entire breast mainly upper outer and central quadrant with posterior

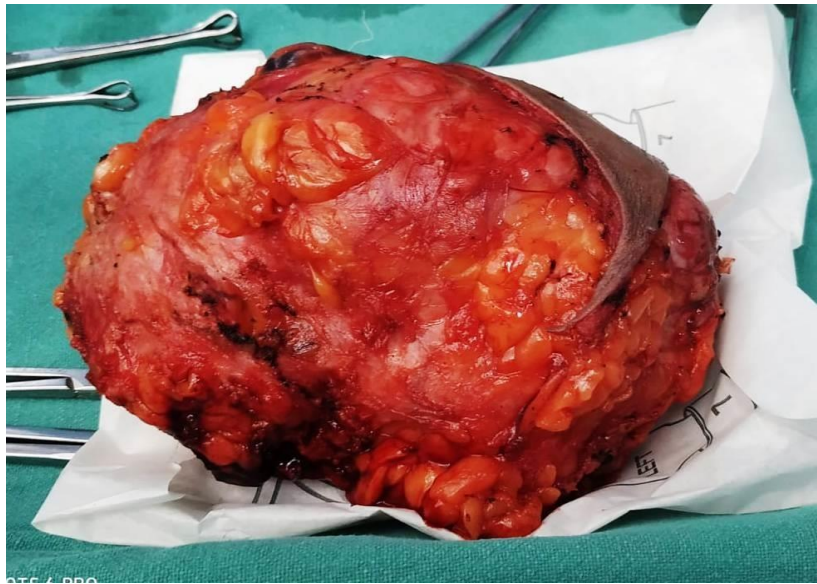
acoustic shadow.No evidence of internal vascularity seen.No significant lymphnodes seen in right axilla. Left breast was normal.



**Figure 5:** USG findings shows well defined heterogenous, hypoechoic mass lesion with clefts and posterior acoustic shadows.



**Figure 6:** USG DOPPLER study showing minimal internal vascularity.



**Figure 7:** clinical specimen after surgical removal.

### Histopathological finding:

Benign Phyllodes tumor grade I with low rate of local recurrence.

### Discussion:

Phyllodes tumour is a rare fibroepithelial neoplasm. 1:6300 examinations; 0.3-1.5 % of all breast tumors [1, 2], 3% of all fibroadenomas. Most of the tumours occur in females of a median age [2,3,4]. 5<sup>th</sup> -6<sup>th</sup> decade, mean age of 45 years [5], occasionally in women < 20 years of age) with higher grade tumours more common in the elderly .although it is disease of females, few cases are reported in men also [6,7]. The term "phyllodes" derived from the Greek word "phyllon" means leaf and refers to papillary projections seen on microscopic examination .Although phyllodes tumour and fibroadenoma have similar radiologic and histopathologic features, they have to be distinguished, on the basis of their different clinical course [8], as phyllodes tends to have higher density [9]. Large size and rapid growth favours the diagnosis of phyllodes [10]. There is 10 times higher chances of recurrence if tumor size is more than 10cm [11].

Approximately 20-30% of phyllodes tumours are malignant and thus cannot be safely followed or simply enucleated. The malignancy grade is categorised as benign, borderline and malignant based on tumour margins, stromal cellularity and overgrowth stromal cell atypia and mitotic activity. Even benign tumours recur (20%) and they may be accompanied by a change to a more malignant status.

### Mammographic appearance:

Phyllodes tumours are usually larger than fibroadenomas. Both tumours present as well circumscribed, oval or lobulated masses, but phyllodes are reported to have a higher density. Small tumours tend to have more smooth edges, while the greater ones are more irregular and lobulated. Illdefined borders may be due to invasion of surrounding breast tissue. Even malignant phyllodes are usually nonspiculated. Very large size and rapid growth are in favor of phyllodes rather than fibroadenoma.

### Breast ultrasonographic appearance:

The modality of choice for the diagnosis reveals well-circumscribed, lobulated masses with heterogeneous internal echogenicity, including solid and cystic components. There are several imaging features that are more frequently encountered in phyllodes tumours than fibroadenomas. These are lobulations, heterogeneous internal texture,

cystic components, horizontal linear clefts, rich vascularisation and irregular margins. Posterior enhancement has also been reported to represent a commonly detected feature in phyllodes tumours, at rates between 50 and 77% in different studies.

### MRI appearance:

Well -defined lobulated masses with cystic components, either due to degeneration or necrosis, which tend to have a cleft-like shape. The presence of internal cystic areas was significantly different between phyllodes tumours and fibroadenomas .The latter are more commonly associated with septations. Solid parts are iso- to high signal on T2WI, but also foci of dark signal can appear, representing areas of haemorrhage or calcification. Breast phyllodes tumour is of low-signal intensity on plain scan T1WI and of higher signal intensity on T2WI. Previous studies described slowly enhancing (type 1) and suspiciously enhancing (types 2 and 3) phyllodes tumours. Wurdinger et al reported that one-third of phyllodes tumours showed a typical malignant enhancement pattern.

### Follow up:

Patient is adv. for follow up with every 3 months in 1<sup>st</sup> year, every 6 month in 2<sup>nd</sup> year then yearly onwards and Self Breast Examination.

### Conclusion

Imaging helps in preoperative diagnosis of phyllodes tumor however a final diagnosis remains on histopathology.

As chances of local recurrence and spread out of malignant phyllodes tumor is considerable therefore radiological and histopathological correlation is important in diagnosis and treatment of phyllodes tumor.

Our case was proven low grade benign phyllodes tumor still we recommended patient for follow up examination.

### Acknowledgments

We are thankful to Dean, Medical Director and Department of Surgery, and Pathology, LN Medical College and J K Hospital for allowing us to use data from the hospital for this case report publication.

### Financial support and sponsorship: Nil

**Conflicts of Interest:** There are no conflicts of interest.

## References

1. Eliza S, Charikleia M et al. (2018). A large benign phyllodes tumour: a case report.
2. Tan BY, Acs G, Apple SK et al. (2016). Phyllodes tumours of the breast: a consensus review. *Histopathology*. 68(1):5-21
3. Tavassoli F.A, Devilee P. (2003). Pathology and genetics of tumours of the breast and female genital organs. *International Agency of Research on Cancer*. 99.
4. Bernstein L., Deapen D., Ross R.K. (1993). The descriptive epidemiology of malignant cystosarcoma phyllodes tumors of the breast. *Cancer*. 71:3020
5. Karim R.Z., Gerega S.K., Yang Y.H. (2009). Phyllodes tumours of the breast: a clinicopathological analysis of 65 cases from a single institution. *Breast*. 18:165.
6. Bapat K, Oropeza R, Sahoo S. (2020). Benign phyllodes tumor of the male breast. *Breast J*. 8(2):115-116.
7. Nielsen VT, Andreasen C. (1987). Phyllodes tumors of the male breast. *Histopathology*. 11: 761-762.
8. Duman L, Gezer NS, Balçık P et al. (2016). Differentiation between Phyllodes Tumors and Fibroadenomas Based on Mammographic Sonographic and MRI Features. *Breast Care (Basel)*. 11(2):123-127.
9. Wiratkapun C, Piyapan P, Lertsithichai P et al. (2014). Fibroadenoma versus phyllodes tumor: distinguishing factors in patients diagnosed with fibroepithelial lesions after a core needle biopsy. *Diagnostic and Interventional Radiology*. 20(1):27-33.
10. Eva Ruvalcaba-Limón, Josefina Jiménez-López, Verónica Bautista-Piña et al. (2016). Phyllodes Tumor of the Breast: 307 Treated Cases, the Largest Mexican Experience at a Single Breast Disease Institution. *Iranian journal of pathology*. 11(4): 399-408.
11. Asoglu OI, Ugurlu MM, Blanchard K, Grant CS, Reynolds C, Cha SS, et al. (2004). Risk factors for recurrence and death after primary surgical treatment of malignant phyllodes tumors. *Ann Surg Oncol*. 11:1011-1017.
12. Chao TC, Lo YF, Chen SC et al. (2002). Sonographic features of phyllodes tumors of the breast. *Ultrasound in obstetrics & gynecology*. 20(1):64-71.



This work is licensed under Creative Commons Attribution 4.0 License

To Submit Your Article Click Here:

**Submit Manuscript**

DOI: [10.31579/2690-8816/042](https://doi.org/10.31579/2690-8816/042)

### Ready to submit your research? Choose Auctores and benefit from:

- fast, convenient online submission
- rigorous peer review by experienced research in your field
- rapid publication on acceptance
- authors retain copyrights
- unique DOI for all articles
- immediate, unrestricted online access

At Auctores, research is always in progress.

Learn more <https://www.auctoresonline.org/journals/clinical-research-notes>