

Tubal Twin Ectopic Gestation Report of Three Different Cases

Maheshgir S.Gosavi*

Siraj Hospital , Senior Consultant , Thane , India

***Corresponding Author:** Maheshgir S.Gosavi, Siraj Hospital,4th Nizampura,Vanjarpatti Naka,Bhiwandi,Thane,Maharashtra state

Country :India, **Email:** raddon84@rediffmail.com,dentismmg@rediffmail.com

Received date: May 30, 2018; Accepted date : June 18, 2018; Published date: June 25, 2018.

Citation this Article: Maheshgir S.Gosavi, Tubal Twin Ectopic Gestation Report of Three Different Cases. J. Obstetrics Gynecology and Reproductive Sciences. **Doi:** 10.31579/2578-8965/011

Copyright : © 2018 Maheshgir S.Gosavi . This is an open-access article distributed under the terms of the Creative Commons Attribution License, which permits unrestricted use, distribution, and reproduction in any medium, provided the original author and source are credited.

Abstract

Gestation outside the uterine cavity in which the implantation occurs in any tissue other than the endometrium is referred as ectopic pregnancy. The most place for occurring ectopic pregnancy (97% of cases) is the fallopian tubes including ampulla (55%), isthmus (25%), and fimbria (17%), and in 3% of patients ectopic pregnancy occurs in the abdominal cavity, ovary, or cervix.[1]The tubal twin ectopic pregnancy is a rare condition, and the first unilateral tubal twin was reported by De Ott in 1891, and the first live twin tubal ectopic pregnancy was reported in 1944 [2].A live tubal twin ectopic pregnancy is a very rare condition and among >100 reports of tubal twin pregnancies, till now, only 8 cases were live [3]. Early diagnosis and treatment of women with tubal twin ectopic pregnancy is very important and may decrease the risk of tubal rupture.. I present three cases of tubal twin ectopic gestation. In the first case, spontaneous unilateral live tubal twin ectopic gestation .The second and third cases spontaneous ruptured twin ectopic gestation .All three cases were successfully managed and there was no history of assisted reproductive technique fertilization or pelvic inflammatory disease .

Objective

The above case report was to describe the ultrasonography findings of tubal twin ectopic gestation , to describe various surgical techniques in management of the condition.

Keywords

spontaneous, tubal twin ectopic, transvaginal usg

Introduction

Gestation outside the uterine cavity in which the implantation occurs in any tissue other than the endometrium is referred as ectopic pregnancy The most place for occurring ectopic pregnancy (97% of cases) is the fallopian tubes including ampulla (55%), isthmus (25%), and fimbria (17%), and in 3% of patients ectopic pregnancy occurs in the abdominal cavity, ovary, or cervix.[1] The tubal twin ectopic pregnancy is a rare condition, and the first unilateral tubal twin was reported by De Ott in 1891, and the first live twin tubal ectopic pregnancy was reported in 1944 [2].A live tubal twin ectopic pregnancy is a very rare condition and among >100 reports of tubal twin pregnancies, till now, only 8 cases were live.[3] Early diagnosis and treatment of women with tubal twin ectopic pregnancy is very important and may decrease the risk of tubal rupture.. The present report describes a successful management of spontaneous twin tubal ectopic pregnancies with no history of assisted reproductive technique fertilization or pelvic inflammatory disease. Objective of the above case report was to describe the ultrasonography findings of tubal twin ectopic gestation, to describe various surgical techniques in management of the condition.

Abbreviations

USG -- Ultrasonography EP – Ectopic Pregnancy

CASE: 1

Case Presentation

A 35 year old female G2P1L1A0, came to casualty at midnight with pain in abdomen since three days with 8 weeks of amenorrhea and bleeding per vaginum since morning. She had history of two spontaneous abortions. Upon examination, her vitals were stable. Abdomen examination was unremarkable .Upon per vaginum examination the cervical movement was tender, the uterus was bulky and soft, and bogginess and tenderness were felt in the right adnexa. However, her urine pregnancy test was positive.

Ultrasonography with doppler study showed a uterus of 8.3x 5.4x 4.2 cms with endometrial thickness of 10 mm and there was evidence of large heterogeneous lesion in the right adnexa of a size 7.1x 5.1 cms, with sac like structure within which two foetal poles measuring 1.4 cm = 7 weeks and five days .Fetal cardiac activity was appreciated .Mild free fluid was seen in the abdomen. An impression of live twin ectopic pregnancy in the right adnexa was made with mild free fluid in an abdomen. A pseudosac like structure was noticed in endometrial cavity .Both ovaries were visualised separately from the right adnexal mass.

In view of the Twin live ectopic pregnancy she was immediately operated. Intraoperatively, the ampullary part of the right fallopian tube was found showed a sac like structure. A right salpingotomy was done. She was discharged on the 7 th day. On cut section of the sac there was evidence of two embryos Pathological evaluation of the surgical specimen showed a diamniotic monochorionic twin's pregnancy within the fallopian tube and measurement of the twin feti estimated their gestational age at 7 weeks.

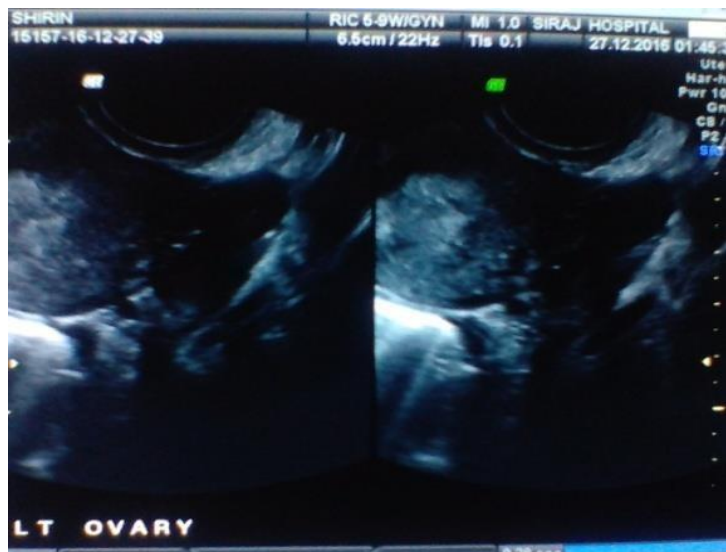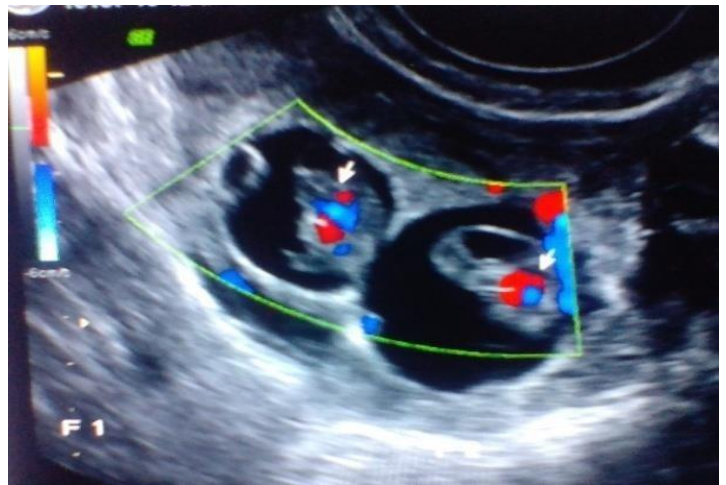

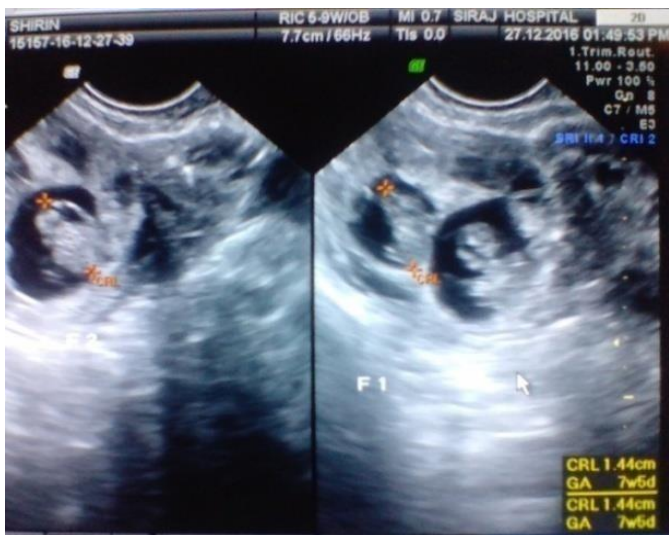
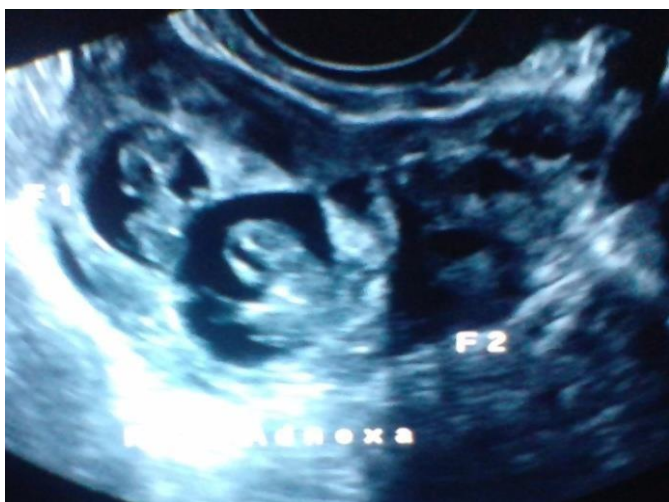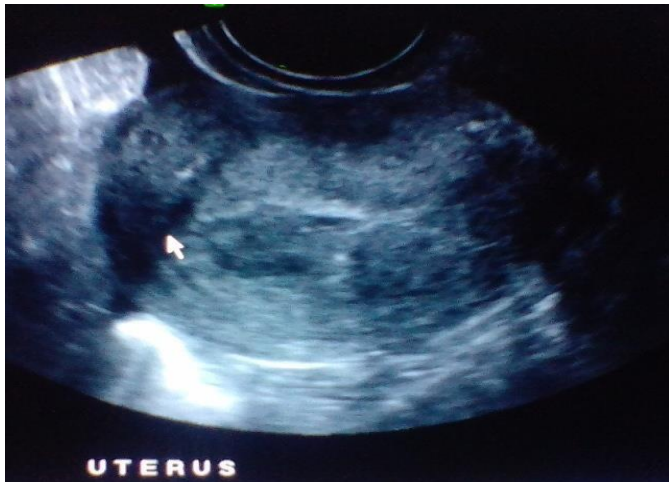Figure 1: Shows Right adnexal sac with Twin live ectopic gestation of approximately 7wks 5 days .No intrauterine pregnancy .Both ovaries are separately visualised.

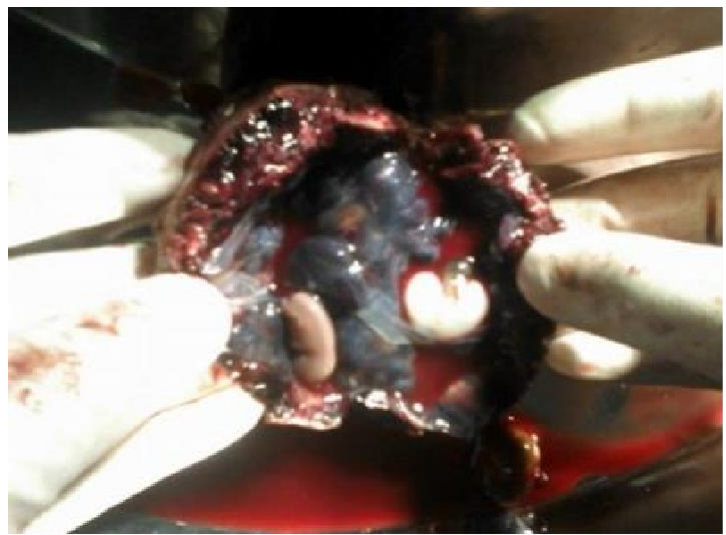


Figure 2: Pathological evaluation of the surgical specimen showed a diamniotic monochorionic twins pregnancy.

CASE 2

A 30 year old female, G2L1A0 came to casualty with severe pain in abdomen since two days with 6 weeks of amenorrhea and bleeding per vaginum since morning .She had one living issues with full term normal deliveries.. Upon examination, her vitals were stable. Abdomen examination was unremarkable. However, her urine pregnancy test was positive .Spontaneous pregnancy there was no history of induction of ovulation by drugs or artificial reproductive techniques

The patient was taken for ultrasonography

Transvaginal Sonography showed a heterogeneous mass in right adnexa measuring approximately 7.3 x 4.6 cm The mass showed irregular Gestational sac measuring approximately 0.3 cm corresponding to 5 weeks and another irregular sac measuring 0.5 cm corresponding to 5weeks 2 days Right ovary was visualised separately from this mass .

Left ovary was visualised and appears normal .Moderate hemoperitoneum was seen .Uterus was bulky however there was no intrauterine gestational.

The diagnosis of right adnexal ruptured ectopic gestation was made .Preliminary investigations were done and patient was taken up for laparotomy in view of right adnexal mass and hemoperitoneum.

Per operatively gross morphology was: Right adnexal complex mass with moderate hemoperitoneum. Right salpingostomy was performed. Patient's post-operative period was uneventful

Histopathology report came out to be right adnexal two gestational sacs were noted.

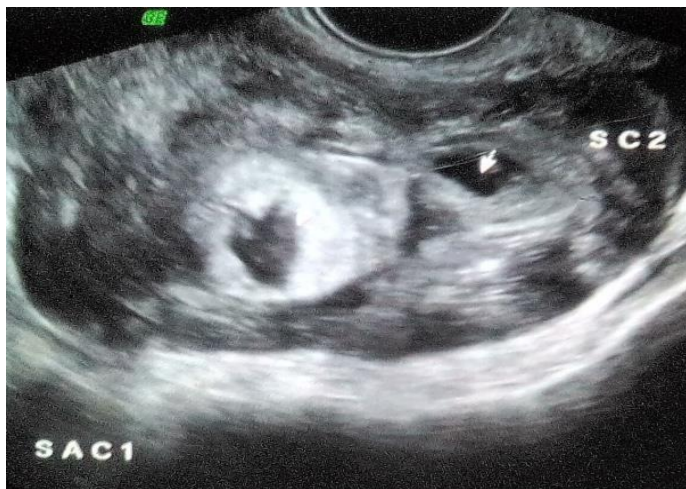

Figure 3: Trans vaginal Sonography shows Right adnexa heterogenous mass with two irregular sacs and hemoperitoneum. Left ovary is visualised .

CASE 3

A 36 year old female, G3L2A0 came to casualty with severe pain in abdomen since three to four days with 6 weeks of amenorrhea and bleeding per vaginum since morning. Upon examination, her vitals were stable. Abdomen examination was unremarkable .Upon per vaginum examination the cervical movement was tender, the uterus was bulky and soft, and bogginess and tenderness were felt in the both adnexae. However, her urine pregnancy test was positive.

Spontaneous pregnancy there was no history of induction of ovulation by drugs or artificial reproductive techniques

The patient was taken for ultra sonography

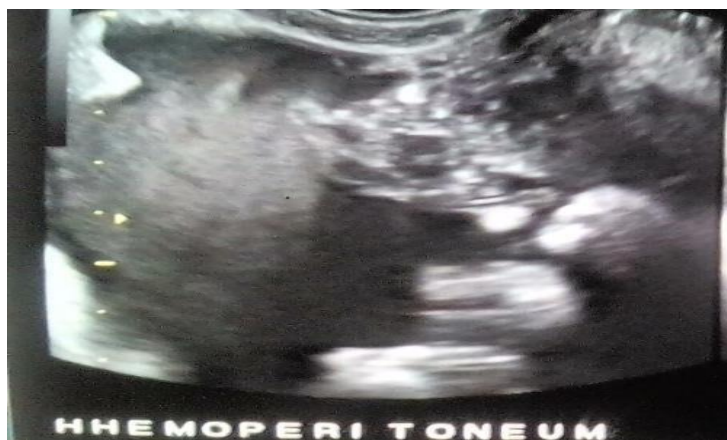Transvaginal Sonography showed a heterogeneous mass in right adnexa with irregular Gestational sac measuring approximately 1.0 cm corresponding to 5 weeks 5 days Right ovary was visualised separately from this mass.

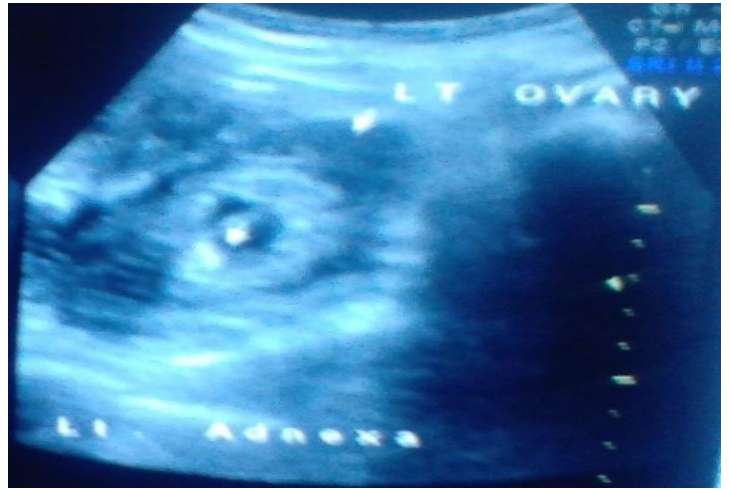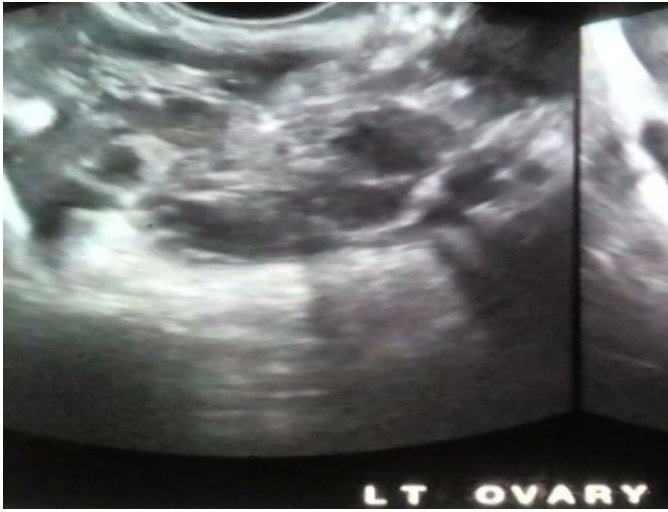Left adnexa irregular Gestational sac measuring approximately 0.8cm corresponding to 5 weeks 4days. Left ovary was visualised separately from this mess .Mild to Moderate hemoperitoneum was seen .Uterus was bulky however there was no intrauterine gestational sac.

The diagnosis of Bilateral adnexal ruptured ectopic gestation was made .Preliminary investigations were done and patient was taken up for laparotomy in view of bilateral adnexal masses and hemoperitoneum.

Per operatively gross morphology was: Bilateral adnexal complex masses with moderate hemoperitoneum. Bilateral salpingotomy was performed. Patient's post-operative period was uneventful

Histopathology report came out to be gestational sacs in bilateral adnexa.





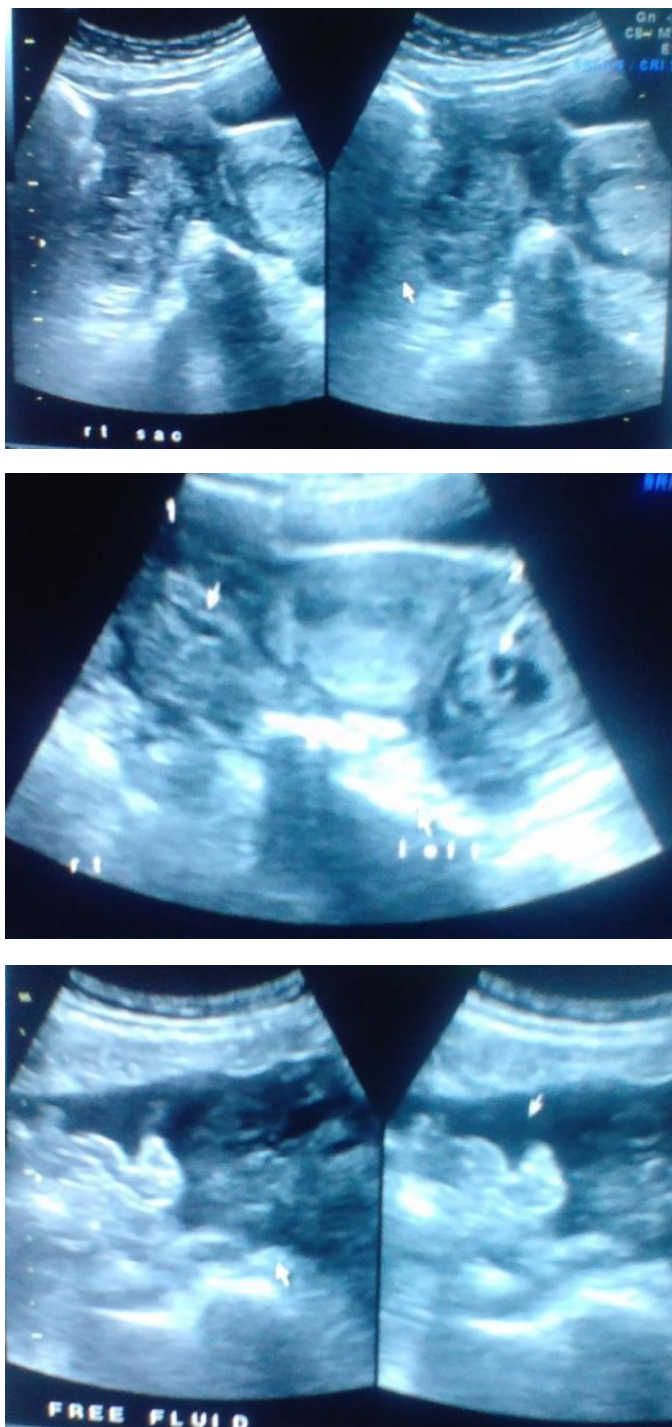

Figure 4: Trans vaginal Sonography shows both adnexae heterogeneous mass with two irregular sacs and hemoperitoneum. Both ovaries are visualized.

Discussion

It is found that the incidence of ectopic pregnancy has risen fourfold compare with the rates of 1970 in the United States (from 0.5% of all pregnancies in 1970 to 2% in 1992).[4] however, unilateral tubal twin ectopic pregnancy are still rare and until now about 100 cases have been reported in the literature.[5] Moreover, fetal cardiac activity has been reported in about <10 cases.[3]

The twin pregnancy is more prevalent among patients with a family history of multiple pregnancies.[6] The incidence of ectopic pregnancy is around 1-2% of all pregnancies[7] and the incidence of spontaneous twin pregnancy is 1:90.[8]

However, live unilateral tubal twin ectopic pregnancy is a very rare condition and occurs in about 1:125,000 of pregnancies.[9] Several risk factors for tubal ectopic pregnancy were identified including active and passive cigarette/tobacco smoking, tubal damage as a result of surgery or infection (particularly Chlamydia trachomatis), and in vitro fertilization.[7] Furthermore, some authors indicated that the number of prior deliveries, ectopic pregnancy, and spontaneous or induced abortions were strongly associated with occurrence of ectopic pregnancy.[10,11]. No such risk factors were present in our patients. It has been demonstrated that the history of ectopic pregnancy leads to an increased recurrence rate of about 10% and 25% for one and two/more previous ectopic pregnancy, respectively.[12]

A history of pelvic pain along with amenorrhea and vaginal bleeding are found in 45% of ectopic pregnancies [2] and probability of ectopic pregnancy in a patient with only abdominal pain and vaginal bleeding is 39%. The likelihood of ectopic pregnancy rises to 54% if the patient has other risk factors, including history of tubal surgery, previous ectopic pregnancy, or pelvic inflammatory disease. [1]

In addition, ultrasound evaluations have facilitated the early EP diagnosis which may lead to a reduction in maternal mortality and morbidity. Also, use of β -hCG assay, especially serial measurements, may improve these evaluations. Studies demonstrated that a β -hCG value of above 1500 mIU/ml corresponds to an approximately 91.5% detection of gestational sacs. [13] However, ultrasonographic findings of suspected adnexal mass and free liquid in the Douglas pouch along with an increased β -hCG levels, especially in association of risk factors, can help the early diagnosis of EP and reduce the related mortality and morbidity.

Twin-ectopic gestations are extremely rare. More than 100 twin tubal pregnancies have been reported, but 13 cases with cardiac activities demonstrated in both fetuses have been diagnosed [14]. The first case of live twin-ectopic pregnancy was described in 1994 [15]. Unilateral twin ectopic pregnancies occur in 1:200 ectopic pregnancies [16]. Most cases are monozygotic and monozygotic [17]. A rare case of diamniotic dichorionic unilateral twin ectopic pregnancy was reported by Ghikeet al. and it appears this patient also had a diamniotic dichorionic twin [18]. They result from the abnormal implantation and maturation of the conceptus outside the endometrial cavity. Diagnosis is made by transvaginal ultrasound and it is crucial to make the diagnosis as soon as possible so that conservative tubal surgery can be planned.

It is reported that the incidence of tubal rupture in was about 32% and the risk of rupture rises about 2.5% for every 24 h period when untreated.[19] Until date, the surgical approach is the most reported option in literature to treat the unilateral tubal twin pregnancies.[20] There have been 4 cases of tubal twin pregnancies (3 unilateral, 1 bilateral) that methotrexate treatment has been tried.[21,22,23,24] However, Arikan et al. suggested that the nonsurgical treatment may be favored in tubal twin EPs in case of stable maternal vital signs and negative fetal cardiac activities.[24] The tubal twin EP is a major health risk for women of childbearing capacity which may lead to life-threatening complications if not treated properly. Therefore, twin EP must be considered base on physical examination and existence of risk factors and should be carefully looked for on ultrasound scanning, due to the potential mortality and morbidity associated with this condition.

Treatment of an ectopic pregnancy depends on its clinical presentation, size, and complications, and may entail conservative, medical, or surgical intervention. Successful laparoscopic management of tubal twin pregnancy and operative laparoscopic salpingotomy reported (25). Salpingectomy is the management of choice in cases of large size of ectopic and ruptured ectopic gestation.

Conclusion

A spontaneous twin tubal pregnancy can occur in patients who have no known predisposing factor. Early diagnosis has made this disorder amenable to appropriate treatment. The high-resolution transvaginal sonography is very helpful in the diagnosis of this condition. Twin-ectopic gestations are extremely rare but there are treatment options. These have typically been classified as either conservative or surgical.

References

1. Lozeau AM, Potter B.[2005] Diagnosis and management of ectopic pregnancy. *Am Fam Physician.* ; 72:1707–14.
2. Dede M, Gezginç K, Yenen M, Ulubay M, Kozan S, Güran S, et al.[2008] Unilateral tubal ectopic twin pregnancy. *Taiwan J Obstet Gynecol.*; 47:226–8.
3. Eddib A, Olawaiye A, Withiam-Leitch M, Rodgers B, Yeh J.9[2006] Live twin tubal ectopic pregnancy. *Int J Gynaecol Obstet.*; 93:154–155.
4. Hois EL, Hibbeln JF, Sclamberg JS. [2006] Spontaneous twin tubal ectopic gestation. *J Clin Ultrasound.*; 34:352–3555.
5. Della-Giustina D, Denny M. [2003] Ectopic pregnancy. *Emerg Med Clin North Am.*; 21:565–584.
6. Kullima AA, Audu BM, Geidam AD. [2011] Outcome of twin deliveries at the University of Maiduguri Teaching Hospital: A 5-year review. *Niger J Clin Pract.* 2011; 14:345–348.
7. Shaw JL, Dey SK, Critchley HO, [2010] Horne AW. Current knowledge of the aetiology of human tubal ectopic pregnancy. *Hum Reprod Update.* 16:432–444.
8. Kazandi M, Turan V. [2011] Multiple pregnancies and their complications. *J Turk Soc Obstet.*; 8:21–24.
9. Parker J, Hewson AD, Calder-Mason T, Lai J. [1999] Transvaginal ultrasound diagnosis of a live twin tubal ectopic pregnancy. *Australas Radiol.*; 43:95–97.
10. Bouyer J, Coste J, Shojaei T, Pouly JL, Fernandez H, et al. [2003] Risk factors for ectopic pregnancy: A comprehensive analysis based on a large case-control, population-based study in France. *Am J Epidemiol.* 157:185–194.
11. Barnhart KT. [2009] Clinical practice. Ectopic pregnancy. *N Engl J Med.*; 361:379–387.
12. Seeber BE, Barnhart KT [2006]. Suspected ectopic pregnancy. *Obstet Gynecol.*; 107:399–413.
13. Barnhart K, Mennuti MT, Benjamin I, Jacobson S, Goodman D,[1994]. Prompt diagnosis of ectopic pregnancy in an emergency department setting. *Obstet Gynecol.*; 84:1010–1015.
14. Summa B, Meinhold-Heerlein I, Bauerschlag DO, Jonat W, Mettler L, et al.(2009) Early detection of a twin tubal pregnancy by Doppler sonography allowsfertility-conserving laparoscopic surgery. *Arch Gynecol Obstet* 279:
15. Gualandi M, Steemers N, de Keyser JL (1994) [First reported case of preoperative ultrasonic diagnosis and laparoscopic treatment of unilateral, twin tubal pregnancy]. *Rev Fr Gynecol Obstet* 89: 134-136.
16. Breen JL (1970) A 21 year’s survey of 654 ectopic pregnancies. *Am J ObstetGynecol* 106: 1004-1019?
17. Storch MP, Petrie RH (1976) unilateral tubal twin gestation. *Am J ObstetGynecol* 125: 1148.
18. Ghike S, Somalwar S, Mitra K,Kulkari S, Ladikar M, et al. (2011) Unilateral TwinEctopic pregnancy (Diamniotic-Dichorionic): A Rare case. *Journal of South Asian Federation of Obstetrics and Gynecology* 3:103-105.
19. Bickell NA, Bodian C, Anderson RM, Kase N. [2004] Time and the risk of ruptured tubal pregnancy. *Obstet Gynecol.* 2004; 104:789–794.
20. Tam T, Khazaei A. Spontaneous unilateral dizygotic twin tubal pregnancy. *J Clin Ultrasound.* 2009; 37:104–106.
21. Fernandez H, Bourget P, Lelaidier C, Doumerc S, Frydman R. [1993] Methotrexate treatment of unilateral twin ectopic pregnancy: Case report and pharmacokinetic considerations. *Ultrasound Obstet Gynecol.*; 3:357–359.
22. Marcovici I, Scoccia B. [1997] Spontaneous bilateral tubal ectopic pregnancy and failed methotrexate therapy: A case report. *Am J Obstet Gynecol.*; 177:1545–1546.
23. Karadeniz RS, Dilbaz S, Ozkan SD. [2008] Unilateral twin tubal pregnancy successfully treated with methotrexate. *Int J Gynaecol Obstet.*; 102:171.
24. Arikan DC, Kiran G, Coskun A, Kostu B. [2011] Unilateral tubal twin ectopic pregnancy treated with single-dose methotrexate. *Arch Gynecol Obstet.*; 283:397–399.
25. Gassibe EF, Gassibe E. [1996] Laparoscopic management of ruptured tubal twin pregnancy. *J Am Assoc Gynecol Laparosc*; 3(4 Suppl):

