

## Report of Objective Clinical Responses in Patients with Brain Cancer to Pharmaceutical-Grade Synthetic Cannabidiol

Julian Kenyon

Old Brewery, Winchester Hants, U.K

**Corresponding Author:** Julian Kenyon, Old Brewery, Winchester Hants, And U.K.

**Received date:** November 10, 2018; **Accepted date:** November 26, 2018; **Published date:** December 04, 2018.

**Citation:** Julian Kenyon, Report of Objective Clinical Responses in Patients with Brain Cancer to Pharmaceutical-Grade Synthetic Cannabidiol. J Brain and Neurological Disorders. 1(1); DOI: 10.31579/2642-973X/001

**Copyright:** © 2018 Julian Kenyon. This is an open-access article distributed under the terms of The Creative Commons Attribution License, which permits unrestricted use, distribution, and reproduction in any medium, provided the original author and source are credited.

### Abstract

**Background/Aim:** Cannabinoids are widely used in the management of pain, nausea and cachexia in cancer patients. However, there has been no objective clinical evidence of any anticancer activity yet. The aim of this study was to assess the effects of Pharmaceutical-Grade Synthetic Cannabidiol on a range of Brain Tumours

**Patients and Methods:** We analysed the data routinely collected as part of our treatment program in 11 Brain Cancer patients over a four-year period.

**Results:** Clinical responses were seen in all of these 11 patients, including a reduction in tumour size, as shown by repeat scans.

There were no side effects of any kind observed when using Pharmaceutical-Grade Synthetic Cannabidiol. Pharmaceutical-Grade Synthetic Cannabidiol was supplied by STI Pharmaceuticals.

**Conclusion:** Pharmaceutical-Grade Synthetic Cannabidiol is a candidate for treating glioma patients.

**Keywords:** cannabidiol; glioma; brain cancer; cannabinoids.

### Introduction

The phytocannabinoids are a group of chemicals extracted from the cannabis plant. A number of them are able to impede cancer cell growth, induce apoptosis and autophagy, and inhibit angiogenesis. The most widely known phytocannabinoid is  $\Delta^9$ -tetrahydrocannabinol (THC), and although it possesses these anticancer effects, it is also psychoactive, which has arguably hampered its clinical development. It is thought that these actions are mediated in part by binding to cannabinoid receptors that are expressed on a number of tissue types (1). As one type of the receptor is found exclusively on brain cells, studies using THC have focused on this tissue type. *In vitro* data were promising and, in 2016, a pilot clinical study in patients with glioblastoma multiforme indicated THC was safe; however, no clear activity was reported (2). The dosages were possibly on the conservative side, to minimise psychoactivity that would naturally restrict the use of THC as drug. Of the 80+ phytocannabinoids, THC is possibly the only one to exhibit this psychoactivity. More recently, studies have diverted away from THC and focussed on other cannabinoids. The next most abundant compound is cannabidiol (CBD), which has a low affinity for the canonical cannabinoid receptors. In contrast to THC, in its pure state, according to the World Health Organisation, CBD did not have abuse potential and caused no harm (3). Studies have shown that in addition to being able to induce cell death directly, it is also capable of interfering with intracellular signalling (4). Alterations to pathways such as the PI3K/AKT/mTOR and the ERK, suggests that CBD can modify the way certain cancer cells react to other treatments. Indeed, studies have shown that combining CBD with conventional chemotherapy such as cytarabine and vincristine can lead to enhanced anticancer activity through modifications to these signalling pathways (5, 6). Furthermore, the sequence in which these drugs are administered can also influence overall activity (5). Studies have also indicated that in certain leukaemia cell lines, CBD can increase the expression of the cyclin-dependent kinase inhibitor p21<sup>waf1</sup> (6). This increased level appears to be maintained by CBD, which inadvertently impedes cell death.

Cytotoxicity can be restored in these cells if the treatment regimen was altered to allow for a temporary cessation of exposure to CBD. Thus, the general efficacy of CBD may also be altered by adapting treatment protocols that include “drug-free” phases (6). The combination of Cannabinoids and  $\Delta^9$  Tetrahydrocannabinol has been shown to be a radiosensitiser (7).

The findings of a number of studies designed to examine the role of cannabinoids in the management of cancer symptoms varied. The most recent prospective analysis of nearly 3,000 patients using medical marijuana showed that a large proportion of patients reported improvement in their condition (8). Patients often feel conventional therapies are not working for them, and so they search the internet for alternative medicines. It is here that they find stories about cannabis working in patients with cancer, and understandably feel it is a route for them. The cannabis products they use vary, and can be in the form of whole plant extracts or purified oils; however, whatever the source, they self-prescribe dosages. A number of anecdotal positive responses have been reported, which sustains the interest in this type of medication.

In order to assess its potential use, we focused on giving patients with Brain Cancers of various sorts (DIPG, Anaplastic Ependymoma, Glioblastoma Multiforme) a Pharmaceutical-Grade Synthetic product at appropriate doses. Every patient in this study signed an informed consent allowing anonymous use of their data. Results with a whole range of solid tumours treated with Pharmaceutical-Grade Synthetic Cannabidiol has been previously reported (10).

### Case presentations

Patients were given synthetic, Pharmaceutical-Grade Synthetic Cannabidiol (STI Pharmaceuticals), registered under the Pharmaceutical Specials scheme in oily drops at 5% (w/v) in 20 ml bottles. Each drop contained 1 mg of synthetic CBD in neutral oil. This was prescribed on an informed consent basis. 11 Brain Tumour patients decided to have this treatment (Table 1).

**Table I.** Tabular presentation of our results in 11 Brain Cancer patients.

Cancer Type	Tumour free	Stable disease	Extended median survival	Slowed progression	No effect/ result	Died	CBD as only treatment	Unknown outcome	Total cases
Anaplastic ependymoma			3				3		3
DIPG			1				1		1
Glioblastoma multiforme			4	3		3	4		7
Total			8	3		3	8		11

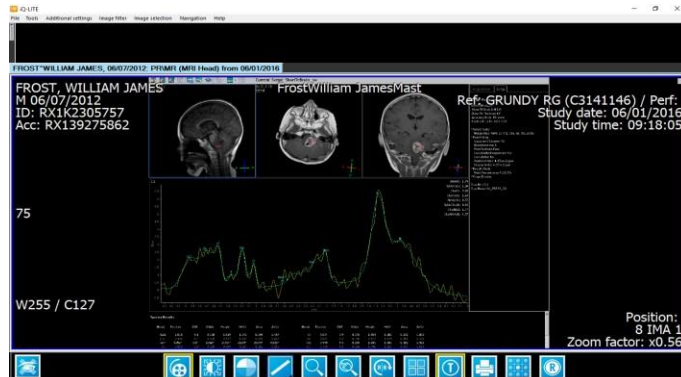Several of these patients had already been taking Cannabis Oil extracted from the Cannabis plant and bought on the Internet, with no beneficial response. This is currently illegal, as the Medicines and Health Regulatory Agency has defined CBD as a medicinal product, which can only be prescribed under the Pharmaceutical Specials scheme, as it is not currently a licensed medicinal product. Eight of these patients used Pharmaceutical-Grade Synthetic Cannabidiol as the only treatment(9).

CBD was administered on three days on and three days off basis, which clinically was found to be more effective than giving it as a continuous dose. The average dose was 10 mg twice a day. For increased tumour mass, the dose was increased, in some cases up to 30drops twice a day (30 mg). In a number of cases where stable disease was present, the dose was reduced to five drops twice a day (5 mg). In some cases, Sativex, which is licensed for use in multiple sclerosis, was used in conjunction with CBD as a source of THC, which synergises with CBD (10). A fraction of the dose used for multiple sclerosis was used. Two sprays of Sativex were given twice a day in three days on and three days off pattern as in the case ofPharmaceutical-Grade Synthetic Cannabidiol; patients on continuous dosing did not do as well as

those on this on-off repeating regimen. Some of these patients reverted to cannabis oil bought on the Internet, and following this, the majority of these cases relapsed.

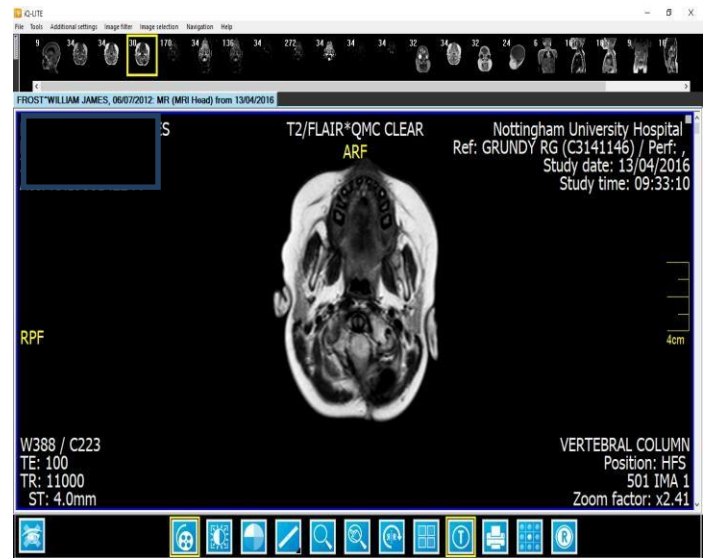
We were unable to define a maximum tolerated dose for CBD, as there was a complete absence of side effects. The minimum durationof treatment required for CBD was six months, but many continuedfor longer. Less than six months appeared inadequate and had little effect, and therefore cases in which CBD was used for less than six months have been defined as un-assessable, and not included in the current cohort of 11 cases.

We sought clear objective evidence of potential efficacy where no other treatment option was available. The most impressive case was a five-year old male patient with an anaplastic ependymoma, a very rare brain tumour. The patient had had all standard treatments, surgery on two occasions followed by chemotherapy and conformal photon radiotherapy. No further treatment options were available to him when treatment on CBD started in February 2016. A scan carried out in December 2016 showed that tumour volume had decreased by ~60%. Further scans, carried out since December 2016, continued to show stable disease. CBD was the only treatment. Four scans with the scan report at the top of each scan are appended (Figure 1A-D).

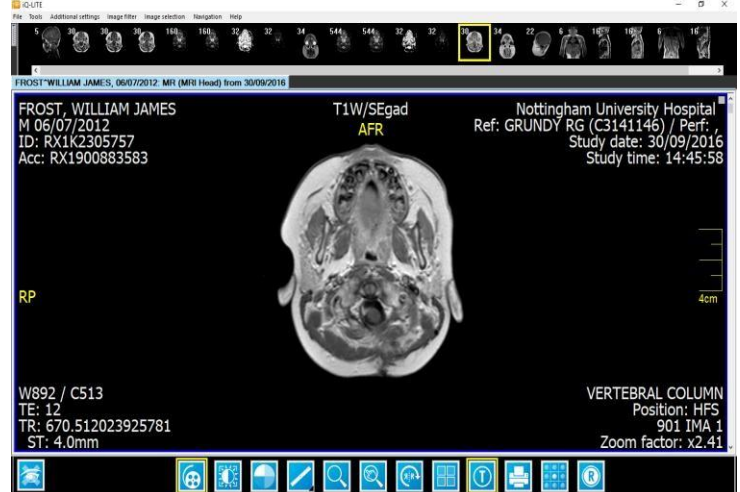


**Figure 1**

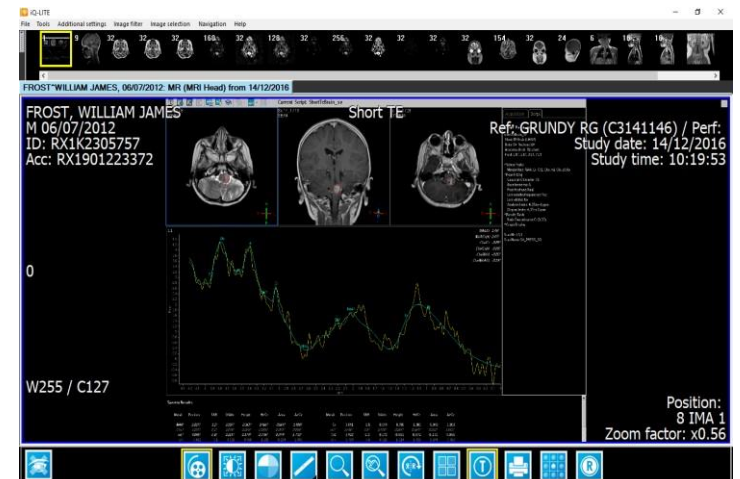**Study 06 01 2016** Further enlargement of the posterior fossa mass. There are some (particularly multimodal) features of radionecrosis but in the context of a previously rapidly progressive tumour then an element of disease progression should also be considered. A short term follow up scan would be informative. (a)



**Study 13 04 2016.** Conclusion: Further tumour progression and development of moderately severe supratentorial hydrocephalus (b)



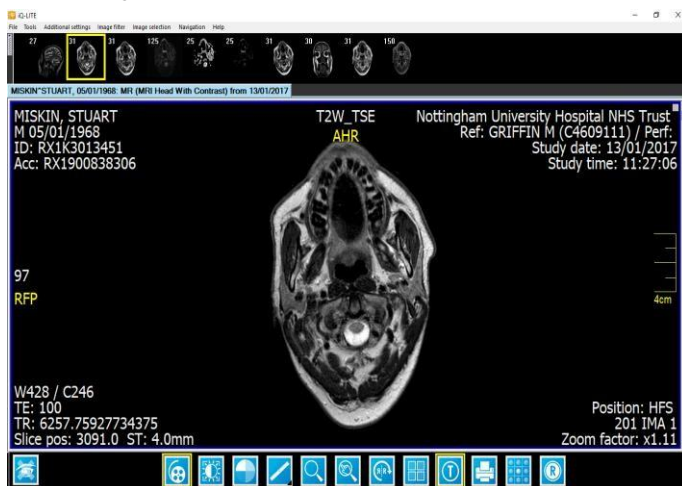
**30 09 16.** Conclusion: Substantial improvement/reduction in size of the residual disease. There has been a substantial improvement in appearances with marked reduction in size of the posterior fossa tumour from 3.4 x 3.2cm in the sagittal plane to 1.7 x 1.7cm (c)



**Study done 14 12 2016. Conclusion: Continued Slow improvement. Clinical information: Impressive resolution of left CPA Recurrent Ependymoma repeat scan in two months. (d)**

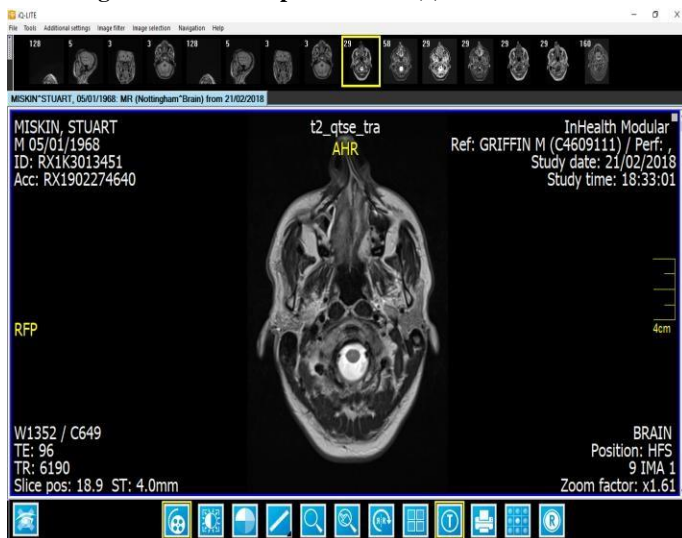Another impressive case was a 50-year-old patient with progressive tanyctic ependymoma Grade 2 diagnosed in June 2013, treated with biopsy and radical radiotherapy, which was completed on 3<sup>rd</sup> June 2015. He refused chemotherapy, and had no further treatment options. He started on pharmaceutical-grade synthetic CBD in July 2016 at a dose of 10 drops twice a day, three days on and three days off (10 mg). Prior to this he had been taking, for some time, metformin, mebendazole, doxycycline and atorvastatin from an oncology clinic in Central London.

In January 2017 a repeat scan showed tumour reduction. At that point the patient stopped taking pharmaceutical-grade synthetic CBD and switched to cannabis oil extract obtained from an internet website. Further scans carried out in February 2018 showed doubling of tumour size and more growth down the brain stem. He has since restarted pharmaceutical-grade synthetic CBD and throughout continued to take the metformin, atorvastatin, doxycycline and mebendazole. So, the only change in November 2017 had been stopping the pharmaceutical-grade synthetic CBD and switching to cannabis oil extract obtained on the Internet (Figure 2A, B).



**Figure 2—Scan report 1**

There is a reduction in size and enhancement of the left periventricular tumour. There is almost complete resolution of the parenchymal enhancement with a couple of small ependymal nodules remaining, but slightly smaller. There is no significant change in the T2/FLAIR appearance with Wallerian de- generation extending into the corticospinal tracts. (a)



**Figure 2 – Scan report 2**

There is evidence of disease progression with a near doubling of the enhancing soft tissue arising from the ependymal surface of the left lateral ventricle and projecting into the body of the left lateral ventricle. There are new enhancing foci in the left putamen and subthalamic region with further non –enhancing T2 hyperintense tumour extending inferiorly into the left cerebral peduncle. (b)

## Discussion

From our laboratory studies, we would not expect any significant anti-cancer activity using continuous CBD alone, as we have only observed cancer cell line apoptosis (cell death) when the agent is washed out of culture and withdrawn. We have also observed a potential increased cell killing ability when given after chemotherapy.

Cannabinoids have an accepted useful role in the management of cancer symptoms, namely pain control, nausea and cachexia, but not as part of primary treatment. The fact that we have been able to document improvement in cancer in few patients strongly supports further studies of CBD-based products in cancer patients who have exhausted standard treatments. Our primary data in a murine glioma model (7) showing enhanced sensitivity to radiotherapy without any side effects, suggests this would be an ideal clinical trial to initiate in the first instance.

## Conflicts of Interest

There are no conflicts of interest to disclose.

## References

- Pertwee RG (2006) The pharmacology of cannabinoid receptors and their ligands: an overview. *Int J Obes* 30: S13-8.
- Guzmán M, Duarte MJ, Blázquez C, Ravina J, Rosa MC et al (2006) A pilot clinical study of Delta9-tetrahydrocannabinol in patients with recurrent glioblastoma multiforme. *Br J Cancer* 95(2): 197-203.
- WHO *Online Q&A*. Cannabidiol (compound of cannabis) December 2017. <http://www.who.int/features/qa/cannabidiol/en/> (accessed March 2018)
- Massi P, Solinas M, Cinquina V and Parolaro D (2013) Cannabidiol as potential anticancer drug. *Br J Clin Pharmacol* 75: 303-312.
- Scott KA, Dagleish AG and Liu WM (2017) Anticancer effects of phytocannabinoids used with chemotherapy in leukaemia cells can be improved by altering the sequence of their administration. *Int J Oncol* 51: 369-377.
- Scott KA, Shah S, Dagleish AG and Liu WM (2013) Enhancing the activity of cannabidiol and other cannabinoids in vitro through modifications to drug combinations and treatment schedules. *Anticancer Res* 33: 4373-4380.
- Scott KA, Dagleish AG and Liu WM (2014) The combination of cannabidiol and Δ9 tetrahydrocannabinol enhances the anticancer effects of radiation in an orthoptic murine glioma model. *Mol Cancer Ther* 13: 2955-2967.
- Bar-Lev Schleider L, Mechoulam R, Lederman V, Hilou M, Lencovsky O, Betzalel et al (2018) Prospective analysis of safety and efficacy of medical cannabis in large unselected population of patients with cancer. *Eur J Intern Med* 49: 37-43.
- MHRA Regulatory status of products containing CBD, published 13<sup>th</sup> October 2016, updated 30<sup>th</sup> December 2016 <https://www.gov.uk/government/news/mhra-statement-on-products-containing-cannabidiol-cbd>
- Julian Kenyon, Wai Liu and Angus Dagleish Report of objective clinical responses in cancer patients to pharmaceutical grade synthetic cannabidiol doi:10.21873/anticancerres.12924 *Anticancer Research* October 2018 vol. 38 (10) 5831-5835 <http://ar.iiarjournals.org/content/38/10/5831.full>