

Mediastinal goitre operated as transclavicular access as adjunct to cervical incision.

Gagliano E¹, Querci A¹, Paparo D¹, Pontin A², Caruso E², Damiano C², Pino A², Dionigi G².

¹Division of General and Emergency Surgery, Department of Human Pathology in Adulthood and Childhood (Chair of General Surgery: Ph. Cucinotta E) University Hospital "G. Martino". University of Messina. Messina. ITALY.

²Division for Endocrine and Minimally Invasive Surgery, Department of Human Pathology in Adulthood and Childhood, University Hospital G. Martino, University of Messina, Messina, Italy.

*Corresponding Author: Ettore Gagliano, Division of General and Emergency Surgery, Department of Human Pathology in Adulthood and Childhood (Chair of General Surgery: Ph. Cucinotta E) University Hospital "G. Martino". University of Messina. Messina. ITALY.

Received date: December 17, 2020; Accepted date: January 15, 2021; Published date: May 25, 2021

Citation: Gagliano E., Querci A., Paparo D., Pontin A., Caruso E., Damiano C., Pino A., Dionigi G. (2021) Mediastinal goitre operated as transclavicular access as adjunct to cervical incision. *J. Surg Case Repo and Imag* 4(4); DOI: [10.31579/2690-1897/049](https://doi.org/10.31579/2690-1897/049)

Copyright: © 2021, Ettore Gagliano, This is an open access article distributed under the Creative Commons Attribution License, which permits unrestricted use, distribution, and reproduction in any medium, provided the original work is properly cited.

Abstract

There are cases in which resection of cervico-mediastinal goitres requires additional thoracic access as an adjunct to standard transverse cervicotomy, and typically this takes the form of sternotomy or thoracotomy. The authors propose transclavicular access as an alternative to thoracotomy or sternotomy access for the removal of such goitres. This technical variant is performed by means of resection of the middle third of the clavicle and extraperiosteal disarticulation. They report a case of cervico mediastinal or "plunged" goitre associated with mediastinal metastasis from a follicular thyroid carcinoma in a 77-year-old woman, in whom this technical variant was used. They conclude by stressing the greater effectiveness, ease of execution and relatively limited "aggressiveness" of the technique in comparison with other ways of reaching the mediastinum. The variant proves effective in solving a number of technical, functional and aesthetic problems.

Key words: cervico-mediastinal goitre, transclavicular access, cervicotomy

Introduction

There are cases in which resection of cervical mediastinal goiters cannot be carried out by a standard incision [1], but requires additional thoracic access, sternotomy, or thoracotomy [2], for total removal.

This can happen above all in the case of large, substernal goiters [2, 3] – so-called "plunged" goiters – whose dimensions impede resection by cervical incision alone and also for other masses, such as benign neoplasm, which give rise to the same technical problems because they develop in the vicinity of and below the thoracic inlet, provided there is no thoracic blood supply [4].

When removing such cervico mediastinal masses whose blood supply is only or prevalently cervical, the difficulties are primarily technical owing to the fact it is impossible to overcome the limitations imposed by the inflexible bony constraints of the upper thoracic inlet, but may also be vascular. Though the cardiotomy step is unavoidable before mobilization by another method and, in general, is enough to control hemostasis, there exists an alternative to sternotomy and thoracotomy, as an adjunct to cervicotomy, consisting in transclavicular access [5, 6].

Even if it is rarely practiced, it is extremely effective and helpful for the surgeon, both for goiters that cannot be removed in other ways, and for other cervico mediastinal masses with cervical blood supply, as in the case described here below, where the two pathologies co-exist and where this

technical variant was used only to remove the second mass [7] which, later, turned out to be a microfollicular thyroid carcinoma.

Case report

The case involves a 77-year-old woman referred to our Department with a relapsing multinodular goiter. The patient underwent a right lobectomy in 1980 for multinodular goiter and a radical right mastectomy in 1998 for invasive ductal carcinoma. She had been suffering from a left anterior cervical mass since 1990, which had progressively increased in volume and was accompanied by clinostatic dyspnoea, desultory at rest, and dysphagia.

Thyroid scintigraphy showed a marked increase in the volume of the left lobe in a subjugular site in the anterior superior mediastinum, and an extensively irregular intraparenchymal uptake of the radiolabeled drug, with several hypo functioning areas, the largest of which were located in sub jugular and left para-isthmus sites.

Needle biopsy suggested a "multinodular hyperplastic goiter". During the patient's stay in the hospital, further ultrasonography showed, in addition to the cervical goiter, a solid nodular, hypoechogenic mass located in a left retrosternal site, measuring approx. 57 mm in diameter, which did not seem to be continuous with the thyroid: a color Doppler assessment revealed a vascular pole from which the central vascularisation departed.

This growth could not be univocally interpreted, even though, at first, it seemed to be consistent with a non-uptaking thyroid nodule or adenomegaly.

Neck-mediastinum CT scan (Fig 1) revealed that the mass was strongly impregnated after the introduction of the contrast medium, located in the anterior superior mediastinum with tracheal compression and situated in a posterior contralateral site.

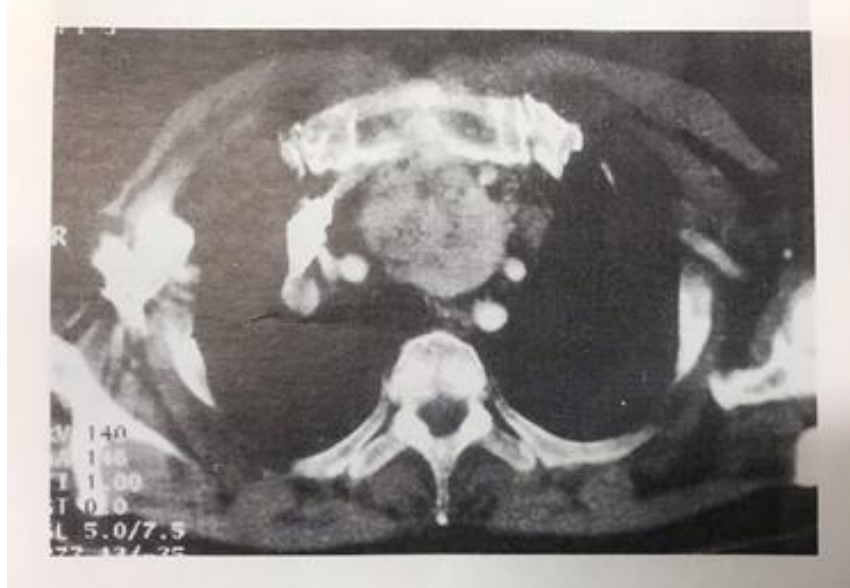

Figure 1: Neck-mediastinum CT scan revealing the mass located in the anterior superior mediastinum.

Furthermore, chest X-rays showed an osteolysis area at the level of the anterior arch of the right 7th rib, which presented as a “pathological hyperenhancement focus” at W.B. Tc99-mMDP bone scintigraphy and was accompanied by diffuse hyperenhancement which persisted in the area of the dorsal-lumbar spinal tract (vertebral bodies D7-D8-L4-L5) and which had already been detected one-year earlier by scintigraphy and targeted X-rays and interpreted as a metastasis from breast cancer.

Also, indirect laryngoscopy showed a hemiparesis of the right vocal cords, which were fixed in the paramedian position, but with sufficient space for breathing.

Oesophagography showed modest dislocation of the esophagus to the right.

Thyroid hormone and blood-chemistry values and ultrasonography findings were normal.

After removal of the previous surgical scar, the surgical access consisted of a standard transverse cervicotomy (Knocker's incision). The left anterolateral incision of the neck was occupied by a voluminous goiter extending from the thyroid left lobe and isthmus and encompassing most of the mediastinum. On the right, where the previous operation had been carried out, thyroid material was absent but an inextricable sclero-cicatricial process was present, with diffuse involvement of the vasculo-nervous bundle.

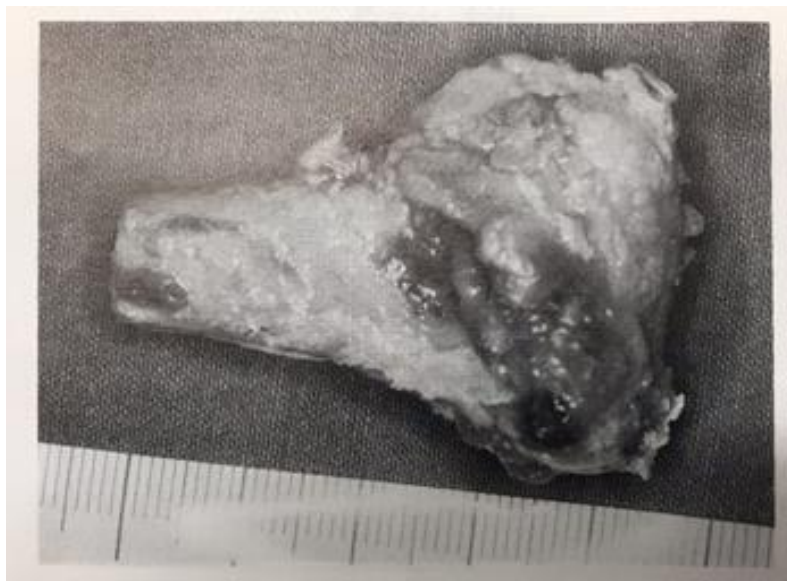

Figure 2: The resected left middle third of the clavicle.

An extracapsular left lobectomy was then carried out. Later, in the left anterior superior mediastinum and a prevascular site, we found a voluminous encapsulated, clearly delimited, oval-shaped mass which immediately proved to be extrathyroidal in origin and nature. It was impossible to remove the mass by standard finger dissection and lift-up through the thoracic inlet.

Because of the condition of the thoracic bones, with costal metastasis contraindicating an additional transthoracic or trans-sternal access, we decided to carry out a left mid-clavicular resection and extraperiosteal disarticulation [2]. On enlarging the thoracic inlet, the mass was located in the cervical region and easily removed [3]. Then, taking into account the right chordal paralysis as a result of the previous operation, we carried out a precautionary tracheo fissure and placed two Redon drains in the thyroid space and the mediastinum.

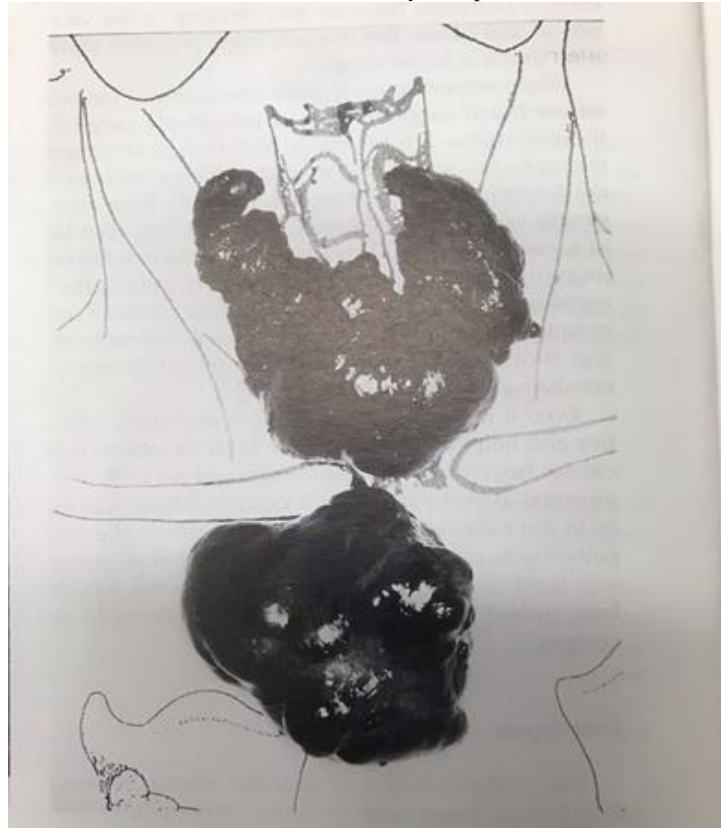


Figure 3: The voluminous goitre and mediastinal mass removed

The postoperative histological examination confirmed the preoperative diagnosis of thyroid goiter and clarified the nature of the mediastinal mass, which proved to be a voluminous metastasis from follicular thyroid carcinoma. This explained the recent osteolytic focus, as an alternative to the earlier interpretation of metastasis from mammary carcinoma.

Thyroglobulin assay (859 ng/ml n.v. 50) provided further confirmation of this hypothesis

Discussion

In our opinion, transclavicular access to the superior mediastinum as an adjunct to cervicotomy is a valid alternative to thoracotomy and sternotomy for the easy removal of transcervical mediastinitis goiters, as proved by the results achieved in this case.

This technical variant proves to be more effective than sternotomy or thoracotomy, since it is easy to perform and less “aggressive”, particularly for “plunged” goiters which cannot be removed by cervicotomy alone.

“Plunged” goiters are cervical goiters which, in 0.3 to 30% of cases, expand in a subjugular and retrosternal site because of the progressive increase in volume. They are firmly located, with the largest diameter, below the thoracic inlet in the anterior or posterior mediastinum, and account for 20% of masses located in that area [8-11]. However, these goiters maintain a cervical vascularisation in contrast to “ectopic” goiters,

which have a mediastinitis blood supply, originating from embryonal thyroid residues in the mediastinum [8-12-14]. Consequently, in ectopic goiter, sternotomy or thoracotomy are and remain the only access routes currently practicable, as in the case of malignant pathologies, infiltrative processes, and posterior “plunged” goiters [10].

Transclavicular access proves capable of solving several problems – technical, functional, and aesthetic – achieving excellent results.

Technically, this access route allows us to overcome the problem of the “mechanical” incongruity between the size of the goiter and the diameter of the thoracic inlet, not only because it enlarges the inlet by breaking it at the clavicular level but particularly because it makes it “extendable” [4-5]. In other words, this access provides the surgeon with the necessary space to go on with blunt finger dissection of the distal part, which would otherwise be unreachable.

Moreover, this type of access allows light to penetrate the operative field and provides the surgeon with a visual check on hemostasis when problems arise that have not been foreseen (as, in our case, during removal of the mediastinal mass). At present, in most cases, hemostasis can be checked and is checked at cervicotomy, in that these are masses that are cervically vascularized.

On the contrary, sternotomy can be more complicated from a technical point of view [6-8] and, as regards the removal of mediastinal plunged goiters, it forces the surgeon to work behind structures such as the left brachiocephalic trunk, without being able to take advantage of the natural cleavage planes, such as that between the thyroid capsule and the mid-cervical aponeurosis, and of the natural protection the latter affords.

Lastly, it is obvious that sternotomy and particularly thoracotomy are more “invasive” than partial clavicular resection, and that they are often out of all proportion to the problem and a bad choice for elderly patients, where the operation is performed on a “senile” skeletal apparatus, even without having to deal with extreme cases of bone metastases, as found in our patient.

As regards the clavicular resection procedure adopted, we performed a periosteal *dècollement* and resection of the middle third of the clavicle (Fig 2), after disarticulating it from the sternum. Indeed, we agree with other authors [4-5] who believe that it is not important to resect a longer or smaller section but to break the sternoclavicular joint and not reposition the clavicular end on the sternal manubrium to prevent postoperative clavisternal osteochondritis from arising. We have no experience with clavicular repositioning using “myocutaneous flaps” [4].

Finally, the extraperitoneal route and mid-clavicular solution allowed us to spare the insertions of the sternocleidomastoid and greater pectoral muscles, which, lying on the periosteum, ensure the antagonistic action of the two muscle groups in the stabilization of the scapular cingulum.

At a postoperative check-up after four weeks, the patient was in no pain, the static status and mobility of her scapular cingulum were satisfactory, and no evidence of marked shoulder asymmetry was observed from the aesthetic point of view.

Conclusions

In our opinion, additional trans clavicular access is a real and indeed a preferential alternative to sternotomy and thoracotomy for the resection of “plunged” goiters that cannot be removed by cervicotomy alone. This opinion is based on our experience, which is admittedly limited to just a single case, but we are convinced that almost all mediastinitis goiters originating from the cervical area – including even the bulkiest ones – can be easily dislocated to the cervical area and then removed by cervicotomy.

This opinion is supported by several technical variants in solving the “mechanical” and “hemostatic” problems which tend to arise during the removal of cervicomediastinal masses with a cervical blood supply, the relative ease of execution, and the reduced “aggressive-ness” of the procedure compared to other ways of reaching the mediastinum which

may give rise to mechanical respiratory problems, particularly in the postoperative phase, in addition to technical difficulties.

This latter feature makes the technique more “proportional” to the goal and also more suitable for the elderly because it is less destructive, especially with a view to an in-hospital and post-discharge postoperative course characterised by rapid, complete functional recovery.

References

1. Picardi N. (1998) Modern surgical technique for thyroidectomy. *Ann. Ital. Chir*; 69: 1-11.
2. Valdoni P, Tonelli L. I gozzi endotoracic. Arch ed Atti Soc. It. Chir 1957;1:189-509
3. Kraimps JL, Gineste D, Gauthier JB, Benand P, Carretier M, et.al (1990): Goitres plongeants. Étude d'une série de 100 cas. *Lyon Chir*;86: 231-240.
4. Papsin BC, Freeman JL, Davis A, Bell RS. (1995) Transclavicular approach to the neck, thoracic inlet, and axilla. *Arch Otolaryngol Head Neck Surg*; 121: 984-987.
5. Picardi N, di Renzo M, Annunziata A, Bartolacci M, Relmi F (1999) L'accesso trans-clavicolare per la liberazione del gozzo immerso permagno. Una proposta chirurgica alternativa. *Ann Ital Chir*;70: 741-748.
6. Picardi N, Pasta V, Monti M. (1977) Contributo allo studio dell'accesso chirurgico dei gozzi endotoracici. *Ann Ital Chir*; 48: 403-418.
7. Armour RH, Conway M, Shenot KN (1997) Retrosternal goitre: a wider view. *Br J Surg*; 84:403-409
8. De Medici A, Mottola P, Zucchermaglio MT, Bargiggia C (1995) I gozzi cervico-mediastinici. Contributo clinico. *Minerva Chir*; 50: 985-992.
9. Maruotti RA, Zannini P, Viani MP, Pezzuoli G. (1991) Surgical treatment of substernal goitres. *Int Surg*; 76: 12-17.
10. Ribet M (1990) Retrotracheal mediastinal goiter with contralateral extension. *Ann Thorac Surg*; 50: 684-688.
11. Di Matteo G, Marcheggiani C, Lucci S: I gozzi cervico-mediastinici. Proceedings. Congresso della Società Italiana di Chirurgia Oncologica. Monduzzi Ed. Roma, 1985; Vol 1, pp 357-374
12. Newman E, Shaha RA (1995) Substernal goiter. *J Surg Oncology*; 60: 207-212.
13. Falor WH, Kelly TR, Krabile WS (1955) Intrathoracic goiter *Ann Surg*;142:238-242
14. Escapasse H, Merlier M: Les goitres à développement thoracique. Paris, J Bailliere Ed. 1973



This work is licensed under Creative Commons Attribution 4.0 License

To Submit Your Article Click Here: [Submit Article](#)

DOI: [10.31579/2690-1897/049](https://doi.org/10.31579/2690-1897/049)

Ready to submit your research? Choose Auctores and benefit from:

- ❖ fast, convenient online submission
- ❖ rigorous peer review by experienced research in your field
- ❖ rapid publication on acceptance
- ❖ authors retain copyrights
- ❖ unique DOI for all articles
- ❖ immediate, unrestricted online access At

Auctores, research is always in progress.

Learn more www.auctoresonline.org/journals/journal-of-surgical-case-reports-and-images