

Open Access

Gallbladder Hypoplasia Treated by Laparoscopy: A Case Report and Literature Review.

Víctor Echenagusia Serrats ^{1*}, Jaione Saez de Ugarte Sobrón ¹, Jose Rebollar ¹, Miguel Angel Garces ¹, Ernesto Martin ¹, Iñaki Martinez ¹, Ruth Bustamante ¹, Maite Camuera ¹, and Elena Merino ¹.

¹University Hospital of Alava, Txagorritxu, Vitoria-Gasteiz, Basque Country Hepa, Spain.

*Corresponding Author: Víctor Echenagusia Serrats, University Hospital of Alava, Txagorritxu, Vitoria-Gasteiz, Basque Country Hepa, Spain. E-mail: Bittor_01@hotmail.com

Received date: September 11, 2019; Accepted date: October 25, 2019; Published date: December 02, 2019.

Citation: Víctor Echenagusia Serrats, Jaione Saez de Ugarte Sobrón, Jose Rebollar, Miguel Angel Garces, Ernesto Martin, Iñaki Martinez, Ruth Bustamante, Maite Camuera, Elena Merino, Gallbladder Hypoplasia Treated by Laparoscopy: A Case Report and Literature Review, J. Gastroenterology Pancreatology and Hepatobiliary Disorders, 3(1): DOI: [10.31579/2641-5194/010](https://doi.org/10.31579/2641-5194/010).

Copyright: © 2019 Víctor Echenagusia Serrats. This is an open-access article distributed under the terms of The Creative Commons Attribution License, which permits unrestricted use, distribution, and reproduction in any medium, provided the original author and source are credited.

Abstract:

The gallbladder hypoplasia is a rare congenital anomaly. We present a case of a 38-year-old man who was referred to us for surgical management of gallbladder disease. The patient presented abdominal pain compatible with repeating biliary colic as the first clinical manifestation. Preoperatively, the magnetic resonance cholangiopancreatography imaging was useful to study thoroughly the biliary tract in order to avoid any iatrogenic injury. Intraoperatively, laparoscopy revealed a rudimentary gallbladder and the histopathological examination confirmed the diagnosis of hypoplastic gallbladder. Laparoscopic cholecystectomy was successful and the patient did not present abdominal pain again.

Key Words: hypoplastic gallbladder; magnetic resonance cholangiopancreatography imaging; laparoscopy

Case Report:

38 year-old patient, presenting epigastralgia and dorsal irradiation for two years. The physical examination shows a painful abdomen in right hypochondrium with positive Murphy sign. The rest of the examination

did not show significant findings. Anodyne analytical, with slight hypertransaminasemia (ALT 73 U/L), without cholestasis pattern or elevations of acute phase reactants. Computerized tomography (CT, Figures 1-2)

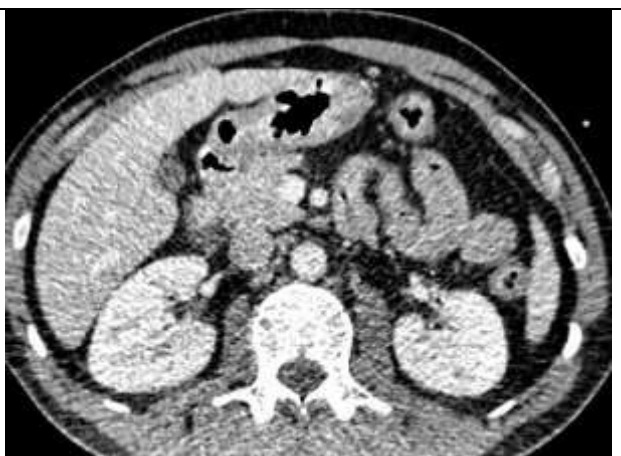
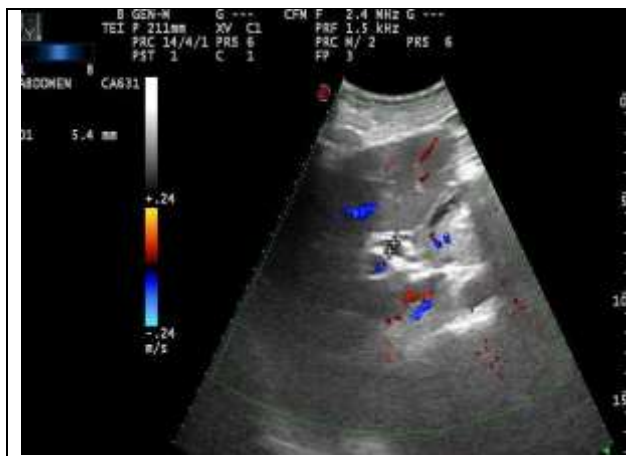


Figure 01 and 02:

CT: Liver of normal size and smooth contour, without space occupant injuries. No splenic focal lesions or adrenal nodules are observed. Collapsed gallbladder, no signs of acute cholecystitis. Normal-sized pancreas and homogeneous attenuation, without peripancreatic fat striation, intra-abdominal free liquid or other signs suggesting acute pancreatitis.

*US: Liver of normal size and morphology that presents a homogeneous

ecostructure without identifying hepatic masses. Porta vein and suprahepatic veins of normal caliber. Biliary gallbladder hypoplasia with 3 microlitasis inside calcified and bile duct intra and extrahepatic of normal caliber. Pancreatic area and spleen with normal characteristics. No free liquid. And Magnetic resonance cholangiopancreatography imaging (MRCI Figures 3-4),

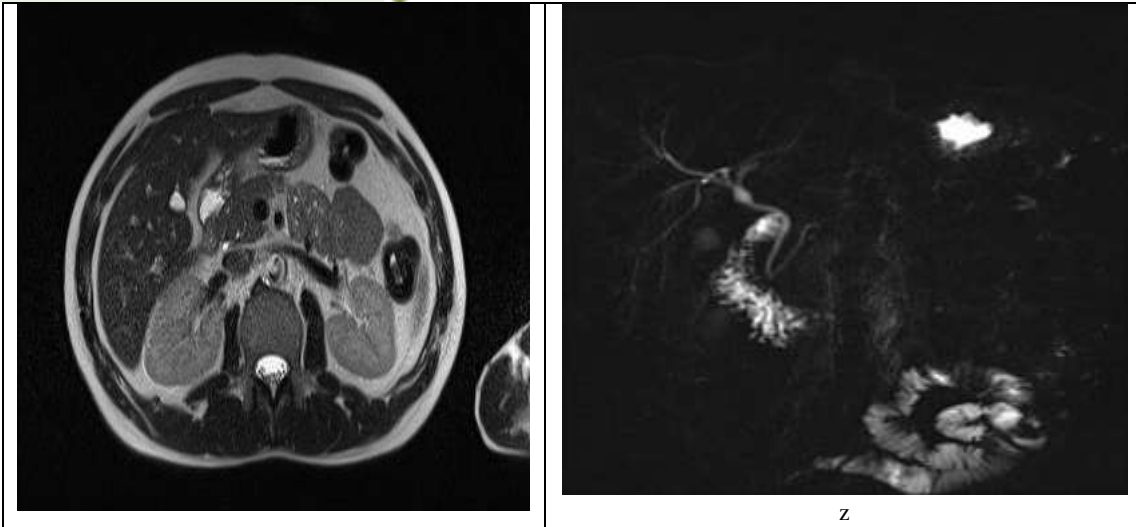


Figure 03 and 04:

Cholangio-RM: No pleural, pericardial or free fluid effusion. Liver size, morphology and normal contours, without evidence of significant signal drop in sequence "opposite phase" suggesting steatosis. No evidence of hepatic LOES. Spleen, pancreas, main pancreatic duct and adrenal glands without significant alterations. No pathological size adenopathies. Intra and extrahepatic bile duct normal, without evidence of repletion defects. Hypoplastic vesicle in patient with seven hours of fasting, it is not possible to assess its content.

Shows a small collapsed gallbladder without signs of acute cholecystitis or chronic cholecystopathy. No lithiasis are identified and bring up the diagnosis of gallbladder hypoplasia. Finally, we perform laparoscopic cholecystectomy. Intraoperatively the diagnosis of vesicular hypoplasia was established (image 5).

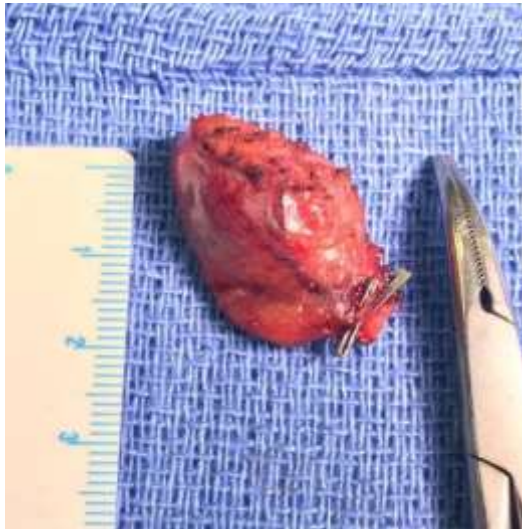

Figure 05: Surgical specimen. Hypoplastic gallbladder with a size of 1,5 x 2 cm. Notice the clips in the cystic duct and cystic artery.

Histopathological examination confirmed a gallbladder hypoplasia with 2 microlithiasis of 2 mm each. The surgical treatment offered a definitive solution to the problem and has not presented abdominal pain.

Discussion:

Gallbladder hypoplasia is a rare congenital anomaly [1]. It consists on a rudimentary, non-functioning, with hypoplastic tissue and a size of 10% of a normal gallbladder developed [2]. Its presentation in adults is extremely rare, being more frequent in the first trimester of life³. Vesicular hypoplasia, either in its pure form or associated with hypogenesis of the bile ducts, has an embryological origin [2]. During the second fetal week the gallbladder develops by endodermal proliferation on the hepatic surface between the segments IV and V [4, 5]. Abnormalities in this process are associated with alterations in size, shape or number [4, 5].

Hypoplasia is less common than vesicular agenesis and is characterized by maintaining proper development of cystic duct and cystic artery [4]. It can be associated with other bile duct malformations, such as the multiseptate gallbladder, derived from an embryological defect in tissue reabsorption that during organogenesis occupies vesicular light [4]. Very few cases have been reported in the literature [4], most common in the context of cystic fibrosis, cholangitis, neonatal hepatitis and biliary atresia [4,5]. It poses a differential diagnosis between vesicular hypoplasia, type II cholederic cyst (choledocian diverticulum) or III (coledocoele) and scleroatrophic gallbladder [1].

Clinically it presents with liver colic in the first months of life being up to 33% of symptomatic cases [5]. Pain in patients with hypoplasia is similar to post-cholecystectomy syndrome pain, which occurs from the dilation of the main bile duct in an effort to store bile, increasing pressure in the Oddi sphincter [1]. This situation increases the risk of cholestasis, cholelithiasis and bile duct infections [1].

It requires a high diagnostic suspicion and often confirmation is done intraoperatively [1, 2]. They require a thorough radiological study, with ultrasonographs being the test of choice in the initial study. Cholangio-resonance and CT scan with HIDA (iminodiabetic acid) provide greater accuracy in the anatomical description, demonstrating anatomical variations that could go unnoticed by increasing the risk of bile duct injury as well as performing an intraoperative cholangiography [1, 3]. There are no standardized clinical guidelines for its management, nor have cases of malignancies been reported [1]. However cholecystectomy is the definitive treatment [1, 4]. Magnification in laparoscopy aids in identification of anomalous anatomy and to precise dissection achieving critical view in Calot's triangle in order to avoid bile duct injury [5].

**Conclusion:**

Vesicular hypoplasia is a rare congenital anomaly with an embryological origin

The exceptionality of this case lies in the low incidence of presentation of gallbladder hypoplasia and in adulthood.

The complementary imaging tests such as cholangio-resonance and HIDA CT are mandatory so as to help the surgical performance by describing possible anatomical variations in order to avoid any iatrogenic injury

Despite no guidelines on its management or possible malignancies, cholecystectomy is the definitive treatment.

References:

1. P. K. Jena, R. AHardie and M. Hobsley (1977). Multiseptate hypoplastic gallbladder. *Br. J. Surg.* Vol. 64; 192-193.
2. Pinky Thapar et al (December 2015). Rudimentary Gallbladder Mimicking Choledochal Cyst. *Indian J Surg*; 77(Suppl 2):S726-728.
3. Sato K, Iwasaki M, Yukawa M, Sato S. Congenital agenesis of the gallbladder, hypoplastic gallbladder, gallbladder atresia. *Ryokibetsu Shokogun Shirizu*. 1196; 9:356-359.
4. Ramón Gomez Contreras et al (2016). Hipoplasia de vesícula biliar con cuadro colestásico comp primera manifestación clínica. *CIR ESP*; 94(4): 238-249.
5. Georgios D. Koimtzis, Maria S. Kosmidou, Fotini Ieridou, Christophoros S. Kosmidis, Triantafyllia Koletsa, et al (2017). Gallbladder Hypoplasia, a congenital abnormality of the gallbladder: A case report. *Am J Case Rep*; 18, 1320-1324.