

Fine Needle Aspiration: who must perform this Procedure?

Negri Stefano^{1*}, Azzolini Diana², Corradi Gabriele¹, Calabrese Giovanni¹

¹Pathology Unit - ASST-Mantova, Mantova, Italy

²Radiology Unit - ASST-Mantova, Mantova, Italy

*Corresponding author: Negri Stefano, Pathology Unit ASST-Mantova Via Lago Paiolo Italy 46100 Mantova.

Received date: August 12, 2021; Accepted date: September 14, 2021; Published date: September 20, 2021

Citation: Negri Stefano, Azzolini Diana, Corradi Gabriele, Calabrese Giovanni. (2021) Fine Needle Aspiration: who must perform this Procedure?. *J. Archives of Medical Case Reports and Case Study*, 4(5); DOI:10.31579/2692-9392/079

Copyright: © 2021 Negri Stefano, This is an open access article distributed under the Creative Commons Attribution License, which permits unrestricted use, distribution, and reproduction in any medium, provided the original work is properly cited.

Abstract

In this historical moment, when FNA seems to have lost its paramount importance, it's necessary to publish the data of the case study carried out from 2007 to 2014 in the pathologic anatomy unit at Carlo Poma Hospital in Mantua.

This work includes 5,586 FNAs performed in various parts of the body. In particular, we examined 583 breast FNAs performed by a pathologist without help from a radiologist. The data confirm that it is very important for a pathologist to be present when a sample is being taken as this results in a decrease in the number of inadequate preparations as well as in improved diagnostic quality.

Key words: FNA; breast; pathologist; radiologist

Introduction

The diagnostic quality of our work in the Pathologic Anatomy Unit at Mantova Hospital enabled us to treat 2000 cases per year by 1990 and this figure has gone up to 3000 since 2000 and 3500 since 2014 with an ever increasing number of FNA on echographic guidance.

The reliability of this diagnostic procedure has led to a very high number of requests for instrumentally-guided exams, both deep and superficial.

This increase, not supported by an adequate rise in the number of pathologists, often compels other professional figures such as radiologists, surgeons or clinicians to perform the exam. [1,2,3]

The aim of this work is to verify the results of FNA on echographic guidance carried out without the aid of a radiologist. The percentage of inadequate samples per anatomic location, as well as the diagnostic effectiveness of breast fine needle aspirations should be analysed calculating sensitivity, specificity, PPV (positive predictive value) and NPV (negative predictive value)

Materials and Methods

No FNA have been carried out without an adequate clinical assessment, preceding radiologic diagnosis or adequate imaging. US-FNAC was performed percutaneously with a high-frequency linear probe.

Protocol: all the procedures were performed by one of the five pathologists of the team who were instructed before. The training period was divided into three main stages. First, a radiologist instructed the five pathologists about how to use the ecograph. In the second stage, the US-guided FNA technique was employed simultaneously by two pathologists, one detecting the lesion, and the other positioning the needle and collecting the specimen. Finally, a single pathologist used the ecograph with one hand, while he used the other to position the needle and collect the specimen.

To collect the specimen, needles with a 25 – 27 gauge were used. The cytological material was obtained by capillarity without using a syringe or a gun which we employed only to empty cystic formations. FNA was performed 3 times repeatedly in order to obtain three adequate samples for each lesion.

The cytological material was placed on glass slides and smeared. Two cytologic samples were fixed in 95% ethyl alcohol immediately following FNA and were stained with Papanicolaou method. The other cytologic sample was not fixed and was stained with May-Grünwald Giemsa method. The sample was evaluated on microscopic examination in order to provide a definitive diagnosis in the short term (≤ 7 days after the procedure).

621 breast FNAs were carried out by a pathologist without help from a radiologist between January 2007 and December 2014, but only 583 were considered as the patients had undergone surgical biopsy or clinical follow-up for a period of at least two years. We defined a conclusive non operative diagnosis as “malignant” in lesions that were malignant on follow-up and “benign” in lesions that were benign on follow-up.

Breast lesions were studied with conventional ultrasound, and, eventually, with Doppler ultrasound before sampling. The characteristics of the lesion, such as solid or cystic structure, presence of necrotic areas or calcifications, were evaluated in order to find the best site for sampling.

The FNA specimens were diagnosed according to the 2006 European guidelines [4]:

C1: unsatisfactory. C2: benign. C3: atypia probably benign. C4 suspicious of malignancy. C5: malignant.

The predictive values were calculated for cases which were “malignant” C5 or “benign” C2 by FNA [3].

Then, the sensitivity and specificity were calculated for the entire group with the assumption that “suspicious” C4 and “malignant” C5 lesions were

positive for malignancy, while the “atypia probably benign” C3, and “benign” C2 lesions were negative. [2,5].

The cases diagnosed as C2 and C3 underwent biopsy only in case of clinical and /or radiological uncertainty (triple test) [6,7].

The diagnostic performance of FNAC was statistically evaluated, defining the percentage of non-diagnostic materials, sensibility, specificity, positive predictive value and negative predictive value, with relation to the final

diagnosis, which was reached after follow-up imaging, clinical course, and/or surgical operation [8].

Results

In the period of 8 years (from 2007 to 2014) in which the procedure was employed, 5,586 FNA were performed, of Figure. 2 which 3,748 on the thyroid, 621 on the breast, 255 on the salivary glands, 367 on lymphnodes and 595 on nodules detected at various locations. (shown in Figure. 1)

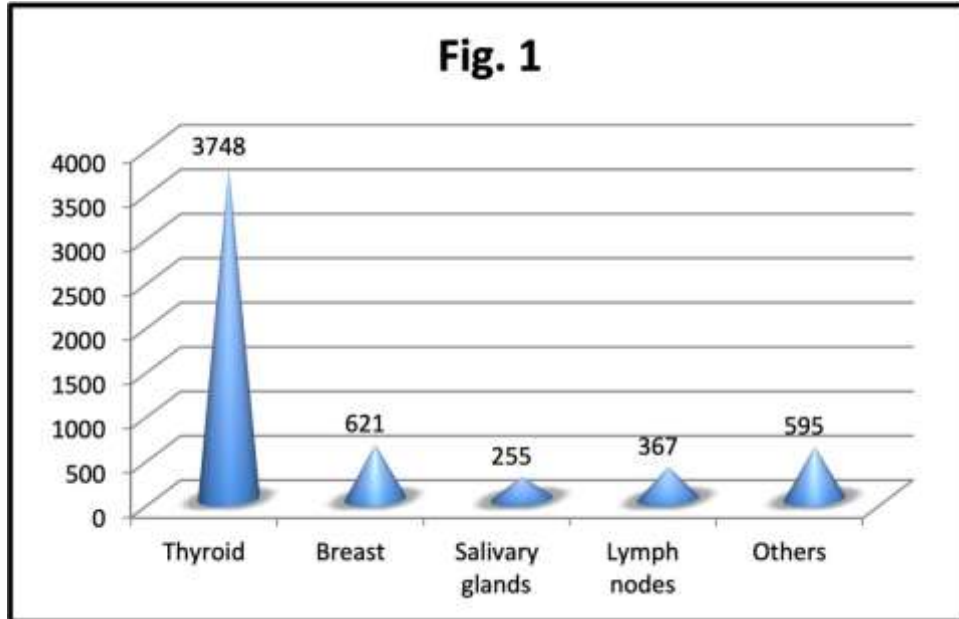


Figure 1: Number of FNA performed

The percentage of inadequates (shown in Figure. 2) depends on the location of the nodule to be examined and varies from 5.18% (19/367) in the case of lymphnodes, to 2.25% (14/621) for mammary ones, with an average value of 4.42 %

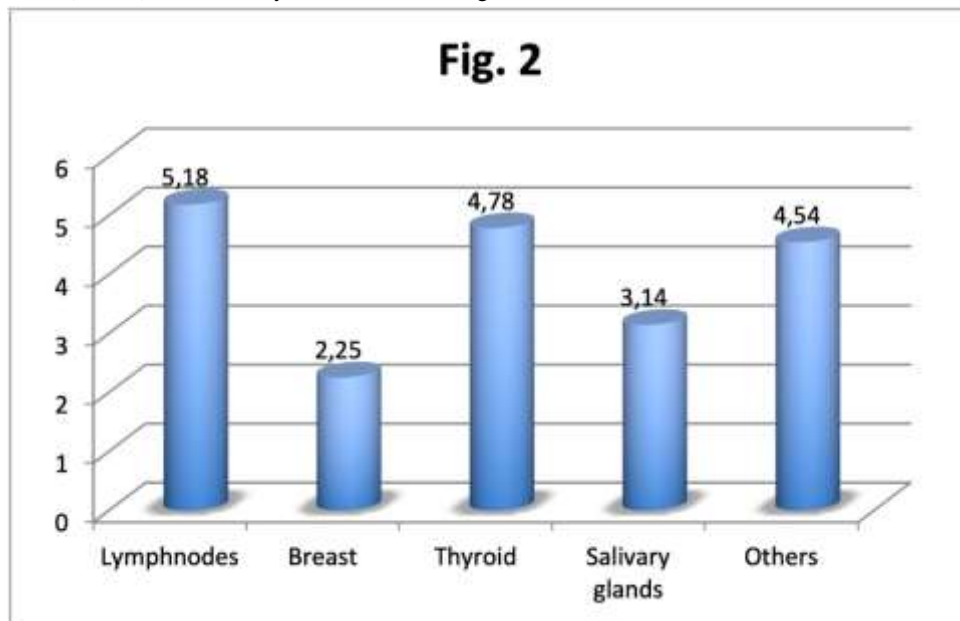


Figure 2: Percentage of inadequates

AS far as breast FNAs were concerned, among the 583 patients whose slides were analysed, 44 were male and 539 were female. The mean age was 51.72

(range 15-92). The final diagnosis was neoplastic in 162 cases and non-neoplastic in 407 cases.

Samples were inadequate in 14 cases (2.4%) in which the final diagnosis showed absence of malignancy after all patients had undergone follow-up. A total of 390 patients out of 583 (66.9%) showed a cytologic diagnosis for a benign condition. Among these cases, 38 patients underwent surgical resection and the final diagnosis showed malignancy in three cases: 2 lobular carcinomas, in one case the lesion was misdiagnosed as benign owing to a mistake during the sampling and was discovered to be malignant on further examination while in another case the pathologist made a diagnostic mistake, and one ductal carcinoma, misdiagnosed due to another error during sampling.

44 cytologic samples (7.5%) were suspicious for malignancy and all these patients underwent surgical resection. Malignancy was confirmed in 24 patients (6 lobular carcinomas, 5 ductal carcinomas, 1 carcinoma with combined lobular and ductal aspects, 1 carcinomatous mastitis, 2 tubuloblastic carcinomas, 1 adenoid-cystic carcinoma, 1 carcinosarcoma, 1 renal cancer metastasis, 1 ductal intraepithelial neoplasia (DIN)3, 3 DIN2, 1 DIN1c and 1 LIN1). A benign lesion was showed in the final diagnosis of 20

cases (8 fibroadenomas, 1 phylloid tumor, 2 mammary cysts, 4 intraductal papillomas, 4 ductal hyperplasias and 1 sclerosing adenosis). A total of 135 patients (23.2%) were positive for malignancy at the cytological examination. All these patients underwent surgical resection and the diagnosis was always confirmed.

96 Ca ductal

20 Ca lobular

4 Ca ductal+ lobular

others (1 stromal sarcoma, 3 micropapillary carcinomas 1 tubular carcinoma, 2 apocrine carcinomas, 3 mucoid carcinomas, 1 neuroendocrine carcinoma, 1 lymphoma, 1 squamous carcinoma, 1 colon metastasis, 1 lung metastasis of adenocarcinoma)

Statistical analysis was made with and without considering the cases that resulted suspicious for malignancy at cytologic examination. In the first case sensitivity, specificity, positive predictive value, negative predictive value and false negative rate were respectively 97.8%, 100%, 100%, 99.2% and 0.77% (shown in Figure. 3); in the latter case they were 98.1%, 95%, 88.8%, 99.2% and 0.77%.

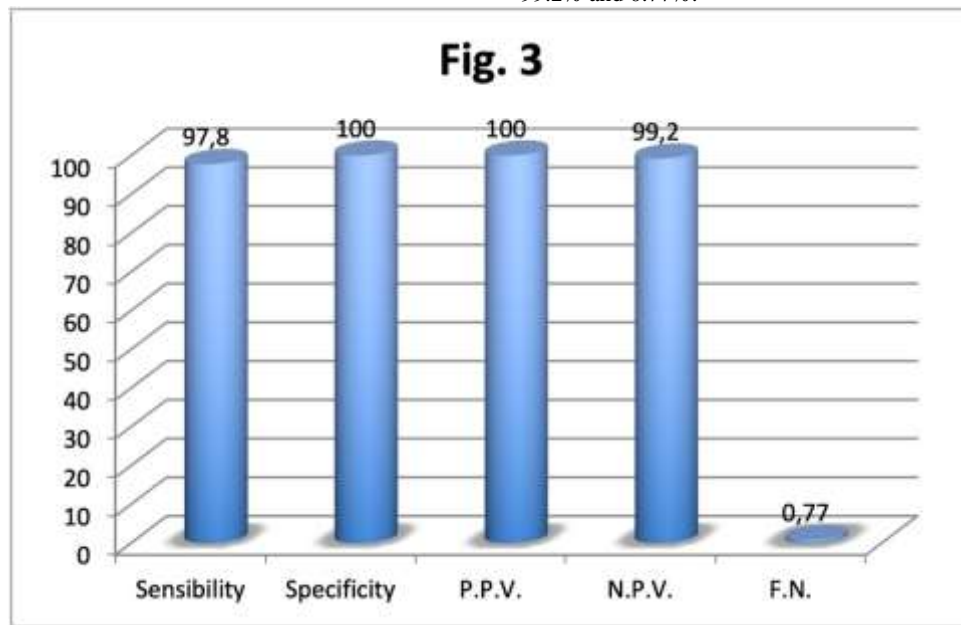


Figure 3: Sensibility, specificity, positive predictive value (PPV), negative predictive value (NPV) and false negative

Discussion

Fine needle aspiration (FNA) cytology has become widely accepted as a reliable diagnostic tool for diagnosing breast lesions. It is a simple, quick, safe, only slightly invasive and fairly cheap method with high sensitivity and specificity [9].

A growing number of requests from doctors and the problems caused by the fact that an anatomopathologist must always be present during the exam, has caused it to be performed by different professional figures. The question however is: who is actually supposed to carry out FNA? The radiologist sees the image well, knows which lesion to examine, knows the probable necrotic areas but he may have never seen a slide and therefore lacks the experience necessary to meet the demands of the anatomopathologist. On the other hand, the pathologist has got little knowledge of the echograph but, if he has good experience of cytology, he knows which needles to use, how to smear and fix the slide and can also modify his sampling method to improve the efficacy of his action. The other professional figures (surgeon and internist) have limited experience in using the echograph and have hardly ever seen a slide. In our study we observed a percentage of inadequate samples, inferior to that reported in literature which presents a wide range of percentages up to 25% [10, 9, 6].

The possibility for the anatomopathologist to examine the slides allows a significant improvement in the methodology compared to other operators (surgeons, radiologists or internists) who haven't got this opportunity [11-15].

In addition, studies looking at the relationship between the level of training in FNA of the person performing the procedure and nondiagnostic rates repeatedly show an inverse relationship between the two [9].

The sensitivity of FNA for breast lesions was 97.8%, while in other studies it ranged from 64% to 97% [10, 2]. The leading causes of false negative diagnoses were interpretative error in 1 case (rare atypical cells in a mainly benign context) and two cases of sampling error. In the literature, the major cause of false negative diagnoses was sampling error rather than interpretative problems [10].

An accurate use of FNA may result in avoiding unnecessary excisions of benign breast lesions [7]. Specificity and positive predictive value (PPV) is one of the most useful indexes of the technique's validity [4]. Our specificity of 100% is higher than that obtained in other studies (84-98.4%) [10]. The absence of false positives, in fact, enables the surgeon to plan the operation accurately as it prevents the use of more expensive, complex and invasive diagnostic methodologies which would not be easily tolerated by patients.

[7-16]. The distinction between in situ and infiltrating breast carcinoma is, in our opinion, the only strong point of core biopsy. However, these methodologies hardly ever allow a full examination of the neoplasia; due to selective sampling, invasion is underestimated in 9-38% of cases showing DCIS on CNB) [8, 3]. In addition, core biopsy employs needles of considerable size which fragment the neoplasia making it difficult for an anatomopathologist to reach a correct diagnosis. For these reasons, even in the presence of a diagnosis of in situ carcinoma, many breast surgeons prefer to carry out an exhaustive study of the sentinel lymph node [8].

Therefore, when the cytologic exam is positive, performing a core biopsy could be useless, except in the cases of pre-operative chemotherapy necessitating the evaluation of the presence or absence of oestrogen and progesterone receptors as well as that of CER-B2). Furthermore, a biopsy might also be harmful as it could be responsible for pitfalls, transport of neoplastic cells, and discomfort for the patient and, finally, difficulty for the surgeon in the detection of the lesion [16].

The status of receptors as well as the index of cell proliferation Ki 67 can easily be assessed on the cytological material obtained by FNA [9].

Some studies have recently shown that hormone receptors and CER-B2 can be analyzed reliably on FNA samples if this information is needed before surgical intervention [3].

FNA on echographic guidance is the most widespread procedure in the field of oncological diagnostics. However, its nationwide use is hampered by the lack of professional figures to be entrusted with the preparation of the material. What's more, the need to integrate the professional skills of the cytologist with those of the radiologist is hindered by the fact that these two figures work in two different departments.

Yet, FNA still has value in the work-up of some patients as it provides an opportunity for a conclusive diagnosis.

Specifically, this may prevent redundant surgeries in patients with benign breast pathology and can spare diagnostic core biopsy or diagnostic excision for malignant lesions.

Additionally, a decisive same-day diagnosis reduces short-term anxiety in patients with a benign pathology and shortens the psychologically stressful waiting period.

Conclusions

The data that we collected from 2007 to 2014 allow us to conclude that a properly-trained pathologist is perfectly capable of performing FNA on echographic guidance without help from a radiologist.

FNA of breast lesions continues to be a reliable and cost-effective diagnostic method, especially when used in conjunction with clinical and imaging correlation, as part of the "triple test".

Statement of Ethics

This study has been performed in accordance with the guidelines for human studies and the research was conducted ethically in accordance with the "World Medical Association Declaration of Helsinki".

The authors have given the written informed consent of the patients and the study was approved by the institute's committee on human research.

Conflict of interest Statement

The authors have no conflicts of interest to declare

Funding sources

The authors have no funding to report

References

1. "Cytopathologist can reliably perform ultrasound-guided thyroid fine needle aspiration: a 1-year audit on 3715 consecutive cases." Bellevicine G, Vigliar E, Malapelle U et al. *Cytopathology*. 2016 Apr;27(2):115-121
2. "False-positive and false-negative cases of fine-needle aspiration cytology for palpable breast lesions." Ishikawa T, Hamaguchi Y, Tanabe M et al. *Breast cancer* 2007; 14:388-392
3. "An analysis of fine needle aspiration versus core needle biopsy in clinically palpable breast lesions: a report on the predictive values and a cost comparison" Nagar S, Iacco A, Riggs T et al. *The Am J of Surgery* 2012; 2014:193-198
4. "European guidelines for quality assurance in breast cancer screening and diagnosis." Perry N, Broeders M, De Wolf C et al. *Health and consumer protection* 4 ed:206-225
5. "General rules for clinical and pathological recording of breast cancer"
6. Sakamoto G, Inaji H, Akiyama F et al. *Breast cancer* 12 (Tokio, Japan) suppl 5 2005
7. "Histopathological correlation of atypical (G3) and suspicious (C4) categories in fine needle aspiration cytology of the breast." Gyal P, Sehgal S, Ghosh S et al. *International Journal of Breast Cancer* 2013art ID965498:1-5
8. "Indeterminate breast fine-needle aspiration: repeat aspiration or core needle biopsy?"
9. Kooistra B, Wauters C, Strobbe L. *Ann Surg Oncol* 2009; 16:281-284
10. "Preoperative cytological and histological diagnosis of breast lesions: a critical review." Kooistra B, Wauters C, Strobbe L et al. *EJSO* 2010; 36:934-940
11. "A retrospective study of the diagnostic accuracy of fine-needle aspiration for breast lesions and implication for future use." Day C, Moatamed N, Fimbres AM et al. *Diagn Cytopathol* 2008;36:855-860
12. "Analysis of fine needle aspiration cytology of the breast. A review of 1.297 cases and correlation with histologic diagnoses." Choi YD, Choi YH, Lee JH et al. *Acta Cytol* 2004 48(6):801-806
13. "A systematic review of ultrasound-guided FNA of lesions in the head and neck—focusing on operator, sample inadequacy and presence of on-spot cytology service." Ganguly A, Burnside G, Nixon P Br J Radiol 2014 dec; 87(1044) 20130571
14. "Conclusiveness of fine needle aspiration in 2419 histologically confirmed benign and malignant breast lesions." Kooistra B, Wauters C, Wobbes T. *The breast* 2011; 20:229-232
15. "Cytopathologist performed ultrasound - guided fine - needle aspiration and core-needle biopsy: a prospective study of 500 consecutive cases." Lieu D. *Diagn Cytopathol* 2008; 36(5):317-324
16. "Value of cytopathologist-performed ultrasound-guided fine-needle aspiration as a screening test for ultrasound-guided core-needle biopsy in nonpalpable breast masses." Lieu D. *Diagn Cytopathol* 2009; 37(4):262-269
17. "Breast imaging for interventional pathologists." Lieu D. *Arch Pathol Lab Med* 2013; 137(1):100-119
18. "Roles of fine-needle aspiration and core needle biopsy in the diagnosis of breast cancer."
19. Kurita T, Tsuchiya S, Watarai Y et al. *Breast cancer* 2012; 19(1):23-29



This work is licensed under Creative Commons Attribution 4.0 License

To Submit Your Article Click Here: [Submit Manuscript](#)

DOI: [10.31579/2692-9392/079](https://doi.org/10.31579/2692-9392/079)

Ready to submit your research? Choose Auctores and benefit from:

- ❖ fast, convenient online submission
- ❖ rigorous peer review by experienced research in your field
- ❖ rapid publication on acceptance
- ❖ authors retain copyrights
- ❖ unique DOI for all articles
- ❖ immediate, unrestricted online access

At Auctores, research is always in progress.

Learn more <https://www.auctoresonline.org/journals/archives-of-medical-case-reports-and-case-study>