

The First of Congenital Cystic Adenomatoid Lung Malformation in Iraq: A Radiologic and Pathologic Study

Aamir Jalal Al Mosawi

Advisor in Pediatrics and Pediatric Psychiatry, Children Teaching Hospital of Baghdad Medical City Head, Iraq Headquarter of Copernicus Scientists International Panel Baghdad, Iraq.

***Corresponding author:** Aamir Jalal Al Mosawi, Advisor in Pediatrics and Pediatric Psychiatry, Children Teaching Hospital of Baghdad Medical City Head, Iraq Headquarter of Copernicus Scientists International Panel Baghdad, Iraq.

Received date: February 08, 2020; **Accepted date:** February 21, 2020; **published date:** February 24, 2020

Citation: Aamir Jalal AM (2020). The First of Congenital Cystic Adenomatoid Lung Malformation in Iraq: A Radiologic and Pathologic Study. Clinical Research Notes, 1(1); DOI: [10.31579/crn.2020/005](https://doi.org/10.31579/crn.2020/005)

Copyright: ©2020 Aamir Jalal AM. This is an open access article distributed under the Creative Commons Attribution License, which permits unrestricted use, distribution, and reproduction in any medium, provided the original work is properly cited.

Abstract

Background: Congenital cystic adenomatoid lung malformation is a very rare condition characterized by replacement of normal pulmonary tissue with cysts of variable size and distribution. The condition is usually unilateral. Very few cases of bilateral and congenital cystic adenomatoid malformation with good outcome after resections of the lesions have been reported, and most cases were stillborn or died early during life.

Patients and methods: A forty-day male infant presented with progressive respiratory distress since the first week of life observed at the Children Teaching Hospital of Baghdad Medical City was studied. The literature was reviewed with aim of describing the early documentation of the condition in the literature.

Results: Clinically, the infant had significant respiratory distress interfering with feeding and evidence of shift of the mediastinum to the right. Chest X ray showed increased translucency of left lung field and mediastinal shift to the right. CT-scan showed large air-filled cyst in the left lung and small air-filled cyst in the right lung. The child was treated successfully by left upper lobectomy. The gross examination of two gray pieces of lung tissue showed on cut section microcysts that were apparent grossly. Microscopical examination showed intercommunicating cysts lined by cuboidal epithelium with gland like appearance confirming the diagnosis of congenital cystic adenomatoid malformation of the lung.

Conclusion: A very rare case of bilateral congenital cystic adenomatoid malformation of the lung is reported and the early documentation of the condition in the literature is described.

Keywords: adenomatoid; lung; malformation; pathologic study; radiologic

Introduction

Congenital cystic adenomatoid lung malformation is a very rare condition characterized by replacement of normal pulmonary tissue with cysts of variable size and distribution. The condition is usually unilateral. The term "Congenital adenomatoid malformation of the lung" was first suggested by Ch'in and Tang in 1949. They reported a stillborn who had a large cystic mass with epithelial lining affecting the lower lobe of the left lung. Ch'in and Tang reviewed ten previously reported cases from the literature including the case of Stoerk (1897) [1, 2]. In 1989, Beluffi et al from et al from Italy emphasized that congenital cystic adenomatoid malformation of the lung is one of the rarest causes of neonatal distress. They counted 405 previously reported cases in the literature, and reported an other sixteen cases, one with bilateral disease [3].

Giubergia et al (2012) from Buenos Aires, Argentina studied 172 cases of congenital cystic adenomatoid malformation, and found that the most common presenting symptoms of the disorder are respiratory distress in children under 6 months of age (40%) and recurrent pneumonia in older children. Lobectomy was the procedure of choice in the majority of patients [4].

Very few cases of bilateral and congenital cystic adenomatoid malformation with good outcome after resections of the lesions have been

reported, and most cases were stillborn or died early during life [5, 6, 7, 8].

Patients and methods

A forty-day male infant presented with progressive respiratory distress since the first week of life observed at the Children Teaching Hospital of Baghdad Medical City was studied. The literature was reviewed with aim of describing the early documentation of the condition in the literature.

Results

Clinically, the infant had significant respiratory distress interfering with feeding and evidence of shift of the mediastinum to the right. Chest X ray (Figure-1) showed increased translucency of left lung field and mediastinal shift to the right. CT-scan showed large air-filled cyst in the left lung and small air-filled cyst in the right lung (Figure-2A). The child was treated successfully by left upper lobectomy. The gross examination of two gray pieces of lung tissue showed on cut section microcysts that were apparent grossly. Microscopical examination showed intercommunicating cysts lined by cuboidal epithelium with gland like appearance confirming the diagnosis of congenital cystic adenomatoid malformation of the lung. Figure-3 shows the patient few days after surgery.

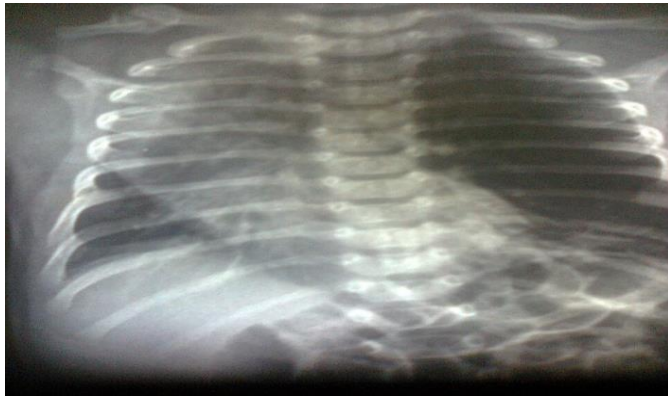

Figure-1: Chest X ray showed increased translucency of left lung field and mediastinal shift to the right

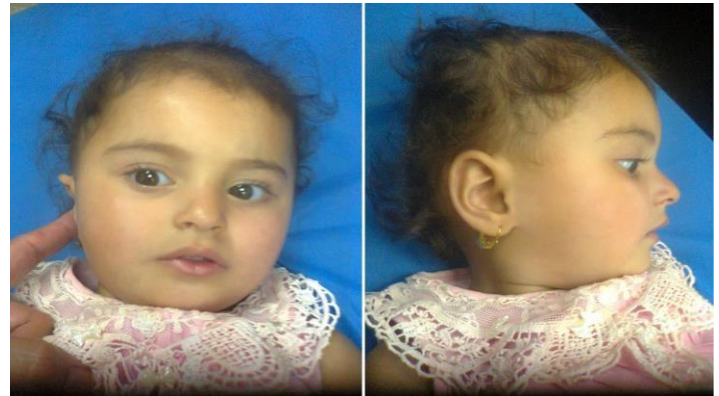

Figure-3: The patient few days after surgery

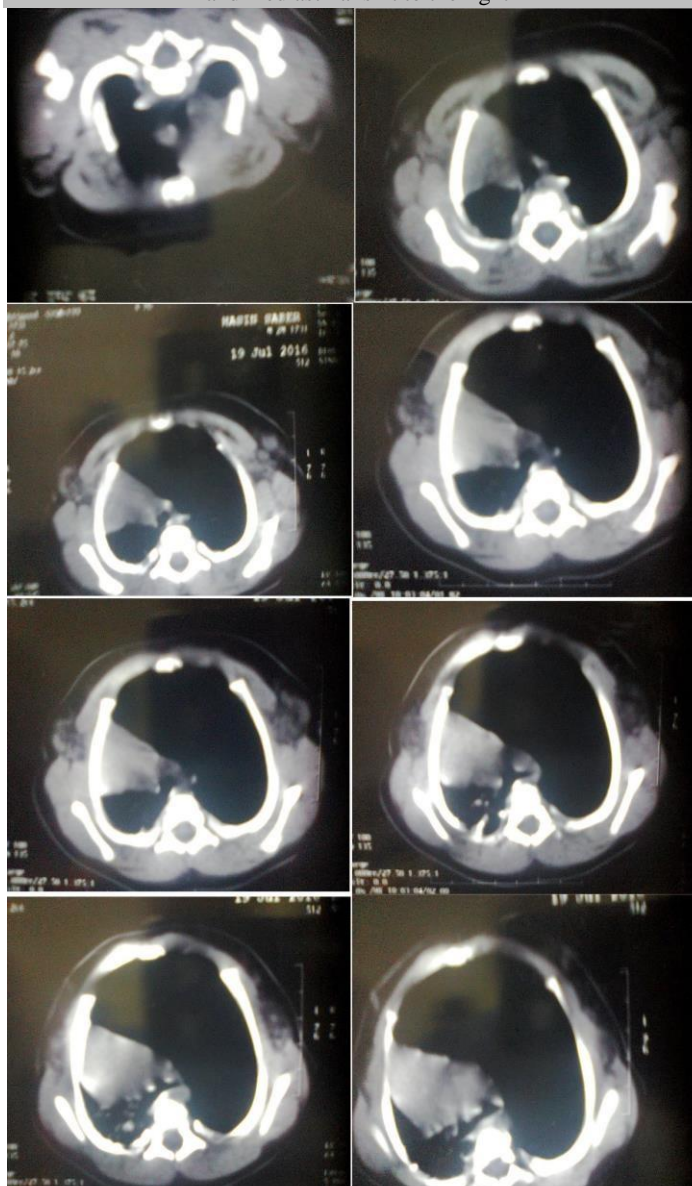


Figure-2: CT-scan showed large air-filled cyst in the left lung and small air-filled cyst in the right lung

Discussion

Congenital cystic adenomatoid malformation of the lung is a very rare condition that was first reported in a stillborn female by Grawitz in 1880 [9]. Storek reported a second case of the disorder diagnosed in a male newborn necropsy in 1897 [2]. Couvelaire reported a third case in a six-day old term neonate in 1904 [10]. Thereafter, another 15 cases of congenital cystic adenomatoid malformation with necropsy diagnosis were reported including the reports of Von Graff (1905), Pappenheimer (1912), Lahm (1919), Seyffert (1920), Sternberg (1923), Meyer (1924), Werbter (1925), Nordmann (1926), Huckel (1927), Esch (1928), Altmann (1929), Wolman (1930), Hunermann and Sievers (1930), Koth (1936) [11,12,13,14,15].

During the 18th century and the twentieth century until 1943, all the cases were necropsy diagnoses.

In 1943, Fischer, Tropea, and Bailey reported the 19th case in a female term infant and it was first case to be diagnosed by surgical resection and not after death [16]. However, Ch'in and Tang (1949) [1], Thomas (1949) [17], and Potter (1952) reported another three cases diagnosed by necropsy [15].

Graham and Singleton (1955) reported a female term infant and treated by surgical resection at six weeks of age and survived [15].

Craig, Kirkpatrick, and Neuhauser (1956) reported four more infants, three of whom were successfully treated by lobectomy in the newborn period [18].

Five more cases diagnosed at necropsy were diagnosed by Gottschalk and Abramson (1957) [19], Bain (1959) [20], Goodyear and Shillitoe (1959) [21], and Kwittken and Reiner (1962) [22]. While, Nanson (1962) [23] and Caffey (1961) [24] reported another two cases diagnosed treated by surgical resection.

Conclusion

A very rare case of bilateral congenital cystic adenomatoid malformation of the lung is reported and the early documentation of the condition in the literature is described.

Acknowledgement

The author would like to express his gratitude for the parents of the patient who willingly accepted publishing his photo.

References

1. Ch'In KY, Tang MY. Congenital adenomatoid malformation of one lobe of a lung with general anasarca. *Arch. Path* 1949; 48: 221.
2. Stoerk O. Ueber angeborene blasige Missbildung der Lunge. *Wien klin Wschr* 1897; 10: 25.
3. Beluffi G, Brokensha C, Kozlowski K, Lucaya J, Masel J, et al. Congenital cystic adenomatoid malformation of the lung. Presentation of 16 cases. *Rofo* 1989 May; 150(5):523-30. PMID: 2541476.
4. Giubergia V, Barrenechea M, Siminovich M, Pena HG, Murtagh P. Congenital cystic adenomatoid malformation: clinical features, pathological concepts and management in 172 cases. *J Pediatr (Rio J)* 2012 Mar-Apr; 88(2):143-8. PMID: 22543527.
5. Schmidt W. Bilateral congenital cystic adenomatoid malformation of the lung. Analysis of a case. *Pathologe*. 1983 Jan; 4(1):55-8. PMID: 6844284. [Article in German].
6. Tristán JU, Gracia Urgellés X, Wiehoff Neumann A, Hernández Briz Estévez Rosas S. et al.. Bilateral multilobular cystic adenomatoid malformation. *Cir Pediatr* 1995 Oct; 8(4):167-9. PMID: 8679395 in Spanish].
7. Uroz-Tristan J, Cabrera-Roca G, Wiehoff-Neumann A, Hernández-Briz MJ, Ceballos-Esparragón J, et al. Bilateral and multilobar cystic adenomatoid malformation of the lung. *Eur J Pediatr Surg* 1998 Dec; 8(6):364-7. PMID: 9926307.
8. Banerjee MC, Wirbelauer J, Adam P, Trusen A, Marx A, et al. Bilateral cystic adenomatoid lung malformation type III: a rare differential diagnosis of pulmonary hypertension in neonates. *J Perinat Med* 2002; 30(5):429-36. PMID: 12442610. PMID: 12442610.
9. Grawitz P. (1880). Ueber angeborne Bronchiectasie. *Virchows Arch path Anat* 1880; 82: 217.
10. Couvelaire A. (1904). Dig-nirescence kystique congenitale dupoumon. *HistogIn6se des deganerescences kystiques congenitales des organes glandulaires (rein, fore, pancrdas, poumon)*. *Rev mens. Afaladies de l'Enfance*, 22, 60.
11. Pappenheimer AM. Congenital cystic malformation of the lung. *Proc NY path Soc n.s.* 1912; 12:193.
12. Altmann F. Beitrage zur Lehre von den Lungenmissbildungen. *Beitr Path Anat* 1929; 82: 199.
13. Wolman JJ. A case of congenital cystic lung in a stillborn fetus. *Bull. Ayer Clin Lab* 1930 (2)12: 49.
14. Hunermann C, Sievers H. Zur klinischen und rdntgenologischen Diagnose angeborener cystischer Lungenmissbildungen im Sauglingsalter. *Z Kinderheilk* 1930; 50: 451.
15. Belanger R, Lafleche LR, Picard JL. Congenital cystic adenomatoid malformation of the lung. *Thorax*. 1964 Jan; 19:1-11. PMID: 14105879.
16. Fischer CC, Tropea F Jr, Bailey CP. Congenital pulmonary cysts: report of infant treated by lobectomy with recovery. *J Pediat* 1943; 23: 219.
17. Thomas MR. A cystic hamartoma of the lung in a new-born infant *J Path Bact* 1949; 61: 599.
18. Craig JM, Kirkpatrick J, Neuhauser EB. Congenital cystic adenomatoid malformation of the lung in infants. *Am J Roentgenol Radium Ther Nucl Med*. 1956 Sep; 76(3):516-26. PMID: 13354842.
19. Gottschalk W, Abramson D. Placental edema and fetal hydrops; a case of congenital cystic and adenomatoid malformation of the lung. *Obstet Gynecol*. 1957 Dec; 10(6):626-31. PMID: 13484170.
20. Bain G. Congenital adenomatoid malformation of the lung. *Dis Chest* 1959; 36: 430.
21. Goodyear JE, Shillitoe AJ. Adenomatoid hamartoma of the lung in a newborn infant. *J. Clin Path* 1959; 12: 172.
22. Kwittken J, Reiner L. Congenital cystic adenomatoid malformation of the lung. *Pediatrics* 1962; 30: 759.
23. Nanson EM. Pulmonary resection in infancy and childhood. *Canad Med Ass J* 1962; 87: 275.
24. Caffey J. On the natural regression of pulmonary cysts during early infancy. *Pediatrics* 1953; 11: 48.