

# Ossification of Non-vascularized Free-Fibula Graft for Mandibular Reconstruction after Resection of Ameloblastoma: Review of Literature and Presentation of 2 cases

Georgina David Dhalwale\*

Behind Hotel Suman, Balaji nagar, Sakri road, Dhule, India.

**Corresponding Author:** Georgina David Dhalwale, Behind Hotel Suman, Balaji nagar, Sakri road, Dhule, India.

**Received Date:** 29 June 2021 | **Accepted Date:** 30 July 2021 | **Published Date:** 09 August 2021

**Citation:** Georgina D Dhalwale. (2021). Ossification of Non-vascularized Free-Fibula Graft for Mandibular Reconstruction after Resection of Ameloblastoma: Review of Literature and Presentation of 2 cases. *Journal of Clinical Surgery and Research*. 2(4); DOI: [10.31579/2768-2757/020](https://doi.org/10.31579/2768-2757/020)

**Copyright:** ©2021 Georgina David Dhalwale, This is an open-access article distributed under the terms of the Creative Commons Attribution License, which permits unrestricted use, distribution, and reproduction in any medium, provided the original author and source are credited.

## Abstract

**Introduction:** Ameloblastoma is a benign neoplasm of odontogenic epithelial origin occurring more commonly in the mandibular posterior region and rarely in the maxilla. About 50-60% of ameloblastomas occur in the mandibular ramus area, while only 10% is seen in mandibular anterior region. Ameloblastomas are slow growing, locally invasive, rarely malignant tumours affecting the jaw. Mostly commonly seen in the 4th-6th decade of life affecting males more commonly than females. The resection of the mandibular segment without adequate reconstruction leads to functional as well as esthetic loss.

**Case Report:** Here we describe two case reports of ameloblastoma with segmental resection and reconstruction using fibula graft.

**Discussion & Review of Literature:** Avascular fibula graft with its high bone density, ease of access to harvest, and tendency to show less resorption helps to achieve satisfactory esthetic contour and function in reconstruction of segmental defects of mandible

**Conclusion:** This article describes two case reports of ameloblastoma with segmental resection and reconstruction using fibula graft along with review of literature.

**Keywords:** ameloblastoma; maxillofacial surgery; fibula graft; reconstruction; mandibular resection; surgery

## Introduction

Ameloblastoma is a neoplasm of odontogenic epithelium of enamel organ -type tissue that has not undergone differentiation to the point of hard tissue formation [11, 18, 25]. Ameloblastomas are rare, benign tumors, representing 1% of the oral tumors and cysts. (13) It is locally invasive with high chances of recurrence [1, 8, 9, 18]. According to WHO 1992, ameloblastoma is defined as, "a benign but locally invasive polymorphic neoplasm consisting of proliferating odontogenic epithelium, which usually has a follicular or plexiform pattern, lying in a fibrous stroma" [4, 5, 6, 8].

Clinically, ameloblastoma is often asymptomatic and slow growing. Ameloblastoma can cause the onset of symptoms such as swelling, dental malocclusion, pain, paraesthesia and anesthesia of the affected region, facial asymmetry, and displacement of teeth and pathological fracture [1, 2, 8, 9, 10].

Surgical management is the measure of treatment of ameloblastomas. It has been proposed that treatment options should be based on clinical signs

and symptoms. It has been suggested that conservative measures for peripheral and unicystic ameloblastoma and a more radical approach of management for the multicystic subtype should be undertaken [3, 14]. Treatment by wide excision is curative in up to 95% of cases [26]. Chana et al. proposed a 1 to 2 cm normal margin, and the large defect left after resection guarantees reconstruction preferably with the free fibula graft [1].

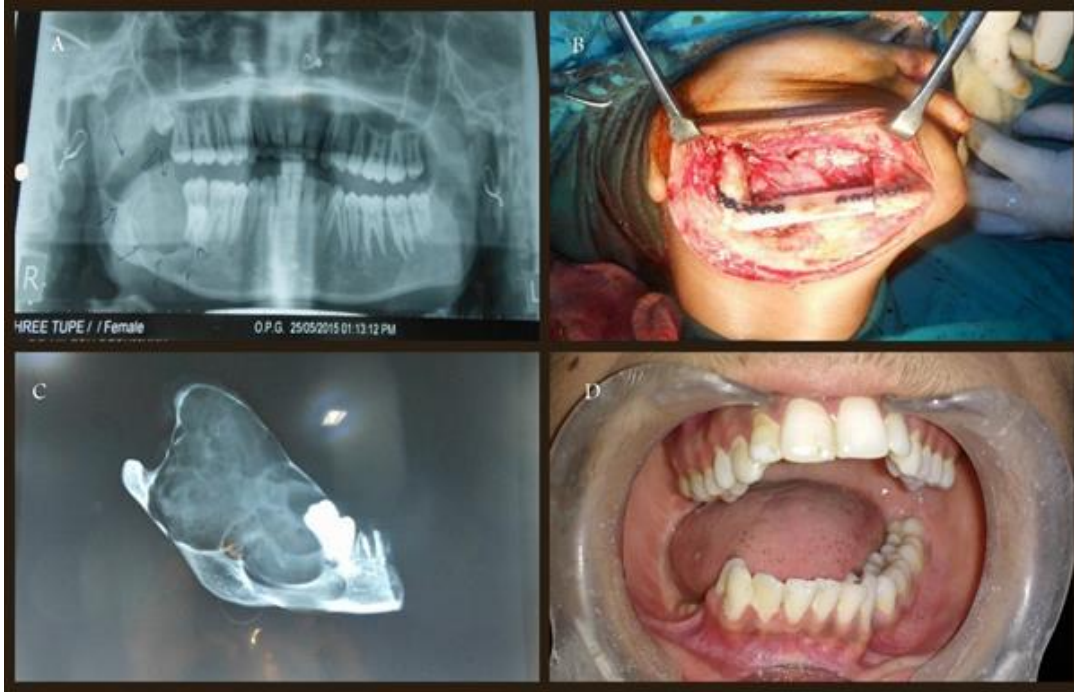In 1989, the first mandibular reconstruction with a fibular flap, using osteotomies to imitate the shape of the mandible, was described [7]. Non-vascularised bone graft with implants provide good contour and aesthetics but are most successful in non-irradiated patients who have adequate soft tissue and where the defect is minimal. Factors like need for skilled professionals and equipment, increased intra-operative time, post-operative period, economic reasons, increased age and compromised medical condition of the patient are against vascular grafting. Thus non-vascularised bone grafts are a viable option for mandibular reconstruction. It can be used for primary reconstruction of mandibular defects due to benign pathologies [27]. Further functional rehabilitation

with implants and removable prosthesis can also be done after 6 weeks of reconstruction [12].

### Case Report 1

A 25 year old female patient, visited our institute with a complaint of pain and swelling in the lower right back region of the jaw since 4-5 months. On extra-oral clinical examination, a single round to oval, ill-defined swelling approximately 5x4 cm in dimension over the right angle and ramus region was noticed. The swelling was hard to firm in consistency,

tender on palpation. On intra-oral examination, a single ulcerative lesion of dimension 2x2 cm was seen in the lower right back region of the jaw in the retro-molar triangle region, which was tender on palpation. Incisional biopsy report was suggestive of Plexiform Ameloblastoma. Wide local excision of the lesion with segmental mandibular resection and reconstruction with free fibula graft was done on the right side. (Fig. 1A, 1B, 1C, 1D) Weight bearing on the donor leg was allowed 1 week post-operatively. Regular follow up was done to ensure the uptake of fibula graft. (Fig. 1E).

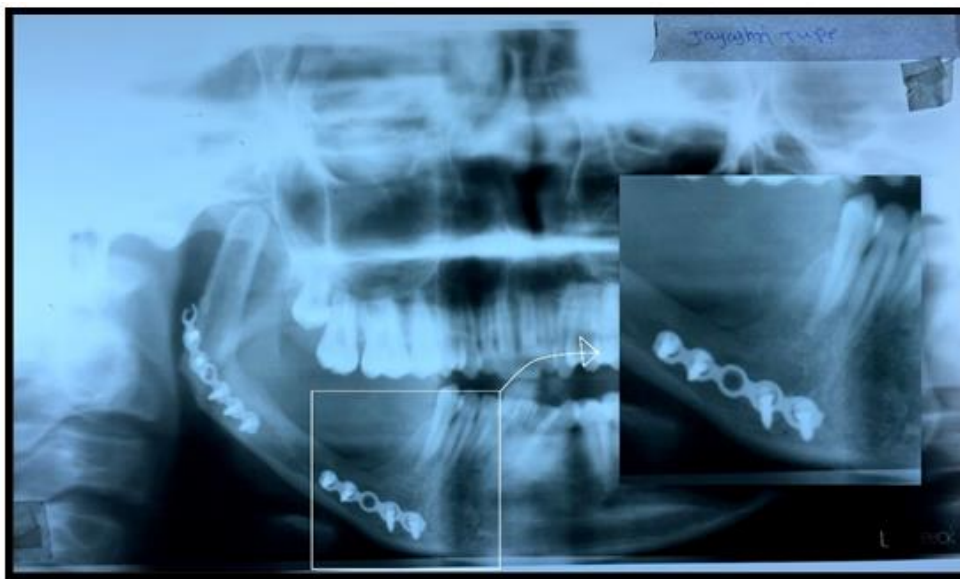

**Figure 1A:** Intra-operative photograph post resection showing mandibular cortical bone erosion caused by the ameloblastoma.

**Figure 1B:** Intra-operative photograph of the graft showing osteosynthesis with titanium plates and screws

**Figure 1C:** Intra-operative radiograph taken of the resected segment to check for margins

**Figure 1D:** Post-operative Intra Oral Pic

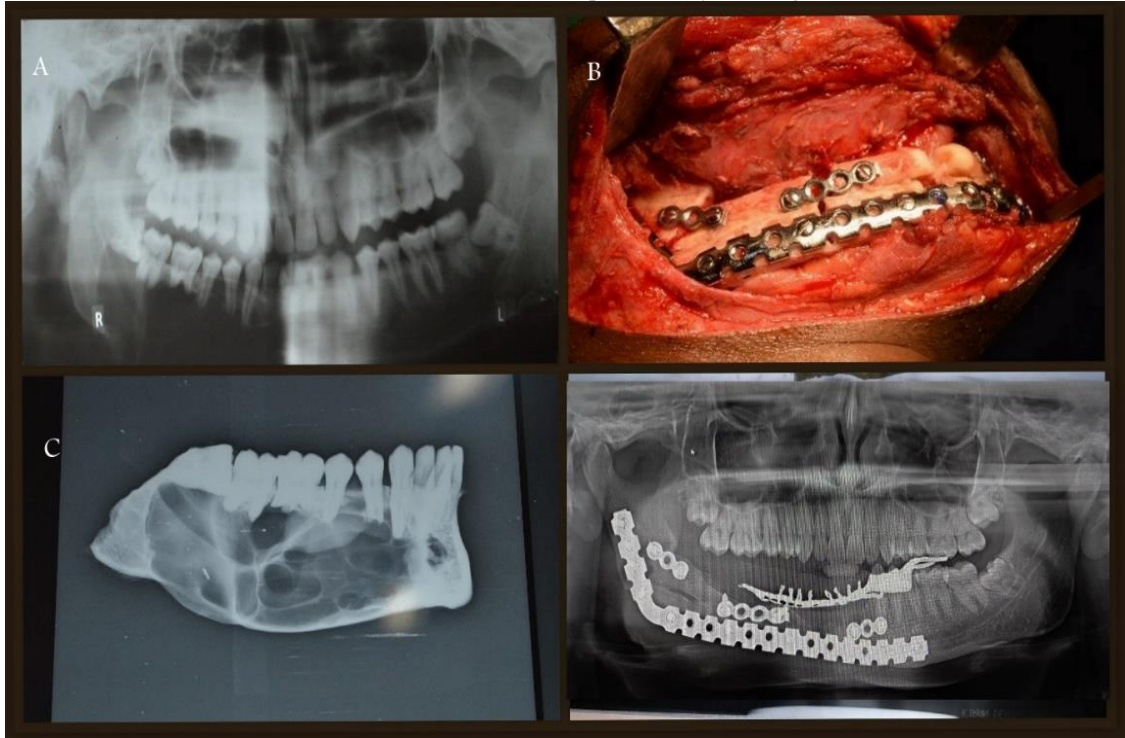


**Figure 1E:** Post-operative OPG showing revascularization of graft in the circled area

## Case Report 2

A 21 year old male patient, visited our institute with a complaint of swelling in the lower right back region of the jaw since 2 months. On extra-oral clinical examination, a single round to oval, ill-defined swelling approximately 5x3 cm in dimension over the right lower border of the mandible was noticed. The swelling was hard to firm in consistency and non-tender on palpation. On intra-oral examination, a single, round to

oval, diffused swelling of dimension 4x3 cm approximately was seen extending from the canine to the second molar on right side, vestibule was obliterated and non-tender on palpation. Incisional biopsy report was suggestive of Ameloblastoma. Wide local excision of the lesion with segmental resection and reconstruction with free fibula graft was done on the right side. (Fig. 2A, 2B, 2C, 2D) Weight bearing on the donor leg was allowed 1 week post-operatively. Regular follow up was taken over a period of 2 years. (Fig. 2D, 3A).

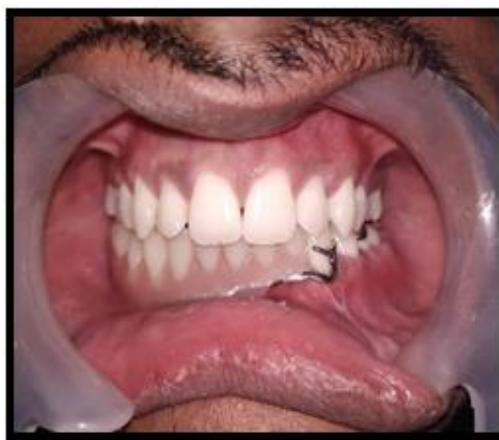

**Figure 2A:** Intra-operative radiograph post resection showing mandibular cortical bone erosion caused by the ameloblastoma.

**Figure 2B:** Intra-operative photograph of the graft showing osteosynthesis with titanium plates and screws

**Figure 2C:** Intra-operative radiograph taken of the resected segment to check for margins

**Figure 2D:** Post-operative OPG. 4 Year Follow up OPG.



**Figure 3A:** Rehabilitation of edentulous space at 6 months post-operatively

## Discussion

Ameloblastoma or adamantinoma, according to World Health Organization (WHO) (1991) defined as a benign but locally aggressive

tumor with a high tendency to recur, consisting of proliferating odontogenic epithelium lying in a fibrous stroma. Robinson in 1997, defined ameloblastoma as "a tumour that is usually unicentric, non-



functional, intermittent in growth, anatomically benign, clinically persistent”.

It was described in 1827 by Cusack and was initially known as adamantoma in 1885 by the French physician Louis-Charles Malassez. It was renamed as ameloblastoma in 1930 by Ivey and Churchill [2, 18, 23].

The clinical signs & symptoms of ameloblastoma in mandible include swelling, malocclusion, pain, paraesthesia, and anesthesia of the affected region, but most of the patients are asymptomatic unless infection leads to pain and are diagnosed during routine plain radiographic films. Therefore, most of the patients are diagnosed late when the mass has grown to an extent that it is clinically evident. When planning the treatment of ameloblastoma, it is important to recognise the growth characteristics and to remove the full extent of the tumor, including the surrounding tissues [2].

Patients with ameloblastoma can be treated in a number of different ways. The best treatment modality is still controversial. Ameloblastomas tend to infiltrate bone trabecula of the cancellous bone on the lesion's periphery and expand through the medullary cortex, before a true bone resorption becomes radiologically evident. Therefore, the true tumor margin goes beyond the clinical or radiographic margin [15].

Conservative treatments for ameloblastoma have lower success rate and chances of local recurrences are high. Segmental resection of the mandible is the current treatment of choice for ameloblastoma. Resection with safety margins of up to 1 cm and immediate reconstruction in the same operating time can provide low recurrence rate, good oral function, and high quality of life [2]. Shirani et al [2007] in a series of 7 patients introduced a technique of removal of large ameloblastoma with immediate reconstruction [16]. Immediate reconstruction is especially significant because unobliterated dead space can accumulate fluids in the operated site that may cause secondary infection leading to un-esthetic appearance and difficulties in mastication, swallowing and speaking. It is concluded that there are less chances of infection, scarring and morbidity with immediate reconstruction procedures following resection. Both the patients in our report were treated with segmental resection, one with disarticulation and one without disarticulation, followed by immediate reconstruction. Also in our cases revascularization of the graft was seen which is not seen often with cases of fibula reconstruction. It is very rare for a non-vascularized graft to be readily accepted, to see revascularization happen and graft being taken up by the bone is remarkable in such cases which can avoid further resorption of bone.

Eppley [2002] did a series of 60 mandibular ameloblastoma cases which showed that there was no recurrence of those cases treated via en bloc resection as compared to enucleation and curettage in which the recurrence rate was high. There are different methods of mandibular reconstruction [16]. Pogrel's comparison study of vascularised and non-vascularised fibula for mandibular reconstruction suggested that any defect <9 cm with adequate soft tissue closure can be successfully reconstructed by means of avascular graft [22]. The ideal flap for such a defect must provide adequate bone length, thickness, and width which should be similar to the mandible, for reconstruction of the bone component of the defect and allowing osseointegration [2]. The various sources for non-vascularized bone graft include iliac crest, fibula, calvarium, rib and tibia [12]. The healing process of non-vascularised bone grafts is by creeping substitution. The graft acts as supporting structure and is replaced by new bone arising by the process of osteoconduction and osteoinduction after resorption of the matrix [17]. Fibula is situated posteriolateral to tibia, with its tubular structure being similar to mandible, dense cortical plates, and presence of endosteal blood supply allows for multiple graft osteotomies to contour without compromising the bone. Availability of 20–25 cm of bone for harvest and least donor site morbidity makes it an ideal choice for reconstruction of

such defects. Since it is not the prime weight bearing bone, its removal does not affect the function of the leg. Thus avascular fibula graft is the reconstruction choice for segmental defects of mandible [12, 24]. In our report, in both the patients fibula graft was taken for reconstruction of the mandibular defect and regular follow up was done to check the gait of the patient which was unaffected. Graft was readily accepted by the bone without any complications. (Refer Fig. 1E, 2D).

Graft union was defined as bony trabeculae bridging between three and four cortices on both the proximal and distal junctions of the autograft with the host bone on radiographs. If union or bony bridging occurred at only one site, it was considered as a nonunion. Long-term post-operative radiograph monitoring was done to evaluate graft union on all patients. Grafts were evaluated to have nonunion if no radiographic bony trabeculae would have crossed the bone junctions on both ends on latest follow-up [28].

The main advantages of fibula grafts are quicker graft harvest with less blood loss, enough length of fibular bone segment for any length of mandibular defect. Disadvantages of fibula are the straightness of the bone, necessitating osteotomies for curvature, which increase the operating time. The common recipient-site complications are dehiscence of intra oral wound due to underlying bony defect [12, 17]. None of our patients showed any complications with respect to the graft. Thus avascular fibula graft with its high bone density, ease of access to harvest, and tendency to show less resorption helps to achieve satisfactory esthetic contour and function in reconstruction of segmental defects of mandible [17].

Vayvada et al. reported no recurrence in any of his 11 patients undergoing segmental resection and fibula reconstruction with a mean follow up of 29.3 months [20]. Chaîne et al. reported similar results where none of his 44 patients had any recurrence with a mean follow up of 53 months [21, 19]. We have treated 2 cases by resection and fibula reconstruction and have not observed any case of recurrence.

## Conclusion

It is a good choice to reconstruct mandibular defect with non-vascularised free fibula bone graft to get a better contour and function. The non-vascularised free fibula graft provides a good alternative to other bone grafts for mandible reconstruction. The main aim of this paper was to highlight the union of non-vascularized fibula graft with the adjacent bone. It is a good choice to reconstruct mandibular defect with free fibula bone graft to get a better contour.

## References:

1. EK Chee, MD, T Sara Ahmad, FRCS, ES Ng, MS (Ortho). (2007). Fibula Osteocutaneous Flap for Mandible Reconstruction after Ameloblastoma Resection: Amending Technique to Reduce Ischaemic Time. *Malaysian Orthopaedic Journal*. 1(1).
2. Haluk Vayvada, MD, Fahri Mola, MD, Adnan Menderes, MD, and Mustafa Yilmaz, MD. (2006). Surgical Management of Ameloblastoma in the Mandible: Segmental Mandibulectomy and Immediate Reconstruction with Free Fibula or Deep Circumflex Iliac Artery Flap (Evaluation of the Long-Term Esthetic and Functional Results). *J Oral Maxillofac Surg*. 64:1532-1539.
3. Adrian Ooi, Jiajun Feng, Hiang Khoon Tan, Yee Siang Ong. (2014). Primary treatment of mandibular ameloblastoma with segmental resection and free fibula reconstruction: Achieving satisfactory outcomes with low implant prosthetic rehabilitation uptake. *Journal of Plastic, Reconstructive & Aesthetic Surgery*. 67; 498-505.
4. Mark L. Smith, MD, Emily Clarke Pearson, MD, Joseph H. Dayan, MD. (2012). Fibula osteo-adipofascial flap for mandibular

- and maxillary reconstruction. 2011 Wiley Periodicals, Inc. Head Neck 34: 1389-1394.
5. Small IA, Waldron CA. (1955). Ameloblastoma of the jaws. Oral Surg Oral Med Oral Pathol 8:281.
  6. Wei FC, Santamaria E, Chang YM, et al. (1997). Mandibular reconstruction with fibular osteoseptocutaneous free flap and simultaneous placement of osseointegrated dental implants. J Craniofac Surg 8:512.
  7. R. Pellini, G. Mercante, and G. Spriano. (2012). Step by step mandibular reconstruction with free fibula flap modelling. Acta Otorhinolaryngologica Italica. 32(6), 405.
  8. Girish B. Giraddi, Kirti Arora, Aamir Malick Saifi. (2017). Ameloblastoma: A retrospective analysis of 31 cases. Journal of Oral Biology and Craniofacial Research.
  9. Hariram, Shadab Mohammad, Laxman R. Malkunje, Nimisha Singh, Sugata Das, Gagan Mehta. (2014). Ameloblastoma of the anterior mandible. National Journal of Maxillofacial Surgery. 5(1).
  10. A. Laborde, R. Nicota, T. Wojcik, J. Ferri, G. Raoul. (2017). Ameloblastoma of the jaws: Management and recurrence rate. European Annals of Otorhinolaryngology, Head and Neck diseases. 134; 7-11.
  11. K. M. K. Masthan, N. Anitha, Jayasri Krupaa, Sudha Manikkam. (2017). Ameloblastoma. Journal of Pharmacy and Bioallied Sciences. 7(S1).
  12. Sathya Kumar Devireddy, M. Senthil Murugan, R. V. Kishore Kumar, Rajasekhar Gali, Sridhar Reddy Kanubaddy, M. Sunayana. (2013) Evaluation of Non-vascular Fibula Graft for Mandibular Reconstruction. J. Maxillofac. Oral Surg.
  13. José Raphael de Moura Campos Montoro, Marconi Gonzaga Tavares, et al. (2008). Mandibular ameloblastoma treated by bone resection and immediate reconstruction. Rev Bras Otorrinolaringol. 74(1): 155-157.
  14. X.F. Shan, J. Liang, L. Zhang, Z.G. Cai. (2017) Mandibular defects reconstruction with fibula flap and free fibula bone graft. International Jour of Oral Max.
  15. Jose Rapbael de Moura Campos Montoro, Marconi Gonzaga Tavares, et al. (2008) Mandibular ameloblastoma treated by bone resection and immediate reconstruction. Rev Bras Otorrinolaringol. 74(1): 155-157.
  16. Rahul Srivastava, Parvathi Devi, Bhuvan Jyoti, Shobhit Pradhan, Ashutosh Shukla. (2013). Follicular with plexiform ameloblastoma in anterior mandible: Report of case and literature review. Indian Journal of Dentistry. 4;119-124.
  17. Sathya Kumar Devireddy, M. Senthil Murugan, R. V. Kishore Kumar, Rajasekhar Gali, Sridhar Reddy Kanubaddy, M. Sunayana. Evaluation of Non-vascular Fibula Graft for Mandibular Reconstruction.
  18. K. M. K. Masthan, N. Anitha, Jayasri Krupaa, Sudha Manikkam. Ameloblastoma. Journal of Pharmacy and Bioallied Sciences. 7(1).
  19. A. Laborde, R. Nicot, T. Wojcik, J. Ferri, G. Raoul. (2017). Ameloblastoma of the jaws: Management and recurrence rate. European Annals of Otorhinolaryngology, Head and Neck Diseases 134; 7-11.
  20. Vayvade H, Mola F, Menderes A, Yilmaz M. (2006) Surgical management of ameloblastoma in the mandible: segmental Mandibulectomy and immediate reconstruction with free fibula or deep circumflex iliac artery flap (evaluation of the long term esthetic and functional results). J Oral Maxillofac Surg. 64:1532-1539.
  21. Chaîne A, Pitak-Arnop P, Dhanuthai K, Ruhin-Poncet B, Bertrand JC, Bertolus C. (2009). A treatment algorithm for managing giant mandibular ameloblastoma: 5-year experiences in a Paris university hospital. Eur J Surg Oncol. 35:999-1005.
  22. Pogrel MA, Podlesh S, Anthony JP et al. (1989). A comparison of vascularized and non-vascularized bone grafts for reconstruction of mandibular continuity defects. J Oral Maxillofac Surg. 55:1200-1206.
  23. Hariram, Shadab Mohammad, Laxman R. Malkunje, Nimisha Singh, Sugata Das, Gagan Mehta. (2014). Ameloblastoma of the anterior mandible. National Journal of Maxillofacial Surgery. 5(1).
  24. X. F. Sha, J. Liang, L. Zhang, Z. G. Cai. Mandibular defects reconstruction with fibula flap and free fibula bone graft. International Journal of Oral & maxillofacial surgery. 46(S1); 191.
  25. Adebisi, K. E., Ugboko, V. I., Omoniyi-Esan, G. O., Ndukwe, K. C., & Oginni, F. O. (2006). Clinicopathological analysis of histological variants of ameloblastoma in a suburban Nigerian population. Head & Face Medicine. 2(1), 42.
  26. Aggerholm-Pedersen, N., Mæretty-Nielsen, K., Keller, J., Baerentzen, S., Schrøder, H., Jørgensen, P. H., Safwat, A. (2015). The importance of standardized treatment in high-grade osteosarcoma: 30 years of experience from a hospital-based database. Acta Oncologica. 54(1), 17-24.
  27. Bailey, B. J. (2001). Atlas of head & neck surgery--otolaryngology. Lippincott Williams & Wilkins.
  28. Emmanuel Pantaleon Estrella, Edward H. M. Wang (2016). A Comparison of Vascularized Free Fibular Flaps and Nonvascularized Fibular Grafts for Reconstruction of Long Bone Defects after Tumor Resection. Journal of Reconstructive microsurgery.



This work is licensed under Creative Commons Attribution 4.0 License

To Submit Your Article Click Here: [Submit Manuscript](#)

DOI: [10.31579/2768-2757/020](https://doi.org/10.31579/2768-2757/020)

#### Ready to submit your research? Choose Auctores and benefit from:

- ❖ fast, convenient online submission
- ❖ rigorous peer review by experienced research in your field
- ❖ rapid publication on acceptance
- ❖ authors retain copyrights
- ❖ unique DOI for all articles
- ❖ immediate, unrestricted online access

At Auctores, research is always in progress.

Learn more [auctoresonline.org/journals/journal-of-clinical-surgery-and-research](http://auctoresonline.org/journals/journal-of-clinical-surgery-and-research)