

Spontaneous closure of Stage II Idiopathic Macular Hole

Ayşe Gul Kocak ALTINTAS *

Sağlık Bilimleri University Ulucanlar Eye Hospital Ankara Turkey.

Corresponding Author: Ayşe Gul Kocak ALTINTAS, Sağlık Bilimleri University Ulucanlar Eye Hospital Ankara Turkey.

Received date: July 07, 2021; **Accepted date:** August 12, 2021; **Published date:** August 25, 2021

Citation: Ayşe Gul Kocak ALTINTAS, (2021). Spontaneous closure of Stage II Idiopathic Macular Hole. *Experimental and Clinical Ophthalmology*. 1(1). DOI: 10.31579/eco.2021/002

Copyright: © 2021 Ayşe Gul Kocak ALTINTAS. This is an open access article distributed under the Creative Commons Attribution License, which permits unrestricted use, distribution, and reproduction in any medium, provided the original work is properly cited.

Abstract:

A 70-year-old man had stage II Idiopathic Macular Hole, complained of a decrease in vision, and have metamorphopsia was presented. Oct examination revealed incomplete posterior vitreous detachment (PVD) with persistent antero posterior traction on the small part of the superior edge of the MH in upper scans of horizontal sections. Spontaneous closure of IMH following complete PVD and decreased macular edema combine with the recovery of the foveal structure observed by OCT.

Key Words: idiopathic macular hole; vision; metamorphopsia; neurosensory retina; choroidal neovascularization; fundoscopic; foveal pseudocyst

Introduction:

A macular hole (MH) is a partial or complete defect of the neurosensory retina in the foveal center. MH may develop secondary to trauma, retinal detachment, choroidal neovascularization, macular edema, or submacular hemorrhage but the most common type of MH is the idiopathic macular holes (IMH). The formation of an IMH has been attributed to either antero-posterior or tangential traction exerting on the fovea. A full-thickness defect of retinal in the MH can cause a significant decrease in visual acuity and visual distortion [1-5].

Pars plana vitrectomy is still accepted as a primary and effective treatment option for idiopathic full-thickness MH. [6,7] However, spontaneous closure of early stage of IMH's with good visual acuity progression in several case reports has been published in recent years. But the spontaneous closure of stage II and more advanced stage IMH is extremely rare in the literature. The mechanism and the characteristics for spontaneous closure of idiopathic full-thickness macular holes and the risk factors are not still fully explicated [8-12].

In this case report, we presented a case that a spontaneous closure of stage II IMH after the separation of vitreoretinal traction and recovery of the foveal anatomic structures.

Case Report:

A 70-year-old man was referred to our retina clinic with a complaint of decreased vision and visual distortion in his right eye. He did not have any trauma, and his medical history was unremarkable. The Best-corrected visual acuity was finger counting from 5 meters in the right eye and 0.6 in the left eye mild nuclear sclerosis were observed in both eyes in anterior segment examination. Posterior segment evaluation was done by fundoscopic and optical coherence tomography (OCT) examination. OCT of the macula showed full-thickness IMH with loss of both neurosensory retina and retinal pigment epithelium (RPE) combined with separation of perifoveal posterior vitreous on both center of the macula and inferior edge of the macular hole. But incomplete posterior vitreous detachment (PVD) with persistent antero-posterior vitreous traction on the small part of the superior edge of the MH was seen in upper scans, of horizontal sections in OCT. (Figure 1)

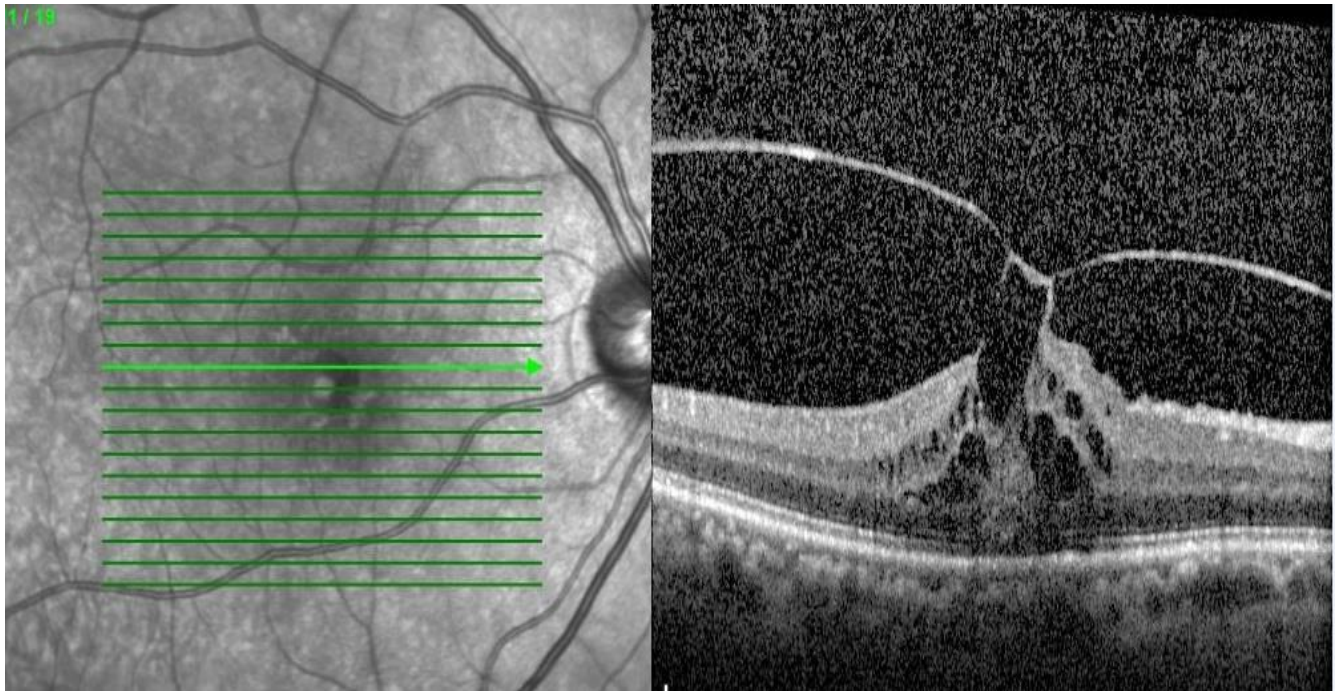


Figure 1. Incomplete posterior vitreous detachment (PVD) with persistent vitreous traction on superior edge of the Stage II IMH seen in upper scans, of horizontal sections of OCT.

The both nasal and temporal edges of the macular hole were sharp and stretch out bridge-like structure. Basal diameter of MH was 590 μ , the

minimum diameter was 250 μ , and the upper diameter was 410 μ . This OCT revealed a stage II. Full-thickness IMH. (Figure 2)

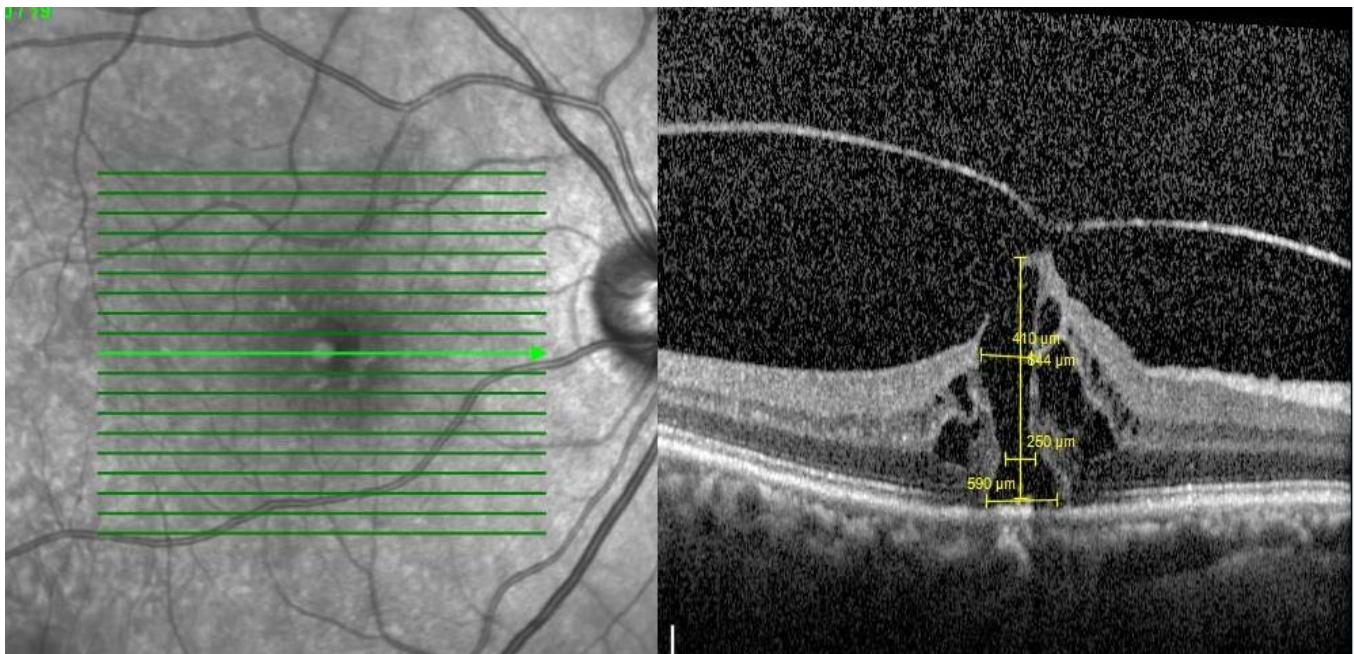


Figure 2. Stage II full-thickness macular hole with sharp and stretch out edges combine with separation of perifoveal posterior vitreous on center of the macula

For treatment of IMH, pars plana vitrectomy was recommended to relieve posterior vitreous traction on the edge of MH. During the preparation for surgery two weeks later, his visual acuity increased to 0.2, and visual distortion was decreased. A complete PVD with the release of foveal vitreomacular traction combined with spontaneous closure of IMH

and restoration of external limiting membrane (ELM) was observed on OCT examination. But outer retinal changes, including interruption of the foveal photoreceptor ellipsoid zone (EZ) and retina pigment epithelium combined with a small pseudocyst of the macula were seen in the same OCT scans. (Figure 3)

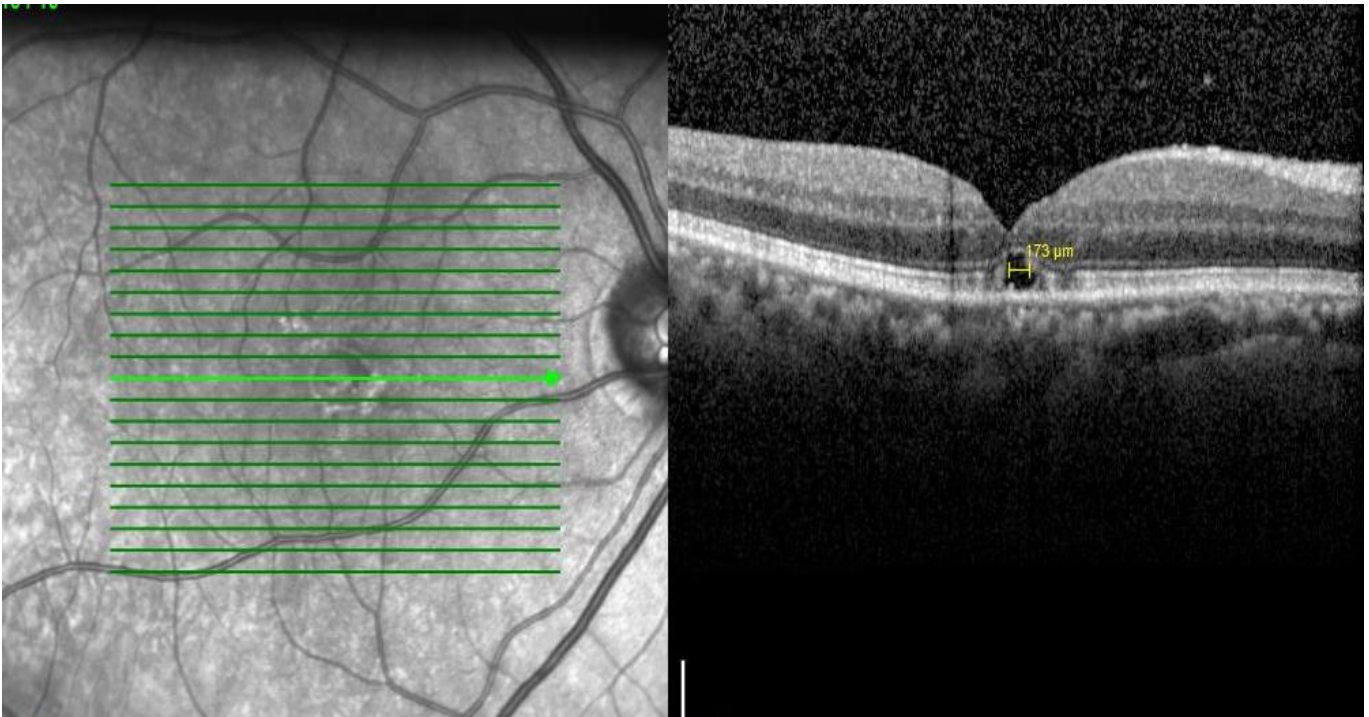


Figure 3. Complete PVD with the release of foveal vitreomacular traction combined with spontaneous closure of IMH

At subsequent visits, progressively decrement in the size of pseudocyst and improvement in EZ changes were observed. (Figure 4. a,b,c,d).

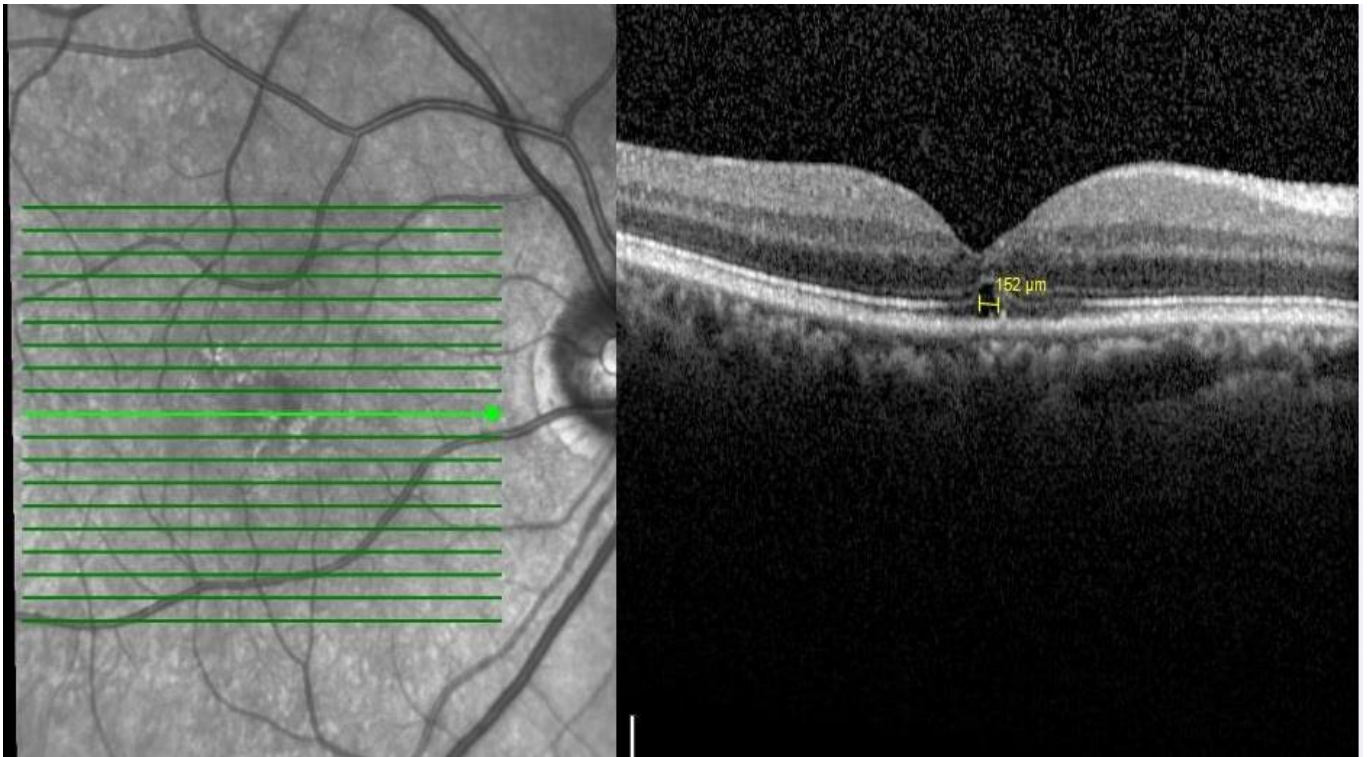


Figure 4a. Four months after the spontaneous closure of Stage II IMH

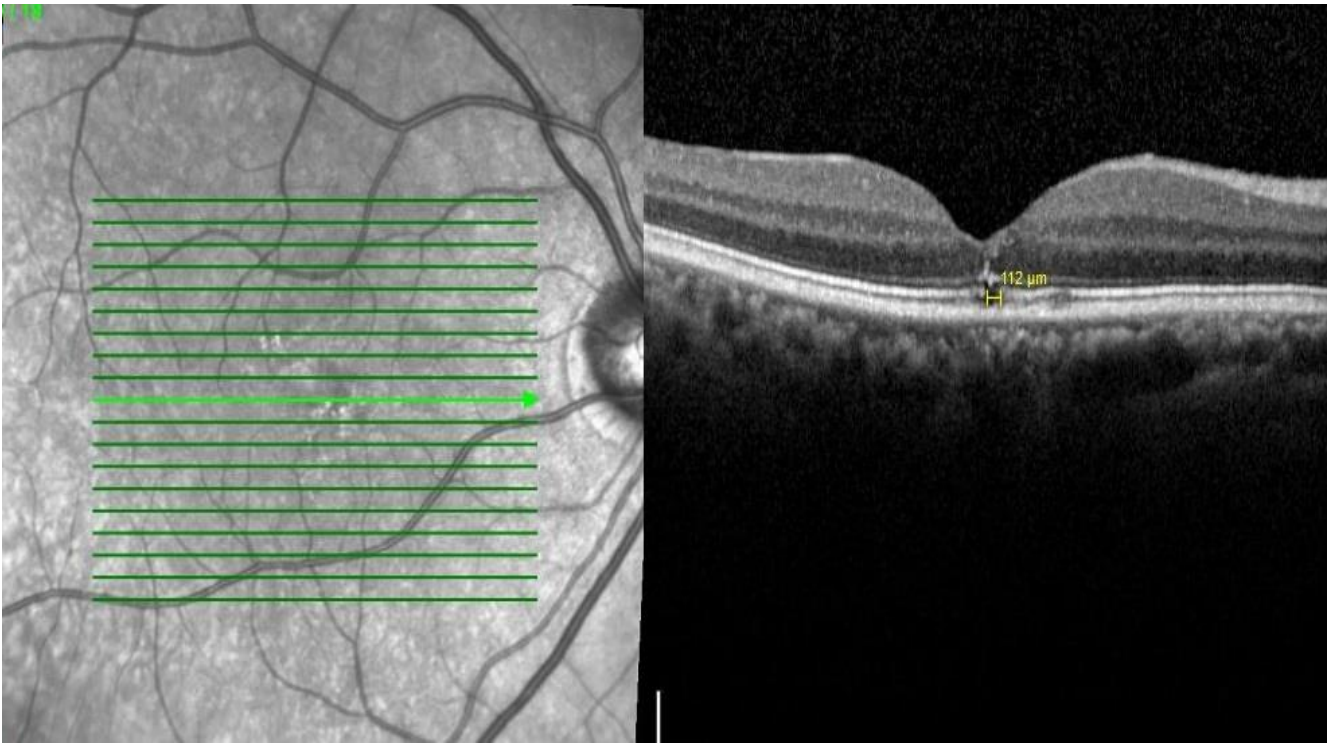


Figure 4b. Eight months after the spontaneous closure of Stage II IMH

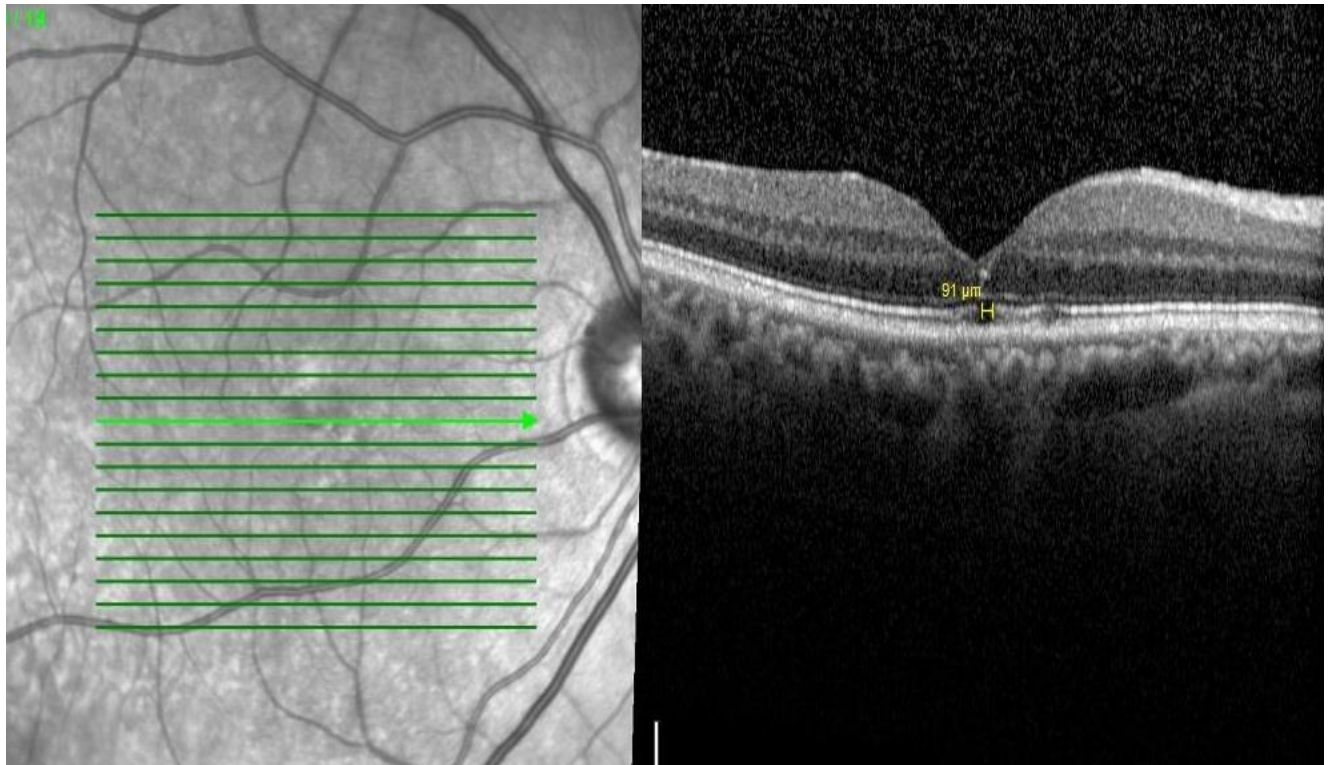


Figure 4c. One and a half years after the after the spontaneous closure of Stage II IMH

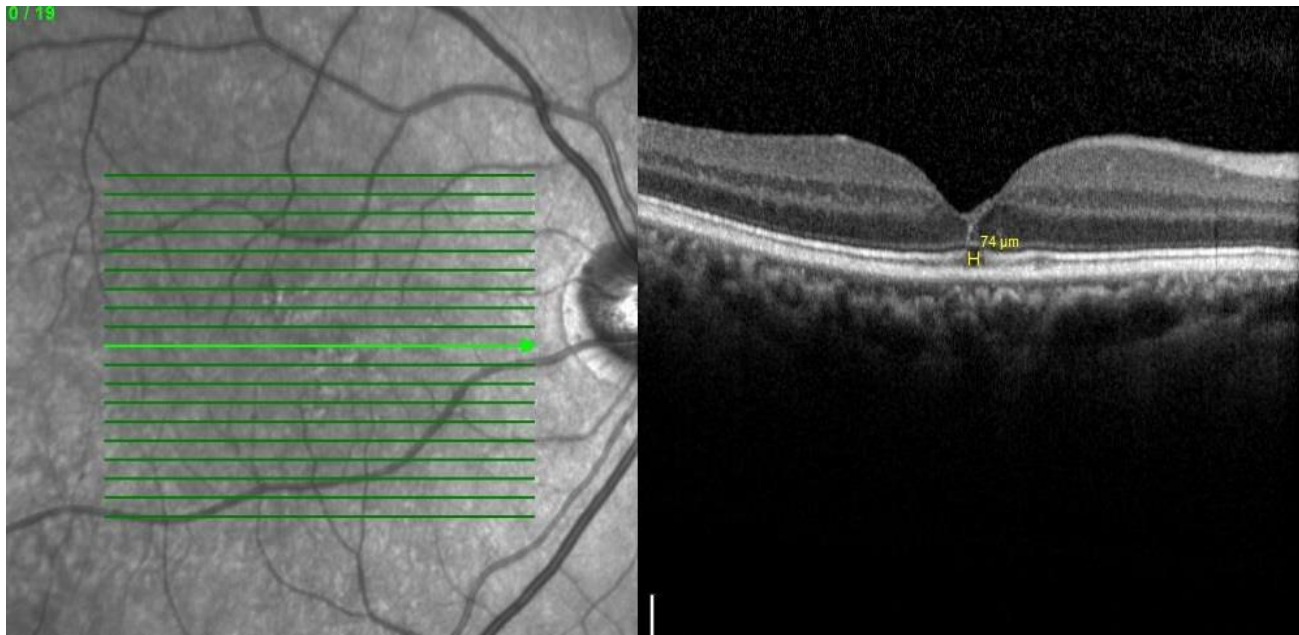


Figure 4d. Two years after the after the spontaneous closure of Stage II IMH

Figure 4(a,b,c,d). Progressive resorbption of pseudocyst with decreasing in horizontal cyst diameter.

Best-corrected visual acuity increased to 0.4 during the follow up period. Two years after the spontaneous closure of MH, prominent resolution of the foveal pseudocyst combined with significantly resolved residual EZ disorganization and small persistent defect on the retina pigment epithelium were observed. No reopening of macular hole or any other degenerative changes occurred during the follow-up period.

Discussion:

The spontaneous closure of IMH is very rare, and its incidence varies from reported in 0 to 11.5% [1,5,13,14]. Okubo et al. [5] reported five eyes (3.5%) with spontaneous closure of full-thickness IMHs of 142 eyes. In Freeman et al.'s [6] multi-centered, controlled, randomized clinical trial, 2 (4%) eyes showed spontaneously closed IMH out of 56 eyes. [2,7] Yuzawa et al. [1] observed spontaneous closure in 6 eyes (6.2%) of 97 eyes. In Ezra et al. [7] series, spontaneous closure of the IMH occurred in 7 (11.5%) of 61 eyes.

Liang and Liu [10] reviewed the Pub Med database articles from 1999 to 2018 about the spontaneous closure of IMH. They found the spontaneous closure in stage I was seen in 41 eyes, in 21 eyes with stage II, in 13 eyes of stage III, and seven eyes in stage IV IMHs in the literature. The chance of spontaneous closure of IMH has correlated with the stage of IMH; the more advance stage of IMH, the less opportunity to closure. The most spontaneous closure of IMH was published as a case report similar to our case.

The exact mechanisms for the spontaneous closure of IMH are not well understood, but several hypotheses have been described. Complete posterior vitreo-retinal separation causes relief antero-posterior traction on the edge of the macular hole and results in flattening of the elevated foveal tissue in the MH. Flattening of the MH edges allows retina pigment epithelial (RPE) migrations into the inner retinal surface, combined with the bridging effect of retinal tissue by glial cell and Müller cells proliferation across the hole, facilitate spontaneous closure of IMH. Besides, collagen secretion by retinal cells and their contraction circumferentially pulls the separated MH edges centripetally may cause

the spontaneous closure. However, other unknown cellular reactions like inflammation maybe effect these histological changes. (5,9,13,14)

In our patient, the development of total PVD and release of anteroposterior vitreous traction on the edge of the macular hole initiated the formation of the spontaneous closure of Stage II macular hole. During the follow up period, continuity of external limiting membrane and regeneration of the outer nuclear layers of fovea were observed. But even with a significant EZ restoration, minimal interruption of RPE in the small pseudocyst was persisted.

Freund et al. [12] reported spontaneous closure of stage II IMH without complete posterior vitreous detachment similar to Kelkar et al [13] report. [9, 29] Morawski et al. [14] observed that IMH spontaneously closed in 5 out of 9 eyes without the relief of VMT. These reports showed that the release of VMT could initiate the spontaneous closure of IMHs, but it may not be the essential mechanism.

Spontaneous macular hole closures were reported on both stage III and stage IV IMHs in several reports. Total PVD had already developed and antero-posterior traction was relieved, therefore the mechanism of spontaneous closure may be more complicated [14,15]. Privat et al. [16] observed spontaneous closure of 6 eyes with stage III or IV MHs. Sugiyama et al. [17] published similar cases in which posterior vitreous already separated from the MH edge.

The exact pathogenesis of IMH closure remains incompletely understood and several mechanisms have been reported [18-21]. Morawski et al. [14], similar to Michalewska et al. [2,18], suggested that when the edges of macular holes become sharp and stretch out bridge-like structure, this "bridging" phenomenon is the main mechanism of spontaneous closure of IMHO .

In presenting case, sharp edges on the MH in the initial stage and rapid regeneration of ELM after release of VMT were observed. Intact ELM may give structural stability in the central outer retinal layers, and bridges that effect the holes may facilitate the spontaneous closure of stage II IMH.

The diameter of MHs may be another factor for the spontaneous closure. Privat et al. [16] suggested that MH with less than 250 μ m diameter have more prone to close spontaneously. The smaller diameter of IMHs has

more chance that both edges to combine together. Fernández and Navarro [20] reported that IMHs with a minimum diameter of IMH smaller than basal diameter have more opportunity to close spontaneously. We observed that basal diameter was much larger than the upper diameter of small IMH in presenting the case.

Conclusion

We observed the release of VMT, sharp edges on the MH, the bridge-like structure, and the small size of hole diameter in presenting a case with spontaneously closed stage II IMH. All of these factors are important during the spontaneously closure process of IMHs. Still, none of them is unique, and each hypothesis needs to be confirmed by both histopathologic examination and OCT evaluation studies with more sample numbers.

References

1. Yuzawa M, Watanabe A, Takahashi Y, Matsui M. (1994). Observation of idiopathic full-thickness macular holes. Follow-up observation. *Arch Ophthalmol.* 1994;112:1051–1056.
2. Michalewska Z, Michalewski J, Sikorski BL, et al. (2009). A study of macular hole formation by serial spectral optical coherence tomography. *Clin Experiment Ophthalmol* 2009;37:373-383.
3. Lee YJ, Kim M. (2019). Macular hole formation after intravitreal injection of bevacizumab for diabetic macular edema. *Korean J Ophthalmol.* 2019;33:198–199.
4. Cohen, Michael N. MD; Baumal, Caroline R. MD. (2021). Macular hole formation followed by spontaneous closure after pneumatic retinopexy in a patient with diabetic macular edema *Retinal Cases & Brief Reports: Winter 2021; 15 (1):24-26.*
5. Okubo A, Unoki K, Yamaki K, Sameshima M, Sakamoto T. (2013). "Early structural changes during spontaneous closure of idiopathic full-thickness macular hole determined by optical coherence tomography: a case report," *BMC Research Notes*, 2013; 6(1): 396.
6. Freeman WR, Azen SP, Kim JW, el-Haig W, Mishell D R, Bailey I. (1997). "Vitrectomy for the treatment of full-thickness stage 3 or 4 macular holes: results of a multicentered randomized clinical trial. The vitrectomy for treatment of macular hole study group," *Archives of Ophthalmology*, 1997; 115(1):11-12.
7. Ezra E, Gregor ZJ, Moorfields. (2004). Macular Hole Study Group. "Surgery for idiopathic full-thickness macular hole: two-year results of a randomized clinical trial comparing natural history, vitrectomy, and vitrectomy plus autologous serum: Moorfields macular hole study group report no. 1," *Archives of Ophthalmology*, 2004; 122(2): 224–236.
8. Schweitzer KD, García R. (2007). Spontaneous closure of a stage III idiopathic macular hole. *Can J Ophthalmol.* 2007, 42: 127-128.
9. Imasawa M, Chiba T, Iijima H. (2010). "Spontaneous closure of idiopathic full-thickness macular holes in both eyes," *Japanese Journal of Ophthalmology.* 2010; 54(5): 507–509.
10. Liang X, Liu W. (2019). Characteristics and Risk Factors for Spontaneous Closure of Idiopathic Full-Thickness Macular Hole Review Article *J Ophthalmol.* 2019; 2019: 4793764.
11. Zvornicanin J, Zvornicanin E, Musanovic Z. (2017). "Spontaneous closure of a full-thickness macular hole," *Acta Medica Academica* 2017; 46 (2): 171-172.
12. Freund KB, Ciardella AP, Shah V et al. (2002). "Optical coherence tomography documentation of spontaneous macular hole closure without posterior vitreous detachment," *Retina*, 2002; 22 (4): 506–515.
13. Kelkar AS, Bhanushali DR, Kelkar JA, Shah RB, Kelkar SB. (2013). "Spontaneous closure of a full-thickness stage 2 idiopathic macular hole without posterior vitreous detachment," *Case Reports in Ophthalmology*, 2013;4 (3): 188–191.
14. Morawski K, Jędrzychowska-Jamborska J, Kubicka-Trzaska A, Romanowska-Dixon B. (2016). "The analysis of spontaneous closure mechanisms and regeneration of retinal layers of a full-thickness macular hole," *Retina*, 2016; 36 (11): 2132–2139.
15. Krzysztof M, Justyna JJ, Agnieszka KT, Bożena RD. (2016). The analysis of spontaneous closure mechanisms and regeneration of retinal layers of a full-thickness macular hole. *Retina*, 2016; 36(11):2132-2139.
16. Privat E, Tadayoni R, Gaucher D, Haouchine B, Massin P, Gaudric A. (2007). Residual defect in the foveal photoreceptor layer detected by optical coherence tomography in eyes with spontaneously closed macular holes. *Am J Ophthalmol.* 2007; 143:814–819.
17. Sugiyama A, Imasawa M, Chiba T, Iijima H. (2012). Reappraisal of Spontaneous Closure Rate of Idiopathic Full-Thickness Macular Holes. *Open Ophthalmol J.* 2012; 6: 73–74.
18. Michalewska Z, Cisiecki S, Sikorski B et al. (2008). "Spontaneous closure of stage III and IV idiopathic full-thickness macular holes—a two-case report," *Graefe's Archive for Clinical and Experimental Ophthalmology*, 2008; 246(1): 99–104.
19. Altintas AGK. (2021). Spontaneous closure of macular hole following the separation of vitreomacular traction. *J Ophthalmol Adv Res.* 2021; 2(1):1-7.
20. Fernández MG, Navarro JC. (2012). "Spontaneous closure of stage IV idiopathic full-thickness macular hole and late reopening as a lamellar macular hole: a case report," *Journal of Medical Case Reports*, 2012; 6(1): 169.
21. Bringmann A, Unterlauff JD, Wiedemann R, Barth T, Rehak M, Wiedemann P. (2020). Two different populations of Müller cells stabilize the structure of the fovea: an optical coherence tomography study. *Int Ophthalmol.* 2020; 40(11): 2931–2948.



This work is licensed under Creative Commons Attribution 4.0 License

To Submit Your Article Click Here: [Submit Manuscript](#)

DOI: [10.31579/eco.2021/002](https://doi.org/10.31579/eco.2021/002)

Ready to submit your research? Choose Auctores and benefit from:

- ❖ fast, convenient online submission
- ❖ rigorous peer review by experienced research in your field
- ❖ rapid publication on acceptance
- ❖ authors retain copyrights
- ❖ unique DOI for all articles
- ❖ immediate, unrestricted online access

At Auctores, research is always in progress.

Learn more www.auctoresonline.org/journals/experimental-and-clinical-ophthalmology