

The Thirty Fourth and Thirty Fifth Cases of Goldberg Shprintzen Syndrome

Aamir Jalal Al-Mosawi

1Advisor in Pediatrics and Pediatric Psychiatry, Children Teaching Hospital of Baghdad Medical City

2Head, Iraq Headquarter of Copernicus Scientists International Panel, Baghdad, Iraq

***Corresponding author:** Aamir Jalal Al-Mosawi, Head, Iraq Headquarter of Copernicus Scientists International Panel, Baghdad, Iraq.

Received date: January 30 2020; **Accepted date:** February 14, 2020; **published date:** February 18, 2020

Citation: Aamir Jalal Al-Mosawi (2020) The Thirty Fourth and Thirty Fifth Cases of Goldberg Shprintzen Syndrome. J Clinical Research and Reports, 3(1); DOI:10.31579/2690-1919/031

Copyright: © 2020 Aamir Jalal Al-Mosawi. This is an open access article distributed under the Creative Commons Attribution License, which permits unrestricted use, distribution, and reproduction in any medium, provided the original work is properly cited.

Abstract

Goldberg Shprintzen syndrome is an autosomal recessive mental and growth retardation syndrome associated with distinctive facial dysmorphism, Hirschsprung disease, and a variety of neurologic abnormalities, and abnormalities on brain imaging studies.

Thirty three cases of Goldberg Shprintzen syndrome was reported from many countries (Canada, Pakistan, Japan, United Kingdom, Morocco, The Netherlands, Italy, Israel, France, Iran) including 2 patients reported by Goldberg and Shprintzen (1981), one patient reported by Brunoni et al (1983), two patients reported by Hurst et al (1988), two patients reported by Kumasaka and Clarren (1988), one patient reported by Halal and Morel (1990), two patients reported by Yomo, Taira, and Kondo (1991), one patient reported by Tanaka et al (1993), one patient reported by Ohnuma et al (1997), two patients reported by Fryer AE (1998), four patients reported by Brooks et al (1999), One patient reported by Imaizumi (2001), one patient reported by Silengo et al (2003), two patients reported by Shahar and Shinawi (2003), two patients reported by Brooks et al (2005), two patients reported by Murphy et al (2006), five patients reported by Drévillon, Megarbane, and Demeer (2013), one patient reported by Dafsari et al (2015), and one patient reported by Salehpour et al (2017).

The aim of this paper is to report the thirty fourth and thirty fifth cases of the syndrome which occurred in Iraqi brother and was associated with right hemiplegia in one patient.

Keywords: goldberg-shprintzen syndrome; brain abnormalities; hemiplegia; iraq

Introduction

Goldberg Shprintzen syndrome is an autosomal recessive mental and growth retardation syndrome associated with distinctive facial dysmorphism, Hirschsprung disease, and a variety of neurologic abnormalities, and abnormalities on brain imaging studies. The syndrome was first described by Goldberg and Shprintzen in 1981, who described a brother and sister with mental and growth retardation, hypertelorism, submucous cleft palate, and Hirschsprung aganglionic megacolon [1].

Thirty three cases of Goldberg Shprintzen syndrome was reported from many countries (Canada, Pakistan, Japan, United Kingdom, Morocco, The Netherlands, Italy, Israel, France, Iran) including 2 patients reported by Goldberg and Shprintzen (1981), one patient reported by Brunoni et al (1983), two patients reported by Hurst et al (1988), two patients reported by Kumasaka and Clarren (1988), one patient reported by Halal and Morel (1990), two patients reported by Yomo, Taira, and Kondo (1991), one patient reported by Tanaka et al (1993), one patient reported by Ohnuma et al (1997), two patients reported by Fryer AE (1998), four patients reported by Brooks et al (1999), One patient reported by Imaizumi (2001), one patient reported by Silengo et al (2003), two patients reported by Shahar and Shinawi (2003), two patients reported by Brooks et al (2005), two patients reported by Murphy et al (2006), five patients reported by Drévillon, Megarbane, and Demeer (2013), one

patient reported by Dafsari et al (2015), and one patient reported by Salehpour et al (2017).

The aim of this paper is to report the thirty fourth and thirty fifth cases of the syndrome which occurred in Iraqi brother and was associated with right hemiplegia in one patient.

Case report

T.A.S was first seen at the age of four years and 10 months at the pediatric neuro-psychiatric clinic on the 29th of August, 2019, because of weakness of the right side of his body and inability to walk alone. He was also not saying any word and had distinctive facial features characterized by hypertelorism, narrow palpebral fissures, open mouth, and laterally lifted ear (Figure-1). He also had submucous cleft palate.

The boy had spastic right hemiparesis and was unable to walk alone, but he could stand momentarily unaided and was walking holding the wall and furniture (Figure-2). The boy had impaired fine motor skills and was unable to feed self with spoon nor drink with a cup appropriately.

The boy didn't have clear history of birth asphyxia nor CNS injury or infection during infancy that can be blamed for the right hemiplegia. However, he had neonatal intestinal obstruction attributed to Hirschsprung disease and was treated by surgical resection and colostomy at about one month of age.

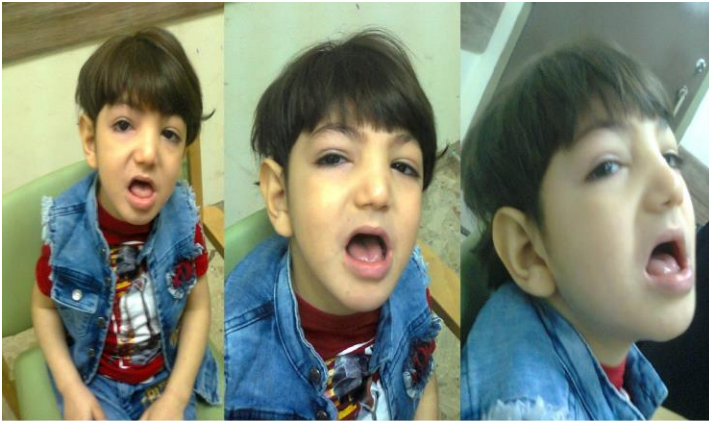

Figure-1: The boy had distinctive facial features characterized by hypertelorism, open mouth, and laterally ear



Figure-2: The boy was unable to walk alone, but he could stand momentarily unaided and walk holding the wall and furniture

The parents were healthy cousins who had three children; a 17-year girl and a six-year boy were both healthy, but a 14-year old boy was mentally retarded and disabled. The boy was not available for examination, but a photo of him (Figure-3) with the patient confirmed that the brothers had the same syndrome.

Brain MRI showed some atrophic changes at the left parietal region.




Figure-3: The two Iraqi brothers with Goldberg Shprintzen syndrome

Discussion

In 1981, Goldberg and Shprintzen described siblings with mental and growth retardation, distinctive facial dysmorphism, short-segment Hirschsprung disease, and cleft palate.

Brunoni et al (1983) reported the occurrence of Goldberg and Shprintzen syndrome in association with cleft lip and palate, and other minor congenital malformations [2].

Hurst et al (1988) reported the occurrence of Goldberg and Shprintzen syndrome in association with iris coloboma and defective neuronal migration. They described a consanguineous Pakistani pedigree in which two boys in separate sibships had Hirschsprung disease and microcephaly. One had iris coloboma and the other did not [3].

Kumasaka and Clarren (1988) reported the familial occurrence of the syndrome in association with central nervous system dysfunction [4].

Halal and Morel (1990) from Canada reported a boy with Hirschsprung megacolon associated with microcephaly, narrow palpebral fissures, broad nasal bridge, congenital heart defect, cryptorchidism, wide-base gait, short stature, developmental delay and abnormal computed tomography (CT) brain scan [5].

Yomo, Taira, and Kondo (1991) from Japan reported the ninth and tenth cases of Goldberg Shprintzen syndrome in a brother and sister with who had Hirschsprung disease, hypotonia, and ptosis. They emphasized that the condition is a distinct autosomal recessive syndrome [6].

Tanaka et al (1993) from Japan reported a 5-year-old girl with Goldberg-Shprintzen syndrome who had Hirschsprung disease, distinctive facial dysmorphism, psychomotor retardation, epilepsy, and congenital heart disease. Brain computed tomography showed evidence of defective neuronal migration and/or dysgenesis of the brain [7].

Fryer AE (1998) from the United Kingdom reported a family with Goldberg-Shprintzen syndrome, and emphasized the intra-familial variability associated with syndrome [9].

Brooks et al (1999) from the Netherlands reported four children with Goldberg-Shprintzen syndrome. Three of them from a large, consanguineous, Moroccan family had Hirschsprung disease, mental retardation, microcephaly, and distinctive craniofacial dysmorphism. The fourth child showed similar clinical features, with the exception of Hirschsprung disease [10].

Silengo et al (2003) reported an Italian infant with Goldberg-Shprintzen syndrome who had short-segment Hirschsprung disease, and brain abnormalities including pachygyria and cerebellar hypoplasia. The patient had the distinctive dysmorphic facial features of the syndrome including hypertelorism, depressed nasal bridge, bulbous nose, and full lips. Other features the patient had included pale optic discs with poor fixation and abnormal EEG. Brain MRI showed pachygyria, hypoplasia of the corpus callosum, and cerebellar hypoplasia. The girl showed severely delayed psychomotor development at age four months. Silengo et al thought that a defect in neuronal crest cell migration and in neuronal migration is associated with syndrome [12].

Shahar and Shinawi (2003) from Israel thought that Goldberg Shprintzen syndrome is the result of a neurocristopathy resulting from defective growth, differentiation, and migration of the neural crest cells. They

emphasized that Hirschsprung disease is the result of defective migration of neural crest cells on to the colonic submucosa and is also considered a neurocristopathy. They reported two children with Goldberg Shprintzen syndrome associated with Hirschsprung disease and a wide spectrum of neurologic abnormalities including agenesis of the corpus callosum and cortical malformations associated with intractable seizures in one child [13].

Brooks et al (2005) described a family with Hirschsprung disease as a variable feature and bilateral generalized polymicrogyria malformation of the cerebral cortex characterized by an increased number of smaller convolutions or gyri and disruption of the normal 6-layered cerebral cortical structure as a constant feature [14].

Murphy et al (2006) from the united Kingdom reported two brothers from a non-consanguineous family who have classical features of Goldberg-Shprintzen syndrome. The novel findings in this report were foot anomalies including camptodactyly and clinodactyly of the 2nd to 4th toes [15].

Drévilion , Megarbane , and Demeer (2013) from France reported five new patients with Goldberg-Shprintzen syndrome from three unrelated consanguineous families families[16]. All patients had moderate to severe psychomotor retardation, microcephaly, poor or absent language development, and hypotonia. Four patients had Hirschsprung disease, and one had constipation. Dysmorphic facial features included sparse hair, arched eyebrows, long eyelashes, ptosis, downslanting palpebral fissures, prominent ears, thick earlobes, prominent nasal bridge, thick philtrum, everted lower lip, and pointed chin. Variable brain abnormalities was observed in the patients and included polymicrogyria, gyral anomalies, corpus callosum hypoplasia, and enlargement of the subarachnoid space, were also present. Other abnormalities included congenital heart disease (2 patients), urogenital abnormalities (2 patients), oligodontia (1 patient), and scoliosis (1 patient). Drevillon et al (2013) thought that the phenotype of the syndrome is caused by defects in development of both the enteric and central nervous systems.

Dafsari et al (2015) from the United Kingdom reported a 7-year-old girl with Goldberg-Shprintzen syndrome caused by a homozygous deletion of exons 5 and 6 of the KIAA1279 gene and evidence of axonal sensory motor neuropathy. The girl had motor developmental delay, hypotonia, ptosis and absent reflexes [17].

Salehpour et al (2017) from Iran reported a 16-year boy with Goldberg Shprintzen syndrome and refractory seizures. The boy had a novel nonsense (stop gain) homozygous mutation in KIAA1279 gene (KIAA1279: NM_015634: exon6:c. C976T: p.Q326X) [18].

In this paper, the thirty fourth and thirty fifth cases of the syndrome which occurred in Iraqi brother was reported, and one of the patients was described in details. Brain MRI of one of the patients who had hemiplegia showed some atrophic changes at the left parietal region. The neurologic and brain abnormalities in this patient has not been reported before in association with this syndrome.

Acknowledgement

The author would like to express his gratitude for the parents who accepted the publication of the photos of their children.

References

1. Goldberg RB, Shprintzen RJ. Hirschsprung megacolon and cleft palate in two sibs. *J Craniofac Genet Dev Biol* 1981;1:185-189.
2. Brunoni D, Joffe R, Farah LMS, et al. Hirschsprung megacolon, cleft lip and palate, mental retardation, and minor congenital malformations. *J Clin Dysmorphol* 1983;1:20-2.
3. Hurst JA, Markiewicz M, Kumar D, Brett EM. Unknown syndrome: Hirschsprung's disease, microcephaly, and iris coloboma: a new syndrome of defective neuronal migration. *J Med Genet* 1988;25:494-7.
4. Kumasaka K, Clarren SK. Familial patterns of central nervous system dysfunction, growth deficiency, facial clefts and congenital megacolon: a specific disorder? *Am J Med Genet* 1988;31:465-466.
5. Halal F, Morel J. The syndrome of Hirschsprung disease, microcephaly, unusual face, and mental retardation. *Am J Med Genet* 1990 Sep;37(1):106-8.
6. Yomo A, Taira T, Kondo I. Goldberg-Shprintzen syndrome: Hirschsprung disease, hypotonia, and ptosis in sibs. *Am J Med Genet* 1991 Nov 1;41(2):188-91.
7. Tanaka H, Ito J, Cho K, Mikawa M. Hirschsprung disease, unusual face, mental retardation, epilepsy, and congenital heart disease: Goldberg-Shprintzen syndrome. *Pediatr Neurol* 1993 Nov-Dec;9(6):479-481.
8. Ohnuma K, Imaizumi K, Masuno M, Nakamura M, Kuroki Y. Magnetic resonance imaging abnormalities of the brain in Goldberg-Shprintzen syndrome (Hirschsprung disease, microcephaly, and iris coloboma). *Am J Med Genet* 1997 Dec 12;73(2):230-232.
9. Fryer AE. Goldberg-Shprintzen syndrome: report of a new family and review of the literature. *Clin Dysmorphol* 1998 Apr;7(2):97-101.
10. Brooks AS , Breuning MH, Osinga J, vd Smagt JJ, Catsman CE, Buys CH, Meijers C, Hofstra RM. A consanguineous family with Hirschsprung disease, microcephaly, and mental retardation (Goldberg-Shprintzen syndrome). *J Med Genet* 1999 Jun;36(6):485-489.
11. Imaizumi K. Goldberg-Shprintzen syndrome. *Ryoikibetsu Shokogun Shirizu* 2001; (33): 761-762.
12. Silengo M, Ferrero GB, Tornetta L, Cortese MG, Canavese F, D'Alonzo G, Papalia F. Pachygyria and cerebellar hypoplasia in Goldberg-Shprintzen syndrome. *Am J Med Genet A* 2003 May 1;118A(4):388-390.
13. Shahar E, Shinawi M. Neurocristopathies presenting with neurologic abnormalities associated with Hirschsprung's disease. *Pediatr Neurol* 2003 May;28(5):385-391.
14. Brooks, AS, Bertoli-Avella, AM, Burzynski, GM, et al. Homozygous nonsense mutations in KIAA1279 are associated with malformations of the central and enteric nervous systems. *Am. J. Hum. Genet.* 77: 120-126, 2005.
15. Murphy HR, Carver MJ, Brooks AS, Kenny SE, Ellis IH. Two brothers with Goldberg-Shprintzen syndrome. *Clin Dysmorphol* 2006 Jul;15(3):165-169.
16. Drévilion L, Megarbane A, Demeer B. KBP-cytoskeleton interactions underlie developmental anomalies in Goldberg-Shprintzen syndrome. *Hum Mol Genet* 2013 Jun 15;22(12):2387-99.
17. Dafsari HS, Byrne S, Lin JP, Pitt M, Jongbloed JD, Flinter F, Jungbluth H. Goldberg-Shprintzen megacolon syndrome with associated sensory motor axonal neuropathy. *Am J Med Genet A* 2015 Jun;167(6):1300-1304.

18. Salehpour S, Hashemi-Gorji F, Soltani Z, Ghafouri-Fard S, Miryounesi M. Association of a Novel Nonsense Mutation in

KIAA1279 with Goldberg-Shprintzen Syndrome. Iran J Child Neurol. 2017 Winter;11(1):70-74.



This work is licensed under Creative Commons Attribution 4.0 License

To Submit Your Article Click Here: [Submit Manuscript](#)

DOI: [10.31579/2690-1919/031](https://doi.org/10.31579/2690-1919/031)

Ready to submit your research? Choose Auctores and benefit from:

- ❖ fast, convenient online submission
- ❖ rigorous peer review by experienced research in your field
- ❖ rapid publication on acceptance
- ❖ authors retain copyrights
- ❖ unique DOI for all articles
- ❖ immediate, unrestricted online access

At Auctores, research is always in progress.

Learn more www.auctoresonline.org/journals/journal-of-clinical-research-and-reports