

Anterior Cervical Discectomy And Fusion Versus Dynamic Cervical Implant – Arthroplasty For Treatment Of Cervical Degenerative Disc Disease: A Prospective Comparative Study

¹Mohamed Othman, Saied A Issa ², Walid Feisal Elsharkawi

¹Faculty of medicine, Department of Orthopedic Surgery, Zagazig University, Egypt

²Faculty of medicine, Neurosurgery Department, Helwan University, Egypt

³Faculty of medicine, Department of Orthopedic Surgery, Zagazig University, Egypt

*Corresponding Author : Mohamed Othman .Faculty of medicine, Department of Orthopedic Surgery, Zagazig University. Egypt.

E-mail:dr.mohamadothman@gmail.com

Received date: October 08,2018 ;Accepted date : October 25,2018 ; Published date: October 30,2018.

Citation for this Article : Mohamed Othman. Anterior cervical discectomy and fusion versus dynamic cervical implant – arthroplasty for treatment of cervical degenerative disc disease: A prospective comparative study. J. Spinal Diseases and Research,

Doi: [10.31579/jsdr.2018/015](https://doi.org/10.31579/jsdr.2018/015).

Copyright : © 2018 Mohamed Othman .This is an open-access article distributed under the terms of the Creative Commons Attribution License, which permits unrestricted use, distribution, and reproduction in any medium, provided the original author and source are credited.

Abstract

The purpose of this study was to compare the outcomes of anterior discectomy and fusion (ACDF) versus dynamic cervical implant replacement (DCI) for treating single-level cervical degenerative disc disease (CDDD).

Patienta and methods

This prospective study included 34 patients with a single-level symptomatic CDDD between C3 and C7, treated with either ACDF or DCI, at two different centres, between 2014 and 2017. The mean age was 38.8±8 (28–57) years. All patients had axial neck and radiculopathy. Cases with myelopathy were excluded. Four patients were lost from follow-up. The remaining 30 cases (16 ACDF and 14 DCI) were followed-up for a mean period of 17.3 ± 7.2 (12 – 24) months.

Results

There was no statistical difference in operative time, and intraoperative blood loss, between the two groups. Clinically, the neurologic condition, VAS-scores for neck and arm pains, and neck disability index showed significant, persistant and comparable improvements in both groups. Radiologically; the intervertebral height at treated level and the alignment of C2-7 and of implanted segment showed significant and comparable improvements in both groups. DCI resulted in better ROM of C2-7 and of implanted level than ACDF did. ROM in adjacent segments did not change significantly in both groups. The complications were; transient hirseness (n=1), transient dysphagia (n=1), asymptomatic nonprogressive DCI anterior migration (n=1), asymptomatic pseudarthrosis after ACDF (n=2), and symptomatic ASD after ACDF (n=1).

Conclusions

Both ACDF and DCI arthroplasty are effective and safe; with comparable outcomes, for treatment of single-level CDDD. A longer follow-up period will be needed to determine the long-term effects.

Keywords

Cervical Degenerative, Anterior, Discectomy, Fusion, Stabilization, Dynamic, Arthroplasty

Introduction

Currently, the anterior cervical discectomy and fusion (ACDF) still represents the standard treatment of cervical degenerative disc disease (CDDD), providing satisfactory short-term results in most patients [1-6]. However, Its main drawback is segmental immobilization, and consecutive overloading and hypermobility of adjacent levels, which accelerate adjacent segment degeneration (ASD) on the long term follow-up [2- 9]. For these reasons, motion-preserving solutions have been developed to produce a physiological distribution of range of motion (ROM) and stresses at implanted and adjacent levels, thereby reducing the risk of ASD [10-14]. Cervical total disc replacement (CTDR) is the standard motion-preserving solution [12,14,15]. Recent results of several multicenter comparative studies have demonstrated equivalent or superior results of CTDR over ACDF as regards to clinical outcomes, reoperation rates at the treated level, and symptomatic ASD [14-18].

However, the main drawback of CTDR is that its design allows for ROM, especially in axial rotation and in lateral bending, which is significantly beyond the natural ROM of the healthy spine, leading to increased facet joints loading, with consequent accelerated facet degeneration. Moreover, CTDR is contraindicated in presence of multi-level disease (≥ 3 levels), facet degeneration and fused adjacent level [16-20].

Dynamic cervical implant –arthroplasty (DCI- replacement) is a novel non-fusion treatment philosophy for CDDD that stabilizes the involved segment while maintaining a reduced ROM. It was initially developed to combine the potential advantages of ACDF and CTDR [13,21-23]. The principal characteristics of DCI are; (1) a one piece implant composed of titanium, (2)seen from lateral, it has a U-shaped design; to conform the concave end plates, and to allow axial elasticity and act as a shock absorber and has straight teeth on the upper and lower anterior ends; to prevent implant migration (3) seen from the top,

It has a rectangular shape that corresponds to the end-plate footprints of the cervical vertebra [6,12]. The potential biomechanical advantages of DCI over ACDF are the ability to maintain segmental motion, thus minimizing the development of ASD [7,13]. It has many potential advantages over CTDR: (a) it provides controlled, limited flexion and extension which is greater than that seen with ACDF, but less than that seen with CTDR, while precluding lateral bending and axial rotation, thus protecting facet joints from excessive stresses. Therefore, the DCI is a potential treatment option for patients with facet arthrosis who would be contraindicated for CTDR, (b) it functions as a shock absorber, because its U-shaped structure absorbs vibrations; thereby protecting the adjacent levels from excessive stresses, (c) it fits well on the vertebral endplate, resulting in immediate postoperative stability; (d) its fixation does not need vertebral body screws, keels, or flanges, but is secured to the endplate via serrated edges, therefore it can be used to treat multilevel disease without compromising the vertebral endplate architecture, (e) it has no metal-polyethylene articulating surface, (as noted with several CTDR), thus avoiding development of wear debris and wear-induced osteolysis, (f) a relatively simpler procedure, with a shorter learning curve [6,7,10-13,20-25].

The purpose of this study was to compare the clinical and radiographic outcomes of using ACDF versus DCI-arthroplasty in the treatment of single-level CDDD.

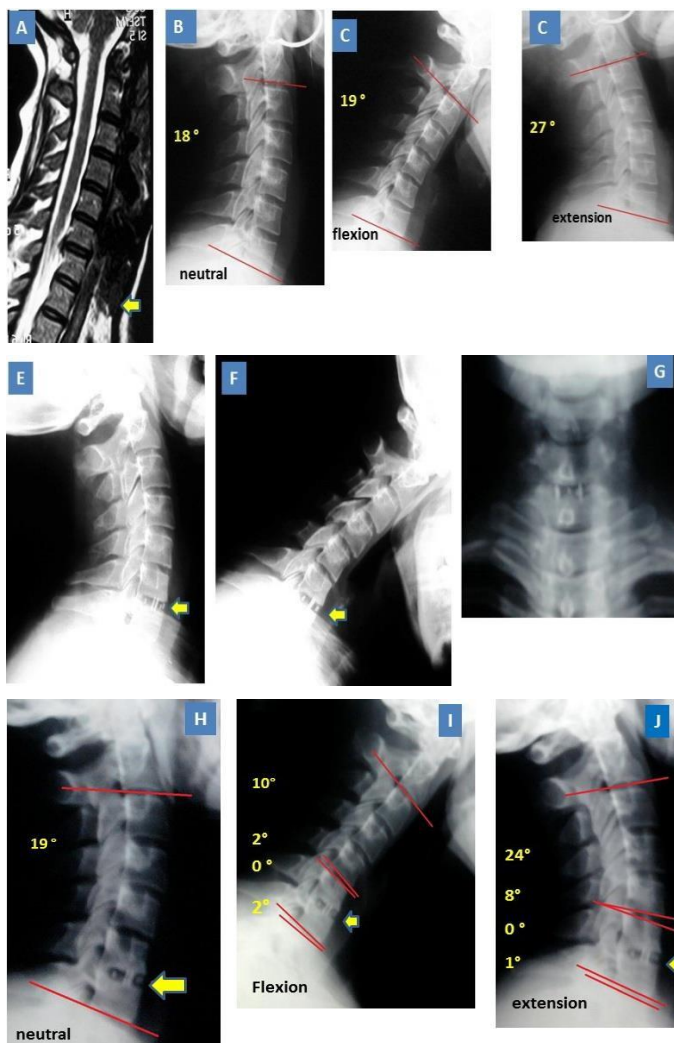


Figure 1: 40 ys old lady with C6-7 DDD., treated by ACDF. (1) Preop. MRI, (2) preop. lateral neutral view: 18 ° overall alignment, (3&4) preop. dynamic views: 46 ° GROM, (5,6,7) 1 y postop.: good position of cage, (8) final lateral view: 19 ° overall lordosis, and good C6-7 fusion (9&10) final dynamic views: fused treated level, 34 ° GROM, and no adjacent levels hypermobility.

Patients and Methods

This prospective study included 34 patients with a single-level symptomatic cervical degenerative disc disease, treated with either ACDF (n = 18) or DCI (n = 16), at two different centres, between Dec. 2014 and April 2017, after approval by the local ethical committee and obtaining informed consent from the patients. The ACDF-group was executed by the 1st and 3rd authors at their institution and the DCI-group was executed by the 2nd author at his institution. Four patients were excluded because they were lost from follow-up. The mean age was 38.8 ± 8 (28–57) years. Twenty patients were males and 14 patients were females. All patients had axial neck and radiculopathy. Affected motion segments were C3-4 (5.9 %), C4-5 (8.8 %), C5-6 (50 %), and C6-7 (35.3 %).

Inclusion criteria were: patients between 18 years and 60 years old, with CDDD, leveled between C3-C7 causing neck and/or arm pain, that were refractory to conservative treatment for at least 3 months. Exclusion criteria were multiple levels disease, cervical myelopathy, segmental instability, severe spondylosis at the affected level, severe facet arthrosis at the affected level, active infection, osteoporosis, inflammatory spondyloarthropathies such as ankylosing spondylitis or rheumatoid arthritis, and previous cervical spine surgery.

Assessment

Clinical Assessment

The patients were assessed using Visual Analogue Scale for neck (VAS-N) and arm (VAS-A) pain, neurological examination and functional assessment using Neck Disability Index (NDI) [26]; preoperatively, postoperatively and finally, as well as final postoperative patient's satisfaction with the result of surgery (using Odom's grading system) [27].

Neck disability index is a questionnaire entailing ten items, to give information of how neck pain affects the ability to manage daily life activities (ADLs). It is interpreted as; no disability: (0-4 points), mild disability: (5-14 points), moderate disability: (15-24 points), severe disability: (25-34 points), and complete disability: (35-50 points)[26].

Odom's grading system was used to evaluate patient's satisfaction with the surgery. Outcomes were rated as; excellent: (relieved all preoperative symptoms and able to execute ADLs without impairment), good: (minimally persistent preoperative symptoms, but can perform ADLs without significant impairment), fair: (relieved some preoperative symptoms, but had significant limitation of ADLs), and poor: (persistent or worsened symptoms and signs) [27].

Radiographic Assessment

[A] Plain radiographs:

Plain AP and lateral radiographs were obtained preoperatively and on the first postoperative day and subsequently supplemented by a flexion/extension views. The following parameters were evaluated and calculated using (Surgimap); a preoperative planning software application for orthopedic surgeons [developed by Nemaris Inc., USA]:

1. The location of the implant and the intervertebral height (IH) were observed on lateral neutral radiographs. The IH was measured by the distance from the midpoint of the upper endplate of the upper vertebral body to the midpoint of the lower endplate of the lower vertebral body [19].
2. Cervical alignment was measured using the Cobb angle, in neutral lateral radiographs: (a) overall cervical alignment (C2–7): was measured between the baseplate of C2 and coverplate of C7 or between the tangents of the posterior body line of C2 and C7. Patients were classified as lordotic ($\geq 10^\circ$; 10 to 40), neutral or straight (0° – 10°), or kyphotic ($< 0^\circ$), and (b) functional spinal unit (FSU) angle. Patients were classified as lordotic ($\geq 5^\circ$), neutral (0° – 5°), or kyphotic ($< 0^\circ$) [5,6].
3. Sagittal ROM using the Cobb method, on full flexion and extension lateral radiographs: [a] overall ROM, global ROM (GROM), or (C2-7) ROM, and [b] segmental ROM at the treated level, and at the adjacent upper and lower levels [6,19].

4. Postoperative changes and complications: Implant migration was defined as every AP or lateral position change compared with the baseline radiograph on the first postoperative day. Subsidence was determined by measuring the distances between both end plates of the index segment beside the implant. Subsidence was defined as loss of height of > 3 mm. Radiolucency around DCI was defined as lucent zones between the surface of the implant and the end plates of the adjacent vertebrae. Fusion was defined as and considered complete when: (a) good bony trabecular formation between the endplates; or trabecular bridging bone formation at the anterior and/or posterior cortex of the involved vertebral bodies appeared, (b) disappearance of lucencies between cage and vertebral plates, (c) absence of motion, or flexion-extension ROM at the fusion site was $\leq 2^\circ$, or motion < 1 mm between the tips of the spinous processes in flexion-extension and (d) the adequate disc height was restored, without collapse-induced kyphosis [4-6,19,24].

[B] CT scans including 3D-reformats were evaluated for signs of prosthesis subsidence or extrusion, HO, or spontaneous fusion [24].

[C] MRI was used preoperatively for diagnosis of CDDD at the index level. The postoperative ASD was assessed by MRI done at follow-up [5,19].

Statistical analysis

Achieved data were analyzed using Microsoft Excel software. Data were then imported into Statistical Package for the Social Sciences (SPSS version 20.0) software for analysis. The data were expressed as number and percentage, with mean \pm SD. The following tests were used to test differences for significance; difference and association of qualitative variable by Chi square test (X2) or Fisher . Differences between quantitative independent groups by t test paired by paired t . P value was set at <0.05 for significant results & <0.001 for high significant result.

Operative procedures

Similar to the techniques described by previous authors [4,6,12,19,23], the principal steps were: (1) A standard anterior approach through a transverse skin incision on the right side of the neck, (2) Discectomy and complete neural decompression of dura and origin of nerve roots, (3) Preparation of the bed for the implant: in ACDF, both anterior and posterior osteophytes were removed and endplates were curetted to the subchondral bone, while in DCI, the posterior osteophytes were completely removed to fully seat the U-portion of the device. Failure to remove these correctly may lead to suboptimal decompression and device displacement, but the anterior osteophytes were preserved, to avoid promotion of HO. Also, it is important during endplate cleaning to respect cartilage and avoid bony bleeding. (4) Trial sizing: The height and diameter of the implant were determined by implant trials and lateral fluoroscopic monitoring. Implant undersizing may lead to poor fixation and implant migration. The largest possible implant that can be safely placed should be selected to maximize implant–endplate contact and to gain support from the apophyseal rim, (5) Bone graft from the removed osteophytes were put in the PEEK-cage, (6) Implant insertion: under fluoroscopic monitoring, the implant was inserted under slight distraction of the segment. Then compression was applied using Caspar pins to fixate the teeth of the implant into the bony end plates. The position of the implant was very important. It should be placed as posterior as possible, but the distance between the anterior/posterior edge of the implant and the vertebral body edge should be controlled to within a range of 2–3 mm, and the lateral boundary of the DCI should not exceed the Luschka joint . A depth-controlled stop mechanism allowed for safe and controlled device placement in the anterior–posterior direction. The implants used, were DCI from Paradigm Spine (GmbH, Wurmlingen, Germany), or polyether-etherketone (PEEK) cages from EgyFix (Egypt), (7).

To reduce the formation of HO after DCI, osseous and soft tissue bleeding was meticulously controlled, blood and bone dust were washed, and damaged bone was covered with bone wax, (7) Wound closure over a drainage tube, (8) wear a cervical collar for one week after DCI and four weeks after ACDF.

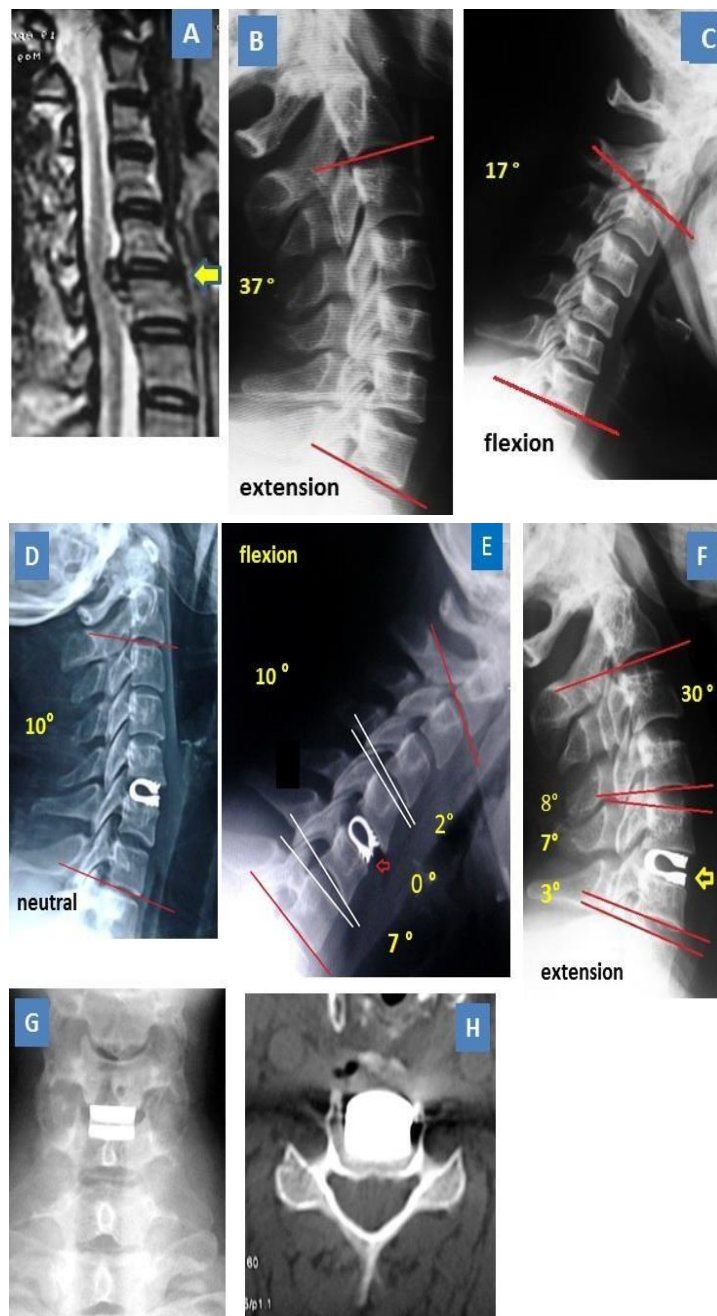

Figure 2: 39 ys old lady with C5-6 DDD; (A) preop. MRI, (B&C): preop. Dynamic views: 46° GROM, (D) final lateral neutral view: good position of DCI & 10° overall lordosis, (E&F): final dynamic views: maintained 7° ROM at implanted level, good GROM & no hypermobility of adjacent levels, (G&H): good position of DCI.

Postoperative care

After DCI, a cervical collar was used for the first week to help soft tissue healing and relieve pain. All patients were then permitted to begin physiological action of the cervical spine during daily life. . After the initial 6 weeks, patients were allowed to engage in normal activities of daily living including driving. After 8 weeks, patients were allowed to return to all normal activities. After ACDF, a cervical collar was used for four weeks postoperatively.

Results

Operative time and intraoperative blood loss:

There were no significant differences in operation time or intraoperative blood loss between the two groups. The operative time was 84.4 ± 21.5 (60 – 100) min. in ACDF-group versus 79.8 ± 15.8 (55 – 95) min. in DCI-group ($P=0.48$). The intraoperative blood loss was 90.6 ± 25.6 (55 – 120) ml in ACDF-group versus 79.2 ± 23.6 (45 – 95) ml in DCI-group ($P=0.23$).

The final outcome

The mean final follow-up period

Four cases were lost to final follow-up. The remaining 30 cases (16 ACDF and 14 DCI) were followed-up for a mean period of 17.3 months \pm 7.2 months (Range: 12 – 24 months).

Clinical outcome

(1) Neurologic assessment:

Preoperatively, in ACDF-group, sensory deficits were present in all cases and motor deficits were present in four cases (25%), while In DCI-group, sensory deficits were present in all cases and motor deficits were present in three cases (21.4%). Postoperatively, all patients showed significant improvement in neurological symptoms. Improvement was more in sensory deficits in both groups.

(2) Visual analogue scale for axial neck pain and radicular arm pain:

The VAS scores for neck and arm pains decreased significantly after surgery and maintained till the final follow-up, in both groups There was no statistically-significant difference between the two groups in VAS at the final follow-up, (Table 1).

(3) Functional assessment using the NDI [26]:

The mean NDI score decreased significantly from $53.2\% \pm 4.2$ preoperatively to $13.5\% \pm 1.7$ 12 finally in ACDF-group, and from $54.4\% \pm 2.31$ preoperatively to $13.8\% \pm 1.8$ finally in DCI-group. There was no statistically-significant difference between the two groups in mean NDI score at the final follow-up. (Table 1)

(4) Patient satisfaction:

According to the Odom criteria [27], 14 patients (87.5%) in ACDF-group and 12 patients (85.7%) in DCI-group had excellent or good patient's satisfaction. The proportion of patients with excellent /good satisfaction was not significantly different between the two groups ($P>0.05$), (Table 1).

Score	Time Period	ACDF-group (n=16)	DCI-group (n=14)	P-value
VAS-neck	Preoperative	7.2 \pm 1.2 (5.7 – 8.8)	7.5 \pm 1.3 (5.5 – 8.3)	0.57
	Postoperative	3.1 \pm 1.1 (2.2 – 4.0)	2.9 \pm 0.75 (2.0 – 3.4)	0.087
	Final	1.9 \pm 0.62 (1.5 – 2.4)	2.0 \pm 0.57 (1.4 – 2.5)	0.58
	Pre – final P	0.00**	0.00**	
VAS-arm	Preoperative	6.9 \pm 1.3 (5.2 – 8.0)	7.0 \pm 2.1 (5.5 – 8.0)	0.87
	Postoperative	2.2 \pm 0.72 (1.3 – 3.1)	2.1 \pm 0.69 (1.3 – 3.0)	0.68
	Final	1.2 \pm 0.34 (1.0 – 1.6)	1.1 \pm 0.29 (0.9 – 1.5)	0.37
	Pre – final P	0.00**	0.00**	
NDI	Preoperative	53.2% \pm 4.2 (50.3 – 57.0)	54.4% \pm 2.31(51 – 56.1)	0.32
	Postoperative	23.3% \pm 2.54 (20 – 25.1)	24.6% \pm 2.14 (20.3 – 26)	0.14
	Final	13.5% \pm 1.7 (12.2 – 14.4)	13.8% \pm 1.8(12.4 – 14.6)	0.67
	Pre – final P	0.00**	0.00**	
Odom's scale(excellent/good/fair/poor)	Final	5/9/1/1	4/8/1/1	

Table 1: Clinical results.

Radiographic Outcome

(1) The intervertebral height (IH)

The mean IH at the treated level increased significantly after surgery and the effect remained still significant till the final follow-up in both groups, (Table 2).

	Follow-up period	ACDF-group (n=16)	DCI-group (n=14)	P-value
(C2-7) alignment (°)	Preoperative	8.9 \pm 5.6 (7–18)	9.0 \pm 3.4 (7.5–16)	0.86
	Postoperative	10.1 \pm 4.3 (8.9–18)	10.9 \pm 3.7 (9–16.1)	0.17
	Final FU.	12.6 \pm 7.6 (9.5–19)	12.9 \pm 4.4 (10–18)	0.74
	Pre – final P	0.00**	0.00**	
Alignment of treated segment (°)	Preoperative	1.0 \pm 2.42 (-0.2–4.0)	1.2 \pm 1.48 (-0.1–3.1)	0.23
	Postoperative	3.5 \pm 1.4 (2.5–4.4)	3.8 \pm 1.2 (2.0–4.2)	0.59
	Final FU.	3.1 \pm 1.3 (2.9–5.2)	3.0 \pm 1.4 (2.8–5.0)	0.88
	Pre – final P	0.00**	0.00**	
IH in mm	Preoperative	33.9 \pm 2.2	34.1 \pm 1.2	0.74
	Postoperative	37.8 \pm 3.0	38.5 \pm 2.1	0.68
	Final FU	36.3 \pm 2.1	36.4 \pm 1.8	0.88
	Pre – final P	0.002*	0.005*	

Table 2 : Radiologic outcome [cervical alignment and intervertebral height]

(3) Sagittal ROM (Table 3):

	FU period	ACDF-group	DCI-group	P-value
Global ROM (°)	Preoperative	49.5±5.2 (39-53)	48.3±4.5 (38-54)	0.482
	3 mo-FU.	39.2±3.8 (33-44)	46±2.8 (44-48.2)	0.0002**
	Final FU.	40.1±3.1(33-44)	45.8±1.8 (44-47.1)	0.001**
	Pre - final P	0.00**	0.21	
Treated Segment ROM (°)	Preoperative	7.7 ± 1.7(6.8-8.9)	7.9 ± 1.8 (6.9–8.4)	0.78
	3 mo-FU.	0.8±0.35 (0-1.5)	6.0 ± 1.2 (5.5–7.3)	0.00**
	Final FU.	0.7±0.32 (0 -1.4)	5.0±1.8 (4.0–7.0)	0.00**
	Pre – final P	0.00**	0.001**	
Upper adjacent segment ROM (°)	Preoperative	9.0±1.7 (8.2-10.3)	9.4±1.9 (8.4–10.4)	0.58
	3 mo-FU.	9.1±1.8 (7.8-10.5)	9.0±1.4 (8.0–10.0)	0.86
	Final FU.	9.5±1.3 (8.2-10.7)	9.0±1.6 (8.1–10.1)	0.43
	Pre – final P	0.42	0.58	
Lower adjacent segment ROM (°)	Preoperative	8.8±2.3 (3.9-9.2)	9.0±2.1 (8.5-10)	0.73
	3 mo-FU.	8.3±2.8 (3.8-9.0)	8.9±1.9 (7.9-10)	0.77
	Final FU.	9.1±3.7 (3-11.3)	8.8±1.5 (7.9-10.2)	0.21
	Pre – final P	0.21	0.77	

Table 3 : Radiologic outcome [sagittal ROM].

- a. The sagittal ROM of the treated segment in ACDF-group decreased significantly from 7.7±1.7 (6.8-8.9) preoperatively to 0.7±0.32 (0 -1.4) finally, while in DCI-group, it was 7.9± (6.9–8.4) preoperatively, and was maintained at 5.0± (4.0–7.0) at the final follow-up.
- b. The sagittal ROM of the upper and lower adjacent segments showed no significant differences between preoperative and final values in both groups, and between the two groups.
- c. The global ROM (C2-7) in ACDF-group decreased significantly from 49.5±5.2 (39-53) preoperatively to 40.1±3.1 (36-44) finally, while in DCI-group, it changed from 48.3±4.5 (38-50) preoperatively to 45.8±1.8 (44-47.1) at final follow-up (P=0.21). The global ROM was significantly higher in DCI-group.
- c. Anterior migration of DCI > 2mm in one patient, detected six weeks postoperatively, but was not associated with dysphagia, respiratory problem, vascular or neurological complications. It was treated by wearing a cervical collar for six weeks, and it remained asymptomatic and without further migration till the final follow-up at 18 months-postoperatively.
- d. Pseudarthrosis in two cases (14.3%) in ACDF-group, but they were asymptomatic fibrous non-unions that required no further treatment
- e. Symptomatic ASD in one case in ACDF-group. The level affected was already degenerated before the index surgery. It became symptomatic 20 months after surgery. Symptoms improved on conservative treatment.

However, there were no deaths, dural tears, hematoma, infections, or iatrogenic damage. Also, there were no excessive subsidence, or HO.

Discussion

ACDF is an effective and safe method for the treatment of CDDD, leading to a high rate of clinical success. However, fusion of the treated segment may result in increased stresses and increased intradiscal pressure in the untreated adjacent levels, resulting in increased risk of ASD [1-9,11,28]. This complication led to the search for dynamic spinal solutions that could provide sufficient stability and simultaneously produce a physiological distribution of ROM and stresses at operative and adjacent levels, thereby reducing the risk for developing ASD [10-14,20,21]. The most common nonfusion technique is CTDR [14,15]. Several randomized controlled trials demonstrated that CTDR had superior or equivalent clinical outcomes and a lower reoperation rate for operated or neighbouring segments than ACDF [14-18]. However, CTDR has many disadvantages such as a high rate of HO and spontaneous fusion [29,30]. The main drawback of CTDR is that its design allows for lateral bending and rotation, that is significantly beyond the natural ROM of the healthy spine, leading to excessive loading of facet joints, with consequent accelerated facet degeneration. Moreover, CTDR is contraindicated in presence of facet degeneration, ≥ 3 diseased levels, and fused adjacent level [15-20].

	ACDF-group (n=16)	DCI-group (n=14)	P-value
Fusion rate	12 (87.5%)	0	0.00**
Pseudarthrosis	2 (12.5%)		
Radiolucency	0	2 (14.3%)	0.0004**
Subsidence in mm	1.5 ± 0.7	2.1 ± 0.9	0.03*
Migration	0	1 (7.15%)	0.02*
ASD	1 (6.2%)	0	0.03*

Table 4 : Radiologic outcome [changes and complications].

Complications

- a. Transient horseness in one case in ACDF-group.
- b. Transient swallowing difficulty in one case in DCI-group.

DCI is a new non-fusion implant that was initially developed to combine the potential advantages of fusion and CTDR [20-25]. The potential biomechanical advantage of DCI over ACDF is the ability to maintain segmental motion, thus minimizing the development of ASD [7,13]. DCI-arthroplasty has many theoretical advantages over CTDR : (a) A relatively simpler surgery with a shorter learning curve , (b) allows controlled, limited flexion /extension—the primary motions in the subaxial cervical spine—which is greater than that seen with ACDF, but less than that seen with CTDR, while precluding rotation and lateral bending movements, thus protecting the facet joints from excessive loads, (c) acts as a shock absorber, therefore protecting the adjacent segments from excessive stresses, (d) no metal–polyethylene articulating surface, thus no wear debris or wear-induced osteolysis, (e) its Fixation depends on its serrated edges, and not screws, keels, or flanges, thus allowing treating multilevel disease without compromising the vertebral endplate architecture, (f) immediate postoperative stability, as it fits well on the vertebral endplate [6,10-13,19-25].

In this study, we compared the clinical and radiological outcomes of ACDF versus DCI-arthroplasty in treatment of single-level CDDD with radiculopathy.

Our results proved that both techniques are effective and safe.

There was no statistical difference in operative time, and intraoperative blood loss, between the two groups in the current study and in the studies of Zhu et al,2014 [10], Zeng et al., 2017 [7], and Zhu et al,2018 [19].

Clinical outcomes in the current study as assessed by neurologic assessment, VAS scores for neck and arm pains, functional NDI score, and patients' satisfaction showed significant and comparable improvements in both groups (Table 1). These results were comparable to the results of similar comparative studies reported in the literature [6,7,10,11,19]. In the study of Li et al, 2014 [11], the VAS, SF-36, JOA, and NDI scores improved significantly after surgery in both the DCI and ACDF groups. The VAS, JOA, and SF-36 scores were not significantly different between the two groups at the final follow-up. Using Odom's criteria, 81.0% of patients in the ACDF group and 84.5% of patients in the DCI group rated their level of satisfaction with the surgery as excellent or good, which was not a significant difference between groups. In the study of Zhu et al,2014 [10] comparing ACDF, DCI and CTDR for treating single level cervical spondylotic myelopathy in 91 patients, with a mean follow-up of 19.9 months, there was no statistical difference in operative time, intraoperative blood loss, and JOA recovery rate among the three groups, but postoperative JOA scores differ significantly from their preoperative JOA scores. Richter et al 2016 [6], treated 60 patients with one- or two-level CDDD with either DCI or ACDF. Both groups showed significant clinical improvement, 12 months postoperatively using the VAS-scores, NPAD, and EQ-5D; with no significant differences between the two groups. Zeng et al,2017 [7], found no statistical difference between DCI and ACDF group in VAS for neck and arm and between DCI and CTDR group in NDI. Zhu et al 2018 [19], compared ACDF for DCI in treatment of single-level CDDD, with a five-year follow-up . The JOA, VAS, NDI, and SF-36 scores improved postoperatively and were comparable between the two groups. However, the proportion of patients who reported their level of satisfaction as being very satisfied, or somewhat satisfied was larger in the ACDF group than that in the DCI group (95.3% vs 79.1%).

The radiologic results in the current study showed the following findings: (a) The mean IH at the treated level increased significantly after surgery and the effect remained still significant till the final follow-up in both groups, (b) The alignment of C2-7 and of the implanted segment increased significantly after surgery and remained till the final follow-up; with no significant difference between the two groups, (c) The global ROM was significantly higher in DCI-group. The sagittal ROM of the treated segment in ACDF-group decreased significantly from 7.7 ± 1.7 (6.8-8.9) preoperatively to 0.7 ± 0.32 (0 - 1.4) finally,

While in DCI-group, it was 7.9 ± 1.8 (6.9–8.4) preoperatively, and was maintained at 5.0 ± 1.8 (4.0–7.0) at the final follow-up. The segmental ROM of the adjacent levels showed no significant differences between preoperative and final values in both groups, and between the two groups (Tables 2,3).

Our radiologic results were comparable to the results of similar comparative studies reported in the literature [6,7,10,11,19]. In the study of Li et al, 2014 [11], with a follow up for > 2 years, the segmental ROM at the treated level and overall ROM increased significantly after surgery in the DCI group, but the ROM in the adjacent cephalad and caudal segments did not change significantly. The mean disc height (DHI) at the treated level was significantly restored after surgery in both groups. In the study of Zhu et al,2014 [10], comparing ACDF, DCI and CTDR, with a mean follow up for 19.9 months, the global ROM was significantly higher in DCI-group and CTDR-group. The mean segmental ROM at the treated level decreased significantly to 0.0 finally after ACDF, while, it was maintained in DCI and CTDR-groups. The ROM in the adjacent cephalad and caudal segments did not change significantly in the three groups. In the study of Richter et al, 2016 [6], cervical lordosis improved significantly after using both DCI and ACDF for treating one- or two-level CDDD. In the study of Zeng et al,2017 [7], compared with ACDF group, DCI group presented higher treated segmental ROM, lower cephalad segmental ROM and caudal segmental ROM, but equal in overall range of motion (ROM). No significant difference in cephalad, treated and caudal segmental ROM was seen between DCI group and CTDR group. In the series of Zhu et al, 2018 [19], there was no statistically significant difference between the two groups in the IH, upper and lower levels ROM; preoperatively, 2 years postoperatively and at the final five-year follow-up. However, the postoperative ROM of the implanted level and C2-7 in the DCI group were significantly higher than that in the ACDF group at 2 years and at final follow-up. The ROM at the implanted level in the DCI group was maintained at 2 years postoperatively but decreased finally (10.7° vs 4.5°).

Possible and reported complications of ACDF and DCI are a major concern.

In the current study, transient horsesness occurred in one case in ACDF-group, and transient swallowing difficulty occurred in one case in DCI-group, In the study of Zhu et a,l 2014 [10], there were three cases with postoperative dysphagia in one week and recovered in two months.

Ventral migration of DCI is a possible and reported complication. Li et al., 2014 [11], reported one case of DCI anterior migration of 2 mm in one patient at the 12 month postoperatively. This was caused by a deficiency in the endplate milling process. This patient did not suffer from vascular or neurological complications or dysphagia. The implant was noted to have regained stability at the 18 month postoperatively, and continued to be stable till the most recent follow-up at 49 months postoperatively; with no need for revision surgery. In the study of Matge et al, 2015 [20], a symptomatic anterior migration of DCI occurred in a patient active in sport, that required DCI removal and then ACDF. Richter et al.2016 [6], reported ventral migration in 15.2% of their patients. In the current study, one case of anterior migration of DCI > 2mm was detected six weeks postoperatively, but was asymptomatic and remained without further migration till the final follow-up at 18 months-postoperatively.

In a trial to avoid DCI anterior migration, the bed preparation, size and location of DCI , and insertion are very critical for success as follows: (a) during preparation of the bed for DCI, the posterior osteophytes should be completely removed to fully seat the U-portion of the device. Failure to remove these correctly may lead to suboptimal decompression and device displacement , (b) sizing: Implant undersizing may lead to poor fixation and implant migration. The largest possible implant that can be safely placed should be selected to maximize implant– endplate contact and to gain support from the apophyseal rim, (c) the position of the implant is very critical.

It should be placed as posterior as possible, but the distance between the anterior/posterior edge of the implant and the vertebral body edge should be controlled to within 2–3 mm, and the lateral boundary of the DCI should not exceed the Luschka joint, (d) during Implant insertion: it should be inserted under slight distraction of the segment, then compression was applied using Caspar pins to fixate the teeth of the implant into the bony end plates [10,12,23,24].

Heterotopic ossification (HO) and spontaneous fusion were possible and reported complications following DCI. Matgé et al., 2015 [23] reported a 35% rate of HO (including 20% minor and 15% major) after DCI, in 47 patients with 58 operated levels at 24 months follow-up. Zhu et al., 2018 [19], after a five-year follow-up, reported HO around DCI in 46.5% of their patients, and they attributed this to the longer follow-up duration of their study. On the otherhand, in the current study and in the study of Li et al., 2014 [11], there was no HO around DCI. Wang et al., 2014 [12] found no HO or spontaneous fusion at the implanted level on 12- and 24-month CT images during the follow-up. However, Wang et al., 2018 [24] after a minimal 5-years follow-up, reported HO in 57.1% of their patients. They attributed this high incidence to the longer follow-up duration, and the use of a high-speed burr to remove the cartilage endplate intraoperatively, which may injure the bony endplate and cause subchondral bleeding. The negative influence of HO is reduction of segmental ROM and spontaneous fusion, with the risk of developing ASD and HO at the posterior edge of the vertebra may cause stenosis of spinal canal or the intervertebral foramen, leading to recurrence of neurologic symptoms [19,29,30]. However, many reports found that although HO reduced segmental ROM but observed no negative influence of HO on clinical outcomes [19,31]. Improvement in surgical technique may play an effective role in preventing HO through: (a) anterior osteophytes were not excised, (b) resecting posterior osteophytes and the hyperplastic posterior longitudinal ligament, (c) osseous and soft tissue bleeding was meticulously controlled, (d) blood and bone dust were washed, and (e) damaged bone was covered with bone wax, and (f) implanting a matching DCI as large as possible for the largest contact area between the DCI and the vertebral endplate, to improve immediate elastic stability postoperatively and avoid bony contact between the adjacent vertebral endplates at the treated segment [10,12,23,24].

Reduction of segmental ROM and spontaneous fusion at the implanted level after DCI, with longer follow-up was a great concern, because it contradicts the hypothesis that DCIs preserve motion [6]. Richter et al., 2016 [6], found unintended fusion of the implanted level in 39.4% of their patients at the 1-year follow-up. They suggested that this may represent the physiologic response to the high rate of radiolucency in their series. In the study of Zhu et al., 2018 [19], ROM at the operated level was maintained well during the first two-year follow-up, but it decreased significantly at the final five-year follow-up (10.7° vs 4.5°). They attributed this to HO and/or implant subsidence. In the study of Matgé et al., 2015 [23] about DCI, there were good motion (5° – 12°) of the implanted level in 57%, reduced motion (2° – 5°) in 34.5%, and little motion (0° – 2°) in 8.5%; demonstrating that satisfying motion preservation of the implanted level ($>2^\circ$) could be preserved in 91.5%, while 8.5% had a near segmental fusion. Mean ROM at superior and inferior adjacent segments showed maintenance of adjacent-level kinematics, with no hypermobility. They suggested that slow fusion appears to protect against ASD as neighboring cervical spine structures may adapt over time, if lordosis was restored or maintained. In the current study, the treated segment ROM was maintained at 5.0 ± 1.8 (4.0 – 7.0) at the final follow-up; with no spontaneous fusion.

Radiolucency around DCI is a reported drawback of DCI. Richter et al [6] reported a high percentage of radiolucency in the DCI group (90.9%) and suggested that this may explain why neck pain did not improve as much as it did in the ACDF group in their patients. With regard to the two revision operations in their DCI group, they found that implants were easy to remove, with only fibrous tissue located between DCI surface and bony endplates.

They considered this as a significant drawback of the DCI and as a source of more potential dislocations and increasing neck pain at later follow-ups, as it indicates nonintegration of the implant into the bony end plates. On the otherhand,

Zhu et al., 2014 [10], Zhu et al., 2018 [19], and Matgé et al., 2015 [23], did not report such complications in their series.

Implant subsidence was reported in two cases in each group in the study of Li et al., 2014 [11], and in 30.2% (13/43) in DCI-group in the study of Zhu et al., 2018 [19]. Wang et al., 2014 [12], found no case of DCI subsidence after two years postoperatively. Wang et al., 2018 [24] after five-years follow-up, reported DCI subsidence in 33.3%. In the current study, implant subsidence was 1.5 ± 0.7 mm in ACDF-group versus 2.1 ± 0.9 mm in DCI-group ($P = 0.03$). however, we did not find this complication in the current study when using definition of > 3 mm loss of IH, as proposed by Zhu et al., 2018 [19].

Wang et al., 2018 [24], suggested that severe DCI subsidence, theoretically not only causes a decrease in ROM at the index level, but also leads to a loss of vertebral height of the operated segment; resulting to reduction of the intervertebral foramen area, with consequent radiculopathy. However, no patient in the their study had such complication. Matgé et al., 2015 [23], stressed on, endplate preservation to prevent further subsidence

Fusion rate after ACDF is another concern. Li et al., 2014 [11] reported a fusion rate of 94.9% in ACDF-group. Richter et al., 2016 [6], reported a fusion rate of 80% in ACDF-group, with pseudarthrosis in 20%. Mastronadi et al [4] reported a fusion rate of 16.7% at 3 months, 61.1% at 6 months, and 100% at one year after ACDF. In the current study, the fusion rate after ACDF was (87.5%), with pseudarthrosis in 12.5%.

An important issue is the potential of adjacent segment disease (ASD) particularly after ACDF. Many previous studies have shown that loss of motion at the fused level is compensated by hypermobility and increased intradiscal pressure at adjacent segments after ACDF, which induces a high rate of ASD [1-5,8-12,28]. The diagnosis of ASD is based on the presence of new degenerative canal stenosis or progressive discogenic disease \pm neural compression at the one or more levels adjacent to the operated level. It can occur either a progressive increase of previously asymptomatic disc degeneration or as a newly developed adjacent level disc disease [5]. According to Hilibrand et al., [9], symptomatic ASD occurs at a relatively constant incidence of 2.9% per year (range 0–4.8%) during the ten years after ACF with autogenous bone graft. On the basis of survivorship analysis, the authors [9] predicted that 25.6% of cases who had an ACF with autogenous bone graft would have new symptomatic ASD within ten years after surgery and about 70% of these symptomatic patients need additional surgical procedures. Contrary to expectation, the risk of an adjacent level new disease was significantly lower following multilevel than singlelevel ACF [4,9]. In the study of Elsawaf et al., 2009 [5], five out of 20 patients (20%) showed ASD problems in their MRI after a mean follow-up of 28 months (range 13–38) of ACDF. Just one patient (5%) needed surgical intervention. Matgé et al., 2015 [23], reported symptomatic accelerated ASD, 24 months after DCI-arthroplasty in only one of 47 patients (2%). Li et al., 2014 [11], reported comparable rate of ASD between ACDF and DCI groups (14.3% vs 12.8%). Also, Zhu et al., 2018 [19], reported comparable rate of ASD between DCI and ACDF groups (16.3% vs 20.9%), due to HO around DCI. In the current study, ASD did not occur in DCI-group, but in one case (6.2%) in ACDF-group. The level affected was already degenerated before the index surgery. It became symptomatic 20 months after surgery, and improved on conservative treatment.

The conclusions of similar comparative studies are an important issue and could be beneficial. Welke et al., 2011 [25], executed a biomechanical comparative study, and concluded that, the DCI implant could provide an alternative to cage supported ACDF or CTDR in the cervical spine. Zhu et al., 2014 [10], concluded that, ACDF, DCI and CTDR are effective therapies for single level cervical spondylotic myelopathy. But each group has respective advantages and disadvantages. Li et al., 2014 [11], after a follow-up for more than two years, concluded that DCI is an effective, reliable, and safe procedure for the treatment of CDDD.

However, there is no definitive evidence that DCI arthroplasty has better intermediate-term results than ACDF. Richter et al., 2016 [6], concluded that the clinical results for DCI treatment are equivalent to those for ACDF in treatment of one- and two-level cervical DDD at 12 months after surgery. Further studies are necessary to investigate the high rates of radiolucency and fusion associated with DCI treatment. Zeng et al., 2017 [7], concluded that DCI is as effective and safe as ACDF and CTDR for patients with CDDD. DCI may maintain the ROM of treated segment and delay the occurrence of ASD. However, insufficient evidence supports that DCI may decrease the stress of facet joints. Zhu et al., 2018 [19], executed a five-years follow up comparative study and concluded that DCI resulted in better ROM of C2-7 and of the implanted level than ACDF did. The clinical outcomes were similar between two groups. However, the ROM at the implanted level decreased at final follow-up in the DCI group, which may contribute to patient dissatisfaction. The long-term outcomes were not that satisfactory especially due to the deviation from its original intention as a non-fusion technique. As such, they have not used DCI in the past 2 years.

This study is limited by the relatively small number of patients, and the relatively short period of follow-up. A longer follow-up period (more than two years and better if ≥ 5 years) will be needed to evaluate for development of complications such as HO, spontaneous fusion around DCI, and subsidence and to determine the extent to which DCI protects against ASD.

Conclusions

Both ACDF and DCI-replacement are reliable, effective and safe; with comparable outcomes, for treatment of single-level CDDD. The clinical parameters improved significantly after surgery, and the effect remained till the final follow-up in both groups; with no statistically-significant difference between the two groups. Radiologically, the alignment of C2-7 and of the implanted segment increased significantly after surgery and remained till the final follow-up; with no significant difference between the two groups. DCI resulted in better ROM of C2-7 and the implanted level than ACDF did. The complications were few, and comparable in both groups. Proper indication and surgical technique are fundamental to success. A longer follow-up period will be needed to determine the long-term effects.

References

- Goff in J, Geusens E, Vantomme N, Quintens E, Waerzeggers Y, Depreitere B, et al (2004). Long-term follow-up after interbody fusion of the cervical spine. *J Spinal Disord Tech.* 17:79–85
- Ishihara H, Kanamori M, Kawaguchi Y, Nakamura H, Kimura T. (2004) Adjacent segment disease after anterior cervical interbody fusion. *Spine J* 4(6):624–628.
- Kulkarni V, Rajshekhar V, Raghuram L (2004) Accelerated spondylotic changes adjacent to the fused segment following central cervical corpectomy magnetic resonance imaging study evidence. *J Neurosurg* 100(1 Suppl Spine):2–6
- Mastronardi L, A. Ducati A, Ferrante L. (2006) Anterior cervical fusion with polyetheretherketone (PEEK) cages in the treatment of degenerative disc disease. Preliminary observations in 36 consecutive cases with a minimum 12-month follow-up. *Acta Neurochir (Wien).* 148: 307–312.
- Elsawaf A, Mastronardi L, Raffaelino R, Bozzao A, Caroli M, Ferrante L. (2009) Effect of cervical dynamics on adjacent segment degeneration after anterior cervical fusion with cages. *Neurosurg Rev.* 32:215–224.
- Richter H, Seule M, Hildebrandt G, Fournie J. Dynamic(2006) Cervical Implant versus Anterior Cervical Discectomy and Fusion: A Prospective Study of Clinical and Radiologic Outcome. *J Neurol Surg A*;77:300–307.
- Zeng J, Duan Y, Liu H, Wang B, Gong Q, Yang et al (2017) Dynamic cervical implant in treating cervical degenerative disc disease: a systematic review and meta-analysis. *Int J Clin Exp Med* 10(6):8700-8708
- Cho SK, Riew KD. Adjacent segment disease following cervical spine surgery. *J Am Acad Orthop Surg*; 2013: 21:3–11
- Hilibrand AS, Carlson GD, Palumbo MA, Jones PK, Bohlman HH. (1999) Radiculopathy and myelopathy at segments adjacent to the site of a previous anterior cervical arthrodesis. *J Bone Jt Surg Am*; 81:519–528
- Zhu R, Yang H, Wang Z, Wang G, Shen M, et al (2014) Comparisons of three anterior cervical surgeries in treating cervical spondylotic myelopathy. *BMC Musculoskeletal Disorders* 15:233.
- Li Z, Yu S, Zhao Y, Hou S, Fu Q, (2014) Clinical and radiologic comparison of dynamic cervical implant arthroplasty versus anterior cervical discectomy and fusion for the treatment of cervical degenerative disc disease. *J Clin Neurosci* ;21(6):942–948.
- Wang L, Song YM, Liu LM, Liu H, Li T. (2014) Clinical and radiographic outcomes of dynamic cervical implant replacement for treatment of single-level degenerative cervical disc disease: a 24-month follow-up. *Eur Spine J* ;23(8):1680–1687
- Mo ZJ, Zhao YB, Wang LZ, Sun Y, Zhang M, et al (2014) Biomechanical effects of cervical arthroplasty with U-shaped disc implant on segmental range of motion and loading of surrounding soft tissue. *Eur Spine J*; 23:613–621.
- Park JY, Kim KH, Kuh SU, Chin DK, Kim KS, et al (2013) What are the associative factors of adjacent segment degeneration after anterior cervical spine surgery? Comparative study between anterior cervical fusion and arthroplasty with 5-years follow-up MRI and CT. *Eur Spine J*;22:1078–1089.
- Mummaneni PV, Burkus JK, Haid RW, Traynelis VC, Zdeblick TA. (2007) Clinical and radiographic analysis of cervical disc arthroplasty compared with allograft fusion: a randomized controlled clinical trial. *J Neurosurg Spine.* ;6(3): 198–209.
- Chang UK, Kim DH, Lee MC, Willenberg R, et al (2007) Range of motion change after cervical arthroplasty with ProDisc-C and prestige artificial discs compared with anterior cervical discectomy and fusion. *J Neurosurg Spine.*;7(1):40–46.
- Heller JG, Sasso RC, Papadopoulos SM, Anderson PA, Fessler RG, et al. (2009) Comparison of BRYAN cervical disc arthroplasty with anterior cervical decompression and fusion: clinical and radiographic results of a randomized, controlled, clinical trial. *Spine*;34(2):101–117.
- McAfee PC, Reah C, Gilder K, Eisermann L, Cunningham B. (2012) A meta-analysis of comparative outcomes following cervical arthroplasty or anterior cervical fusion: results from 4 prospective multicenter randomized clinical trials and up to 1226 patients. *Spine*.37(11):943–952.
- Zhu C, Yang X, Wang L, Hu B, Liu L, et al (2018) Comparison of dynamic cervical implant versus anterior cervical discectomy and fusion for the treatment of single-level cervical degenerative disc disease: A five-year follow-up. *Clinical Neurology and Neurosurgery.* 164: 103–107
- Matge G, Buddenberg P, Eif M, Schenke H, Herdmann J. (2015) Dynamic cervical stabilization: a multicenter study. *Eur Spine J* 24:2841–2847.
- Herdmann J, Buddenberg P, Rhee S. (2009) A dynamic cervical disc replacement—in between fusion and prosthesis. *Eur Spine J*; 18:1713–1826
- Herdmann J, Buddenberg P, Trautwein F, Rhee S, Piltz A, et al (2012) Does maintenance of physiologic kinematics in the adjacent segment prevent adjacent segment degeneration following cervical dynamic stabilization? In: 7th German Spine Conference, Stuttgart, Germany, 6th–8th December *Eur Spine J* 21:2329
- Matge G, Berthold C, Gunness VR, Hana A, Hertel F. (2015) Stabilization with the dynamic cervical implant: a novel treatment approach following cervical discectomy and decompression. *J Neurosurg Spine.* 22:237–245.

24. Welke B, Hurschler C, Schwarze M, Packheiser A, Tak S, et al Biomechanical comparison between fusion, TDR and dynamic stabilization. In: 6th German Spine Conference, Hamburg, Germany, 8th–11th December 2011. *Eur Spine J* 20:2017–2018.
25. Welke B, Hurschler C, Schwarze M, Packheiser A, Tak S, Richter B, Daentzer D. Biomechanical comparison between fusion, TDR and dynamic stabilization. In: 6th German Spine Conference, Hamburg, Germany, 8th–11th December 2011. *Eur Spine J* 20:2017–2018
26. Vernon H, Mior S.(1991) The neck disability index: A study of reliability and validity. *Journal of Manipulative and Physiological Therapeutics*, 14:409-415
27. Odom GL, Finney W, Woodhall B. Cervical disk lesions. *J Am Med Assoc* (1958) ; 166:238 [28]
28. Eck JC, Humphreys SC, Lim TH, Jeong ST, Kim JG, et al (2002) Biomechanical study on the effect of cervical spine fusion on adjacent level intradiscal pressure and segmental motion. *Spine* 27 (22)::2431–2434
29. Leung C, Casey AT, Goffin A, Kehr P, et al (2005) Clinical significance of heterotopic ossification in cervical disc replacement: a prospective multicenter clinical trial. *Neurosurgery*. ;57(4):759–763.
30. Mehren C, Suchomel P, Grochulla F, Barsa P, et al (2006) Heterotopic ossification in total cervical artificial disc replacement. *Spine*.;31(24):2802–2806.
31. Zhou HH, Qu Y, Dong RP, Kang MY, Zhao JW. Does(2015) Heterotopic ossification affect the outcomes of cervical total disc replacement? A meta-analysis, *Spine (Phila Pa 1976)*.15;40(6): E332-40.