

Utilization of Low-Frequency Ultrasound Therapy to Aid in the Healing of a Chronic Painful Ulceration of the Lower Extremity in an Ovarian Cancer Patient: A Case Report

Alton R. Johnson^{1*}, Jean Holewinski², and Marie Williams³

¹Podiatric Medicine and Surgery Clinical Research Fellow, University of Pennsylvania Hospital Systems Penn-Presbyterian Medical Center, Philadelphia, PA, USA

²Clerkship Director, Aventura Hospital and Medical Center, Aventura, FL, USA

³Residency Program Director of Podiatric Surgery, Aventura Hospital and Medical Center, Aventura, FL, USA

*Corresponding author: Alton R. Johnson, Podiatric Medicine and Surgery Clinical Research Fellow, University of Pennsylvania Hospital Systems Penn-Presbyterian Medical Center, Philadelphia, PA, USA.

Received date: July 11, 2020; Accepted date: July 15, 2020; published date: July 20, 2020

Citation: Alton R. Johnson, Jean Holewinski, and Marie Williams. Utilization of Low-Frequency Ultrasound Therapy to Aid in the Healing of a Chronic Painful Ulceration of the Lower Extremity in an Ovarian Cancer Patient: A Case Report. J Clinical Research and Reports, 5(1); DOI:10.31579/2690-1919/107

Copyright: © 2020 Alton R. Johnson. This is an open access article distributed under the Creative Commons Attribution License, which permits unrestricted use, distribution, and reproduction in any medium, provided the original work is properly cited.

Abstract:

The purpose of this case study was to investigate the healing capabilities of low-frequency ultrasound therapy to heal chronic painful ulceration. In this case, a 61-year-old African American female with a past medical history of hypertension, chronic venous insufficiency, and ovarian cancer on chemotherapy presented to the clinic complaining of a painful chronic ulceration to the left ankle. The patient attributed the re-ulceration of this chronic wound to her current chemotherapy treatment drug doxorubicin. After the initial consultation, patient therapy that recommended was ultrasound therapy due to the patient stating the lesion was too painful for frequent sharp debridement in the clinical setting even when utilizing a topical anesthetic. The recommended interval treatments included a seven-minute session to the wound three times a week over a period of nine months. There were noted changes in the appearance of the wound base after the first week of therapy and changes in the size by the second week of therapy. Throughout the treatment regimen, the patient's pain tolerance to the wound improved as well. After nine-month, there was noted complete healing of the tissues without any complications. In conclusion, ultrasound therapy often referred to as MIST therapy can be a useful device to heal chronic painful wounds in immunocompromised patients when therapy options are limited.

Keywords: Wound; wound care; ultrasound frequency therapy; ovarian cancer

Introduction:

Low-Frequency Ultrasound Therapy usage on chronic non-healing wounds has been proven to decreased to bacterial load by penetrating both into and below the wound bed by removing barrier biofilm, decreasing inflammation, and decreasing matrix metalloproteinase 9 (MMP-9). Most wound care therapies are limited to treating the wound surface; however, ultrasound therapy sound waves penetrate into and below the wound bed to accelerate the normal healing process. Studies link this therapy in increased vasodilation, angiogenesis, collagen deposition, and growth factors [1-3].

The Patient: A 61-year-old African American female with worsening chronic left medial ankle ulceration for greater than a month presented to our facility by referral from her oncologist. The patient reported that this ulceration was "achy" in nature with a 10/10 on the pain scale. After the initial consultation, patient therapy that recommended was ultrasound therapy due to the patient stating the lesion was too painful for frequent sharp debridement in the clinical setting even when utilizing a topical anesthetic. The patient-related that the chemotherapy drug doxorubicin causes the ulceration to re-ulcerate. This patient's past medical history consisted of hypertension, chronic venous insufficiency, stage 4 ovarian

cancer on antineoplastic chemotherapy. Patient medications consisted of lactulose 10 grams, Vitamin D3 1000 unit tablet once daily, and doxorubicin 2mg/mL IV suspension at chemotherapy. The only known drug allergy for this patient was penicillin.

Physical Examination:

General Appearance: Patient awake, alert, well developed, well-nourished and well-groomed

Cardiovascular: There is edema of the lower extremities. The palpable pedal pulses are diminished bilaterally.

Extremities: Pain on palpation to the lesion, moves all lower extremities, normal inspection

Neurological: Deep tendon reflexes intact 2/4, no ankle clonus, Sensory testing all intact bilateral lower extremities.

Dermatologic: Full Thickness ulceration to the level of subcutaneous tissue located at the medial malleolus with a fibrotic wound base and no granulation tissue and punched out wound as well. The wound was tender to touch. Measurement of the wound documented as 5cmx4cmx0.5cm

without signs of infection. The ulcer was noted to have an irregular border. Does not probe to bone (At Initial Presentation)

therapy using sterile saline solution for 7 minutes three times a week for nine months.

Low-Frequency Ultrasound Therapy Device

Therapy: The patient's therapy consisted of performed ultrasound

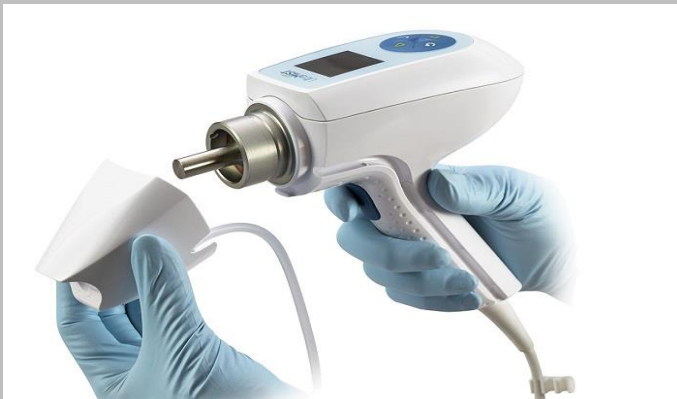

Figure 1A



Figure 1B

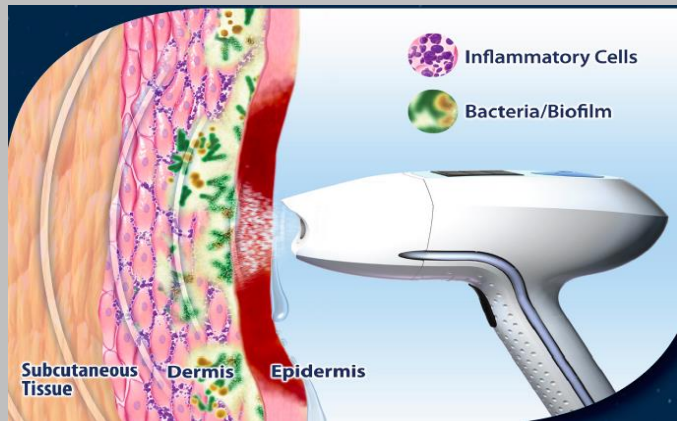


Figure 1C

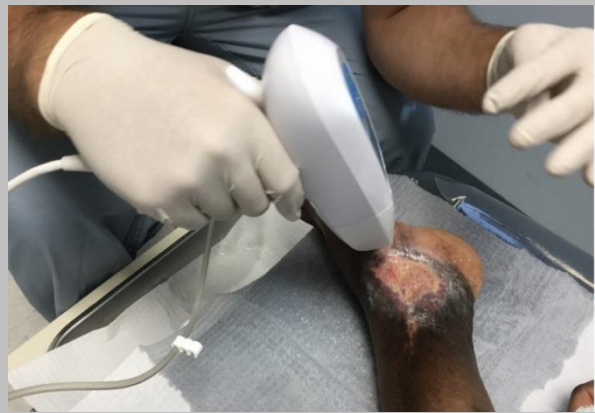

Figure 1D

Figure 1 A-D: Utilization/Illustration of Low-Frequency Ultrasound Therapy to Chronic Ulceration

Clinical Presentation Image Series:

Initial Presentation

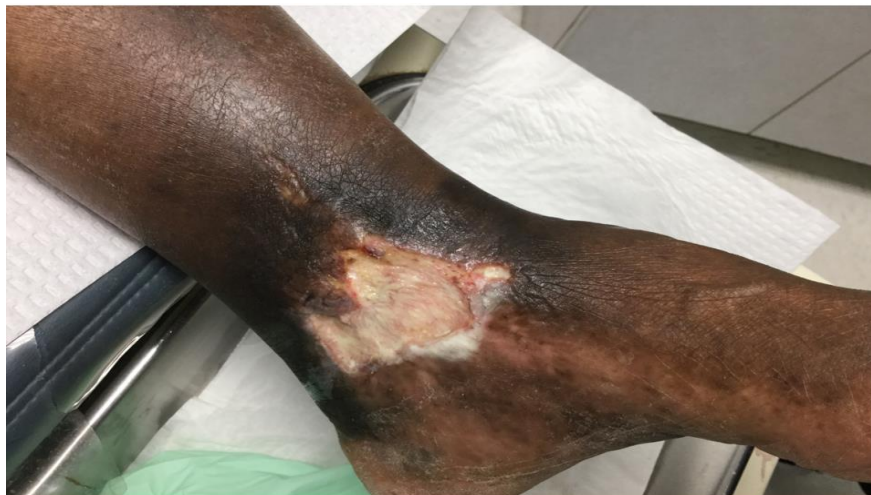
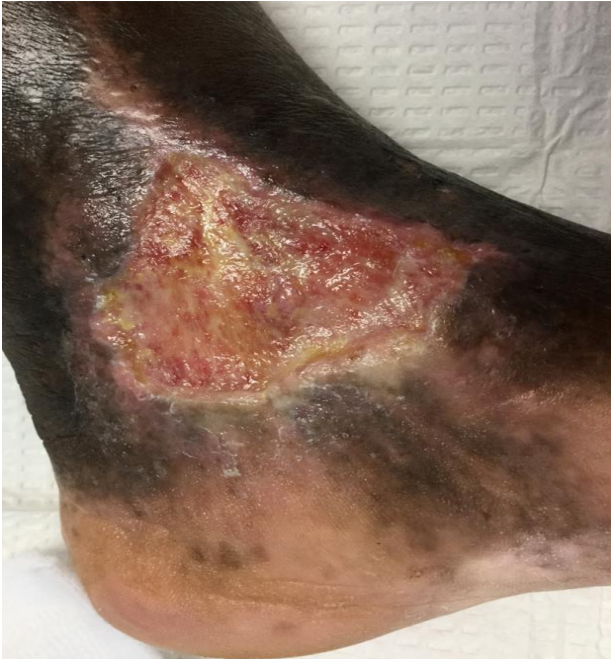
Figure 2: Left Medial Full Thickness Ulceration to the level of Subcutaneous Tissue Medial Malleolus

3 Months After Initiation Low-Frequency Ultrasound Therapy



**Figure 3: Healing Full Thickness Ulceration with Granular Base
9 Months After Initiation of Low-Frequency Ultrasound Therapy**

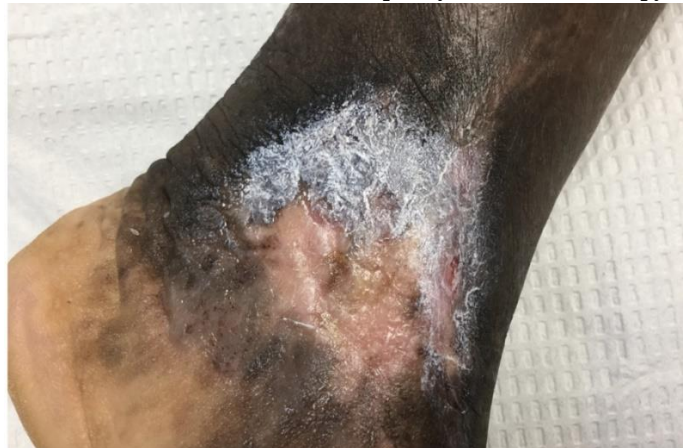

Figure 4: Complete Healed with Epithelialization

Discussion:

The patient's wound was completely healed and epithelialized nine months

after the initial therapy without any re-ulceration or complications. Throughout the treatment regimen, the patient's pain tolerance to the wound improved as well. Indicating that low-frequency ultrasound therapy often referred to as MIST therapy can be a useful device to heal chronic painful wounds in immunocompromised patients when therapy options are limited.

Disclaimer:

The authors disclose that this research was supported (in whole or in part) by HCA Healthcare and/or an HCA Healthcare affiliated entity. The views expressed in this publication represent those of the authors and do not necessarily represent the official views of HCA Healthcare or any of its affiliated entities.

References

1. Kavros SJ, Schenck EC (2007) Use of Noncontact Low-Frequency Ultrasound in the Treatment of Chronic Foot and Leg Ulcerations: A 51 Patient Analysis. *J Am Podiatr Med Assoc*; 97(2):95-101.
2. Serena T (2009) The Impact of Noncontact, Nonthermal, Low-Frequency Ultrasound on Bacterial Counts in Experimental and Chronic Wounds. *OWM* 55(1):22-30.
3. Seth AK, Mustoe TA, Galiano RD, et al (2013) Noncontact, low-frequency ultrasound as an effective therapy against *Pseudomonas aeruginosa*-infected biofilm wounds. *Wound Repair & Regeneration*. (21) 266-274.
4. Yao M, et al (2012) A Pilot Study Evaluating Noncontact Low Frequency Ultrasound and Underlying Molecular Mechanism on Diabetic Foot Ulcers. *International Wound Journal* 11-19- 012 on-line publication.
5. Escandon J, Vivas AC, Perez R, Kirsner R, Davis S (2012) A Prospective Pilot Study of Ultrasound Therapy Effectiveness in Refractory Venous Leg Ulcers. *International Wound Journal*; 9(5):570-578.
6. Liedl DA, Kavros SJ (2001) The Effect of Mist Ultra-Sound Transport Technology on Cutaneous Microcirculatory Blood Flow. *SAWC*.
7. Maan ZN, Gurtner GC, et al (2013) Evaluation of the Role of Noncontact Low-Frequency Ultrasound Therapy on Angiogenesis During Wound Healing American College of Surgeons Clinical Congress.
8. Thawer HA, Houghton PE (2004) Effects of Ultrasound Delivered Through a Mist of Saline to Wounds in Mice with Diabetes Mellitus. *J Wound Care*.13(5):1-6
9. Lai JY, Pittelkow MR (2007) Physiological Effect of Ultrasound Mist on Fibroblasts. *Int J Dermatol*. 46(6):587-593.