

## Instantaneous Reconstruction of Inferior Rectus: Asset for Vision

Sanjoy Chowdhury<sup>1\*</sup>, Madhumita Srivastava<sup>2</sup>, Nilanjan Chowdhury<sup>3</sup>

<sup>1</sup>Chief Ophthalmologist, 4C/3020, Bokaro steel city, Jharkhand, India.

<sup>2</sup>Specialist, Jharkhand, India.

<sup>3</sup>Resident Bokaro General Hospital, Bokaro steel city, Jharkhand, India

\*Corresponding author: Sanjoy Chowdhury, Chief Ophthalmologist, 4C/3020, Bokaro steel city, Jharkhand, India, Email:

drsanjoy@hotmail.com

Received Date: November 10, 2019; Accepted Date: December 09, 2019; Published Date: January 4, 2020.

Citation: Chowdhury S, Srivastava M, And Chowdhury N. (2020) Instantaneous Reconstruction of Inferior Rectus: Asset for Vision. Surgical Case Reports and Images, 3(1): Doi:10.31579/jsci/2019/011

Copyright: © 2020. Sanjoy Chowdhury. This is an open-access article distributed under the terms of the Creative Commons Attribution License, which permits unrestricted use, distribution, and reproduction in any medium, provided the original author and source are credited.

### Abstract

Orbital lesions are frequent findings after blunt periocular trauma causing diplopia, muscle avulsion etc. Four patients presented with diplopia after a penetrating injury to the right eye. Examination revealed right hypertropia and limitation of infraduction of right eye with rupture of Inferior Rectus. Immediate repair of inferior rectus muscle with anterior transposition of inferior oblique is a safe and effective procedure to restore motility

**Key Words:** Ocular motility disorders, Eye injuries, Inferior rectus & anterior transposition of inferior oblique

### Introduction

Orbital trauma is associated with various periorbital and ocular injuries, causing diplopia, muscle avulsion and/or incarceration, paralysis and scar adhesions. In cases of vertical diplopia, rupture of the inferior rectus muscle (IR) secondary of trauma is an infrequent finding, yet possible cause of persistent infraduction deficit. Also it has been seen that traumatic muscle laceration involves the inferior or medial rectus muscles more often. Hypertropia with lack of infraduction following trauma is a diagnostic feature. Persistent Defect leads compensatory changes, posing a surgical challenge later on, so standard procedure includes repair of flap tear, transposition of horizontal recti, and reattachment of distal end to proximal connective tissues. Inferior oblique transposition is not much reported in literatures. Here we present four cases of traumatic inferior rectus muscle laceration which was corrected with anterior transposition of inferior oblique to the snapped inferior rectus muscle stump. [1,2]

### Case Reports

Four cases of traumatic inferior rectus laceration were isolated among orbital trauma patients. All patients had hypertropia with lack of infraduction which was diagnostic of trauma to inferior rectus. Infraduction of the affected eye was markedly reduced. Forced-duction testing showed no limitation to elevation and infraduction in the affected eye, suggesting an isolated lesion of IR with no entrapping of orbital tissue and associated muscle. To restore the function anterior transposition of inferior oblique muscle to IR was planned. Under local anaesthesia IR muscle was explored and in all three cases and only the proximal stump of snapped IR could be found. Inferior oblique muscle was anteriorly transposed at the distal stump of inferior rectus. Traction suture was given which was removed after 10 days. Figure: [1, 2, 3, 4, 5, 6, 7&8]

### Exploration of snapped inf rectus

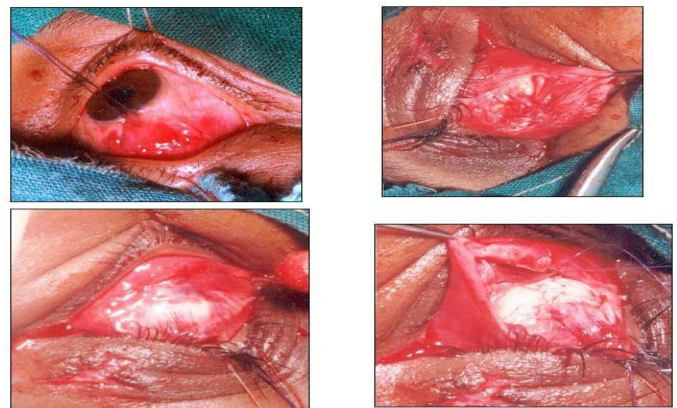


Illustration 1

### Anterior transposition of Inf oblique

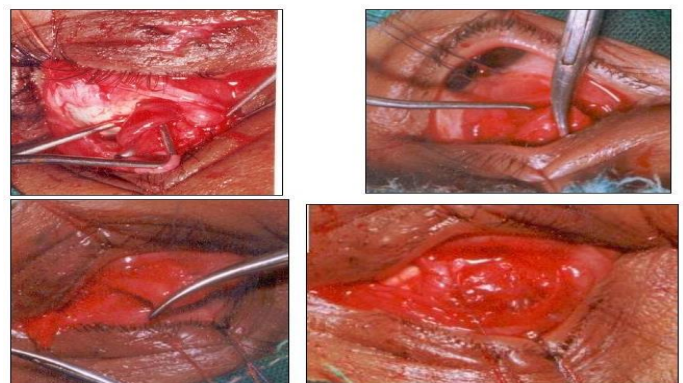
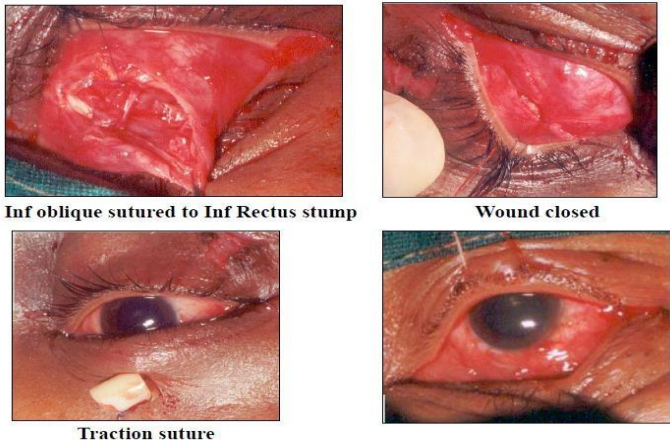


Illustration 2

### Anterior transposition of Inf oblique

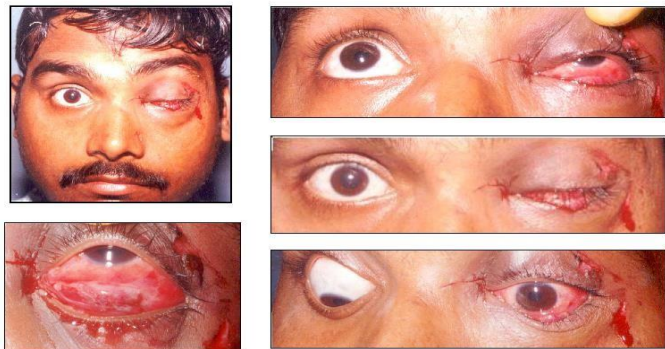

Inf oblique sutured to Inf Rectus stump

Wound closed

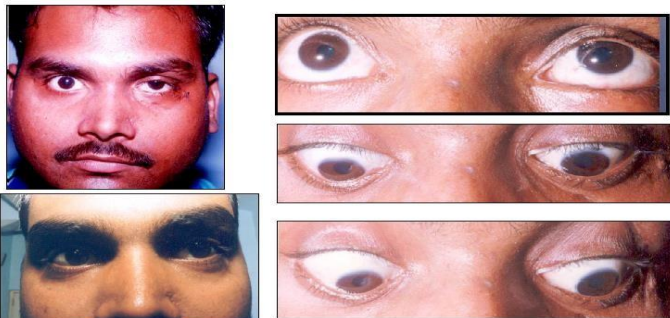
Traction suture

**Illustration 3  
Case 1 (Preop)**

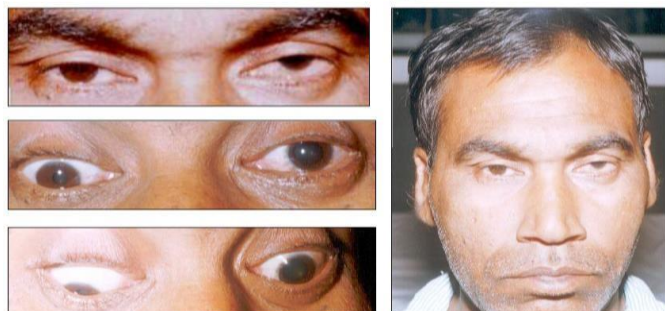

Blunt trauma : No infraduction

**Illustration 4  
Case 1 (Postop)**



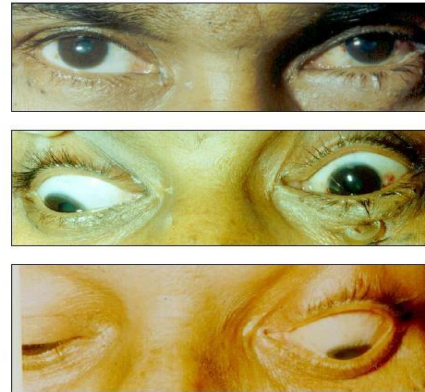**Restored infraduction  
Illustration 5  
Case 2 (Preop)**



Blunt trauma : No infraduction

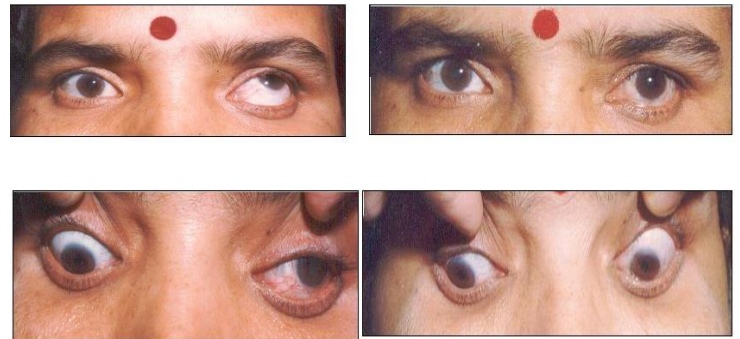
**Illustration 6**

**Restored infraduction Case 2 (Postop)**



**Illustration 7**

**Case 3 (Preop) Case 3 (Postop)**



Blunt trauma : No  
infraduction

Restored infraduction

**Illustration 8**

### Result

Two weeks after surgery restoration of motility in all the three cases who underwent repair promptly after injury was seen, but partial recovery in the fourth case. Primary repair in the fourth case involved only repair of distal stump without any transposition. Delayed transposition was difficult and less effective.

### Discussion

In the literature range of ocular injuries following orbital trauma is well described. [3,4] Rupture of IR is a possible cause of infraduction deficit, being the complete isolated muscle avulsion more infrequent than longitudinal flaps. [5] We postulate that during orbital trauma, sudden traction by orbital septal attachments to the orbital layer of the rectus muscle (ref2) may tear the muscle. The resulting motility defect depends upon the severity of the torn inferior rectus as it scars into surrounding soft tissue. Prompt repair can restore function and anterior transposition of inferior oblique prevents secondary changes.

### Conclusion

Prompt repair of snapped inferior rectus muscle with the help anterior transposition of inferior oblique is a safe and effective procedure to restore motility and a delay can give not good result.



## References

- 1) Von Noorden GK Binocular Vision and Ocular Motility. (1996) Theory and Management of Strabismus. 5Thed. St Louis: Mosby. p455.
- 2) Demer JL et al. (2000) Evidence for active control of extraocular muscle pulleys. Invest Ophthalmol Vis Sci. 41:1280-1290.
- 3)
- 4) Ludwig IH, Brown MS. (2001) Strabismus due to flap tear of a rectus muscle. Trans Am Ophthalmol Soc 99:53-62; discussion 62-3.
- 5) Sloan B, McNab AA. (1998) Inferior rectus rupture following blowout fracture. Aust N Z J Ophthalmol. 26(2):171-3.