

Late Presentation of Penetrating Ulcers at the Ascending Aorta Associated With Intra-Mural Haematoma

Ayman Kenawy^{1*}, Mohamad Nidal Bittar²,

¹Cardiothoracic registrar Lancashire Cardiac Centre Blackpool Victoria hospital Blackpool UK

²Professor of Cardiothoracic surgery, Lancashire Cardiac Centre Blackpool Victoria Hospital Blackpool UK

*Corresponding author: Ayman Kenawy, FRCS CTh, Cardiothoracic registrar Lancashire Cardiac Centre, Blackpool Victoria hospital Blackpool UK.

Received date: January 11, 2020; Accepted date: January 29, 2020; Published date: February 03, 2020

Citation: Kenawy A, Mohamad N Bittar. (2020) late presentation of penetrating ulcers at the ascending aorta associated with intra-mural haematoma. Journal of surgical case reports and images, 3(2): Doi:[10.31579/2690-1897/015](https://doi.org/10.31579/2690-1897/015)

Copyright: © 2020 Ayman Kenawy, This is an open access article distributed under the Creative Commons Attribution License, which permits unrestricted use, distribution, and reproduction in any medium, provided the original work is properly cited.

Abstract

The combined pathology of intra-mural haematoma (IMH) and penetrating aortic ulcer (PAU) represents disease progression of the PAU with high risk for further progression to either rupture or pseudo-aneurysm formation, and hence surgical intervention should be offered once diagnosis is made regardless of the presentation.

We present a 70-year-old fit lady with chronic type A IMH associated with multiple PAUs, diagnosed incidentally, the patient underwent urgent surgical repair with good outcome.

Key words: penetrating aortic ulcer; intra-mural haematoma; late presentation of acute aortic syndrome

Introduction

Penetrating aortic ulcer or intra-mural haematoma of the ascending aorta when presenting acutely are dealt with as part of the acute aortic syndrome as is acute type A aortic dissection, and leaking aortic aneurysm. The controversy arises with the chronic presentation due to paucity of evidence in the literature.

Case presentation

We present a 70 year old lady who attended her local doctor's surgery with increasing shortness of breath over a 4-week period, which was first noticed when she could not keep up with her husband while on holiday abroad. She denied any associated chest pain at the time. Her past medical history includes bronchial asthma for which she took bronchodilators as required. Two months prior the patient presented to her local accident and emergency department with chest pain and feeling unwell. She was investigated for acute coronary syndrome, with the findings being negative. She was discharged and given the all clear.

She was referred to her local hospital, where clinical history was suspicious for pulmonary embolism (PE) and a computer tomography pulmonary angiogram (CTPA) was requested. This did not reveal PE but confirmed multiple penetrating aortic ulcers of the

ascending aorta associated with intra-mural haematoma and a dilated ascending aorta

The patient was transferred to our cardiac centre in stable condition. Transthoracic echocardiogram (TTE) showed normal left ventricular function and dimensions with mild aortic regurgitation (AR) and no pericardial effusion.

Cardiac gated CT aortogram with aortic reconstruction was undertaken, which showed multiple PAUs of the ascending aorta associated with IMH (figure 1), extending from the

Aorto-ventricular junction proximally up to the base of the innominate artery distally

(Figure 2), with no dissection flaps. The maximal aortic dimensions, with the IMH included, was 6.3cm externally and the internal diameter of 4.1 cm. It also confirmed normal coronaries.

The case was discussed at a multidisciplinary team meeting and it was thought that the IMH most likely started at her initial admission. The consensus was to proceed to urgent in-house surgery.

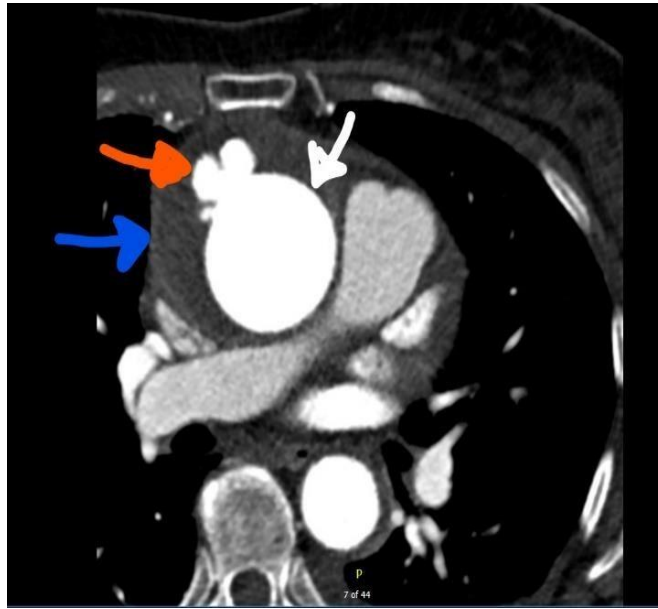


Figure 1: CT scan showing multiple PAUs and IMH of the ascending aorta, white arrow points to ascending aorta, red arrow points to PAUs, blue arrow points to IMH

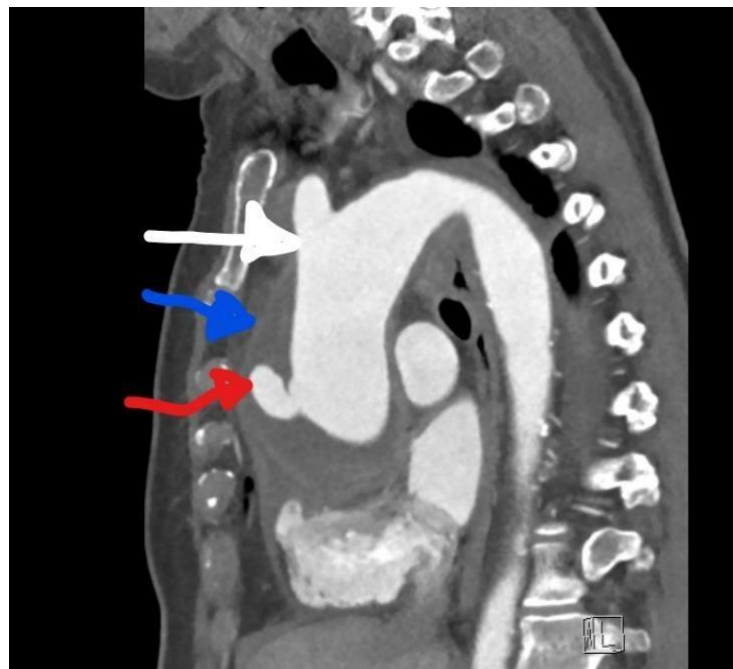


Figure 2: Reconstructed CT showing the proximal and distal extent of the IMH, white arrow points to the base of the innominate artery, blue arrow points to IMH and red arrow points to PAU

Surgical approach

Under general anesthetic we used the following monitoring; right and left radial lines, cerebral oximetry and nasopharyngeal temperature. Trans-oesophageal echocardiogram confirmed normal ventricular function and mild central aortic regurgitation and no dissection flap.

After the patient was anaesthetized, prepped and draped, right axillary artery was exposed and size 8mm Dacron tube graft was sewn to the artery after a small dose of heparin and an activated clotting time (ACT) of 250 seconds was achieved this was followed by median sternotomy and opening the pericardium, there were dense adhesions with mild pericardial effusion, the aorta was bruised and angry looking with impending rupture (figure 3).

Cardiopulmonary bypass was established after full dose heparin and an ACT above 480 seconds using right axillary artery and two stage venous cannulation, myocardial protection was achieved using antegrade and retrograde cardioplegia. Cerebral protection during lower body circulatory arrest was accomplished by antegrade cerebral perfusion (ACP) and lowering the systemic temperature down to 26 degrees centigrade, the ACP was achieved by clamping the base of the innominate artery to perfuse the right carotid artery and further two cerebral perfusion cannulas inserted into the left carotid and left subclavian arteries with a flow rate of 10ml/KG body weight.

On transecting the aorta, at the level of the right pulmonary artery, it was evident that there was an extensive intra-mural haematoma and PAU ostia and tracks, the ascending aorta was excised all the way from one

centimeter above the sino-tubular junction(STJ) to the base of the innominate artery, and sent for histology(histology report attached)

The patient underwent sino-tubular junction (STJ) reconstruction using Teflon strips on both inside and outside of the aorta and replacement of the ascending aorta and hemiarch using size 34 Dacron tube graft. The cardiopulmonary bypass and cross clamp times were 212 and 124 minutes respectively and lower body circulatory arrest time was 43

minutes.

The procedure was uneventful, with a smooth post-operative course and the patient was discharged home on post-operative day 6 and on outpatient review 6 weeks after discharge, is doing well.

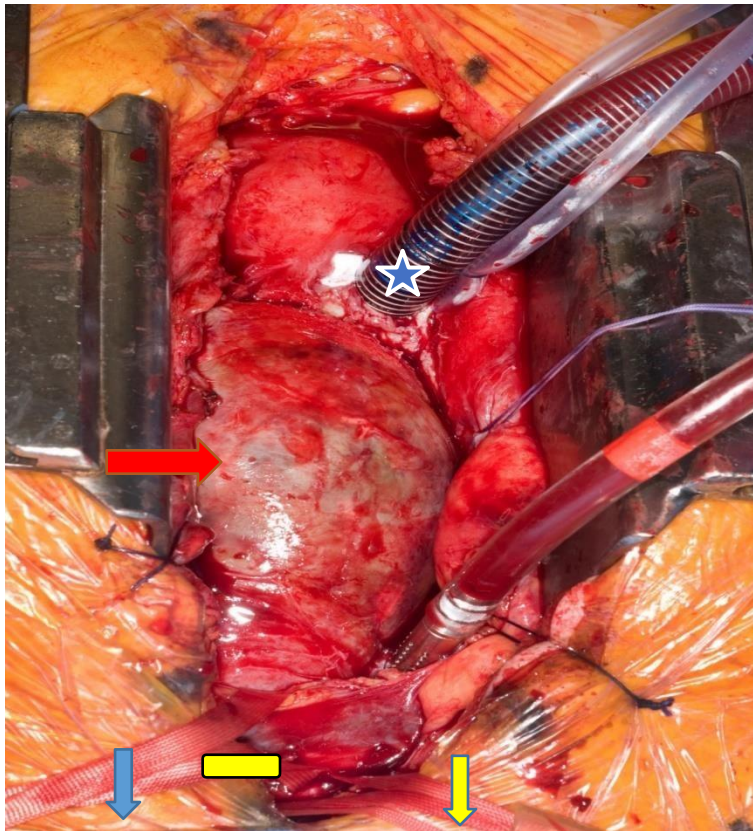


Figure 3. Operative photo showing the angry looking bruised ascending aorta (red arrow), blue arrow points to patient head, blue star indicates the venous cannula in the right atrium, yellow rectangle indicates the tape round the innominate vein and yellow arrow points to tapes round the innominate and left carotid arteries

18P00549 10/01/18 00:00 Updated		Norm	Unit
Histology			
Routine Histology			
REPORT	459 SPECIMEN AND		
	SITE:		
	A. Aortic wall.		
	B. Penetration ulcer.		
	CLINICAL DETAILS: Aortic hemi arch replacement.		
	MACRO:		
	A. Five strips of aortic wall, together measuring 75 mm by up to 45 x 2 mm, varying haemorrhage on one surface.		
	B. Two pieces of haemorrhagic firm tissue, together measuring 36 x 25 x 17 mm.		
	MICRO:		
	A. The tissue has been widely sampled. It shows aortic wall within which are aggregates of foamy macrophages. Within some foci there is fibrin present on the surface with underlying disruption of the vessel wall. In other areas, there is a prominent chronic inflammatory cell infiltrate with reaction and fibroblast formation within the wall of the vessel. The features are those of atherosclerosis with rupture.		
	B. This specimen comprises predominantly fibrin with areas of vessel wall present. Fibrin is seen extending through the vessel wall. These also have a chronic inflammatory cell infiltrate with fibroblastic proliferation. Special stains show no bacteria or fungi (gram, grocott and PASD negative).		
	The features overall are those of atherosclerosis, complicated by ulceration. There is no evidence of malignancy.		
	DIAGNOSIS:		
	A. Aortic wall - Chronic inflammation with atherosclerotic change.		
	B. Penetration ulcer - atherosclerosis with ulceration		
	REPORTED BY: Dr Consultant Histopathologist.		

Histology report of aortic tissue sent during surgery

Discussion

The combination of IMH and PAU in the ascending aorta is extremely rare and most cases with similar pathology were reported in the descending aorta, the initial symptoms two months prior to the index admission was most likely due to the PAU which was missed at this stage.

It is important for patients who present with ACS symptoms and have negative diagnostic criteria for ACS to have CT aortogram which is the gold standard investigation to rule out acute aortic pathology.

The guidelines, both American heart association [1] and European society of cardiology [2], for the management of acute aortic syndrome are quite clear, however, when aortic pathology is picked up incidentally the management is different. There is guidance for chronic dissection and non-leaking aneurysm based on size criteria, rate of expansion of the aorta or the presence of symptoms. There is, however, a lack of guidance and evidence for the management of chronic IMH and PAU of the ascending aorta due to the rarity of these cases [3]. Reports in the literature are mostly on the descending aorta, which is the most common site for IMH and PAU with the management being essentially conservative unless the patient is symptomatic, the aorta grows to a concerning size or ruptures [4].

The pathogenesis of IMH combined with PAU may lead to further progression, namely rupture or pseudoaneurysm[5] and hence surgical intervention should be prompt (3). In this case, despite the absence of typical symptoms, offering surgical intervention was deemed necessary based on the absence of patient co-morbidities and the association of IMH with PAU, which increased the likelihood of complications.

References

- Hiratzka LF, Bakris GL, Beckman JA, Bersin RM, Carr VF, Casey DE, et al. (2010) ACCF/AHA/AATS/ACR/ASA/SCA/SCAI/SIR/STS/SVM Guidelines for the Diagnosis and Management of Patients With Thoracic Aortic Disease. *Circulation*, 121(13):e266-e369.
- Members ATF, Erbel R, Aboyans V, Boileau C, Bossone E, Bartolomeo RD, et al. (2014). ESC Guidelines on the diagnosis and treatment of aortic diseases: Document covering acute and chronic aortic diseases of the thoracic and abdominal aorta of the adult. The Task Force for the Diagnosis and Treatment of Aortic Diseases of the European Society of Cardiology (ESC). *European Heart Journal*, 35(41):2873-926.
- Beckmann E DA, Jelly CA, Melnitchouk S. (2019). Type a intramural haematoma secondary to penetrating atherosclerotic ulcer of the ascending aorta. *Interact CardioVasc Thorac Surg*, 28:491–2.

4. Haring B, Kickuth R, Fluck F. (2019). Intramurales Hämatom der Aorta: eine diagnostische Herausforderung. Dtsch med Wochenschr, 144(07):484-8.
5. Stanson AW, Kazmier FJ, Hollier LH, Edwards WD, Pairolero PC, Sheedy PF, et al. (1986). Penetrating atherosclerotic ulcers of the thoracic aorta: natural history and clinicopathologic correlations. Ann Vasc Surg, 1(1):15-23.



This work is licensed under Creative Commons Attribution 4.0 License

To Submit Your Article Click Here: [Submit Article](#)

DOI:[10.31579/2690-1897/015](https://doi.org/10.31579/2690-1897/015)

Ready to submit your research? Choose Auctores and benefit from:

- ❖ fast, convenient online submission
- ❖ rigorous peer review by experienced research in your field
- ❖ rapid publication on acceptance
- ❖ authors retain copyrights
- ❖ unique DOI for all articles
- ❖ immediate, unrestricted online access

At Auctores, research is always in progress.

Learn more <https://www.auctoresonline.org/journals/journal-of-surgical-case-reports-and-images>