

A Legionella Pneumophilla Infection Masquerading as Acute Acalculous Cholecystitis

Richmond Ronald Gomes 

Associate Professor, Medicine, Ad-din Women's Medical College Hospital, Dhaka, Bangladesh

Corresponding Author: Dr. Richmond Ronald Gomes, Associate Professor, Medicine, Ad-din Women's Medical College Hospital, Dhaka, Bangladesh, Phone no: +8801819289499

Received date: September 09, 2020; **Accepted date:** September 14, 2020; **Published date:** September 18, 2020

Citation: Gomes R R. (2020) A Legionella Pneumophilla Infection Masquerading as Acute Acalculous Cholecystitis. International Journal of Clinical Case Reports and Reviews. 3(4); DOI: [10.31579/2690-4861/052](https://doi.org/10.31579/2690-4861/052)

Copyright: © 2020 Richmond Ronald Gomes, This is an open-access article distributed under the terms of the Creative Commons Attribution License, which permits unrestricted use, distribution, and reproduction in any medium, provided the original author and source are credited.

Abstract

Legionella pneumophilla represents a relatively common cause of community acquired pneumonia with high mortality related burden if not promptly diagnosed and treated with appropriate antibiotics. Clinical characteristics of Legionella infection are often non-specific making accurate diagnosis challenging. Here we report a case of a middle aged immunocompetent woman with a history of fever and abdominal pain located in the right upper abdomen. The paucity of respiratory symptoms led initially to an altered presumed diagnosis of acute cholecystitis. Initial diagnostic work up disclosed elevation of inflammation markers such as raised erythrocyte sedimentation rate (ESR) and C reactive protein (CRP) with acute acalculous cholecystitis. Development of pulmonary symptoms during hospitalization raised the suspicion of Legionella community acquired pneumonia with parapneumonic effusion which was later confirmed by urine for legionella antigen. She started treatment with clarithromycin and improved dramatically.

Key Words: legionella; community acquired pneumonia; acalculous cholecystitis parapneumonic effusion; clarithromycin

Introduction:

Legionella pneumophila is a thin, aerobic, pleomorphic, flagellated, non-spore-forming, Gram-negative bacterium of the genus Legionella. *L. pneumophila* is the primary human pathogenic bacterium in this group. The most common presentation of *Legionella pneumophila* in adult is acute pneumonia (legionellosis), either hospital or community acquired pneumonia [1]. Extrapulmonary disease (such as pericarditis and endocarditis, cholecystitis) is rare¹. Less often, disease presents as a nonpneumonic epidemic, influenza like illness called Pontiac fever [1]. Remarkably, Legionella community acquired pneumonia is of particular severity if not promptly diagnosed and treated, accompanied by a high mortality related burden that reaches up to 27 percent [2]. However its diagnosis remains challenging due to the atypical clinical presentation and the common absence of pulmonary symptoms at onset [3]. Here we present an atypical case of community acquired pneumonia with parapneumonic effusion initially presenting with fever and right upper abdominal pain mimicking acute cholecystitis.

Case Presentation:

A 42 year-old home maker lady, not known to have any comorbidities including diabetes mellitus, hypertension or bronchial asthma was referred to the emergency department of our hospital with a two days history of fever and right upper quadrant abdominal pain. Fever was high grade intermittent, associated with chills and rigor. Maximum recorded temperature was 39.4°C. Abdominal pain was non radiating, moderate to severe in intensity, constant dull ache, increased with movement, deep inspiration and after taking meals with minimum relief after taking proton pump inhibitors or anti spasmotic. Neither her past medical history nor

any travel history was significant. In the emergency department her vital signs were as follows: temperature 102°F, pulse rate 110 beats per minute, respiratory rate 14 breaths per minute, blood pressure 135/90 mmHg and oxygen saturation of 97% while breathing ambient air. Palpation of the abdomen disclosed marked sensitivity with tenderness in the right upper quadrant. Pulmonary auscultation did not reveal any abnormal finding. The rest of the physical examination including neurological and cardiovascular examination were normal.

Chest X ray at admission was normal (Figure 1). Electrocardiogram revealed sinus tachycardia with no other abnormal findings. Initial laboratory work up disclosed: white blood cells 16.55 cells / μ l (normal range: 4-11 cells/ μ l) with 79.8% neutrophils, hemoglobin of 11.7 g/dL (range 12.0-16.0 g/dl), platelet count of $157 \times 10^3/\text{mm}^3$ (range $150-450 \times 10^3/\text{mm}^3$). ESR was 41 mm in 1st hour (normal 0-10 mm in 1st hour). Serum electrolyte showed serum sodium 142 mmol/L (normal range: 136-145 mmol/L), potassium 4.0 mmol/L (normal range: 3.5-5.1 mmol/L). Alanine aminotransferase (ALT) was mildly elevated at 84 IU/L (normal range: 10-40 IU/L). Renal function tests were normal (serum creatinine 1.1 mg/dl, normal 0.6-1.3 mg/dl). Coagulation profile (prothrombin time: patient and control both 12 secs), troponin I (< 0.02 ng/ml) and serum lipase (12U/L, normal 10-60 U/L) were all within normal limits. Measurement of inflammatory markers showed elevated levels of C-reactive protein (117.62 mg/dl, normal <5 mg/dl). An ultrasound of the abdomen detected signs of gallbladder inflammation with gall bladder wall edema with no bright echogenic structure within it (Figure 2) attributed to acute acalculous cholecystitis. Pancreas was normal. Empirical antibiotic therapy was initiated with intravenous administration of ceftriaxone and metronidazole. Three days after

admission her fever persisted. Repeat complete blood count showed white blood cells 21.59 cells / μl (normal range: 4-11 cells/ μl) with 57.2% neutrophils, hemoglobin of 11.6 g/dL (range 12.0-16.0 g/dl), platelet count of $177 \times 10^3/\text{mm}^3$ (range $150-450 \times 10^3/\text{mm}^3$), Erythrocyte

sedimentation rate(ESR) was 50 mm in 1st hour (normal 0-10 in 1st hour). C reactive protein (CRP) was still high (108.67 mg/dl, normal <5 mg/dl). Blood cultures were negative She was switched to meropenem instead of ceftriaxone.

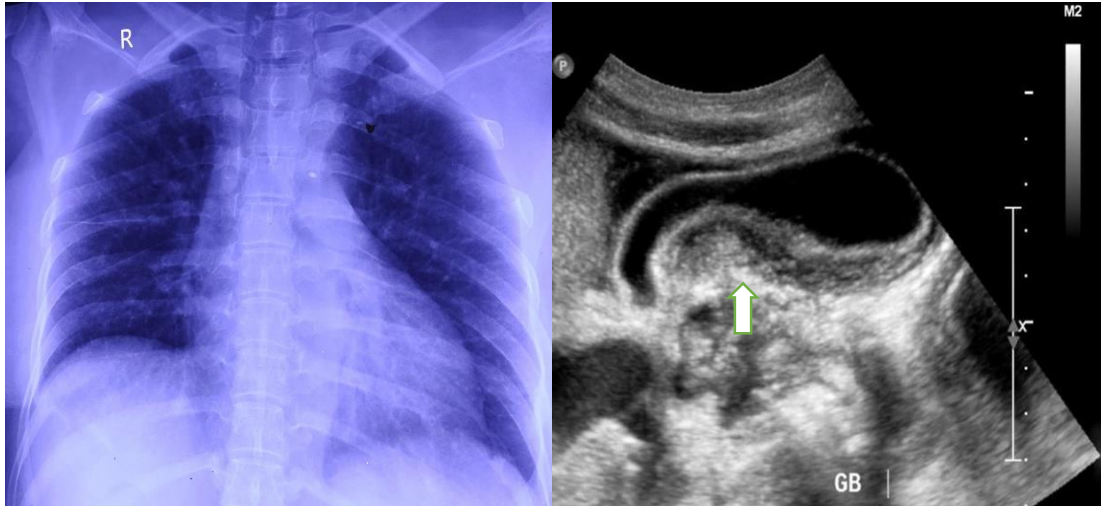


Figure 1 and 2: Chest x ray on presentation with no significant abnormalities and USG of Upper abdomen showing GB mural thickening and hypochoic region within GB wall.

However, on the 8th hospital day, the patient continued to be febrile and complained for pain in the same area with radiation to the right costophrenic angle. Respiratory auscultation revealed diminished breath sounds in the right lower lung fields while percussion showed dullness at the base of the right lung.

Repeat chest x ray was done showing dense homogenous opacity with concave upper margin suggestive of pleural effusion (Figure 3). Pleural fluid study revealed straw colored exudative fluid with protein 4.2 gm/dl, cell count 3200: neutrophil 79%, lymphocyte 20%. ADA(Adenosine deaminase) was 11.20 IU/(normal <25IU/L). A urine antigen test for

legionella was sent which came positive on the 10th hospital day and the antibiotic regimen was changed to clarithromycin 500 mg twice daily for two weeks. During his follow up after two weeks, she was asymptomatic, CBC showed white blood cells 8.16cells / μl (normal range: 4-11 cells/ μl) with 44.6% neutrophils, hemoglobin of 11.4 g/dL(range 12.0-16.0 g/dl), platelet count of $427 \times 10^3/\text{mm}^3$ (range $150-450 \times 10^3/\text{mm}^3$), Erythrocyte sedimentation rate ESR was 20 mm in 1st hour(normal 0-10 in 1st hour), C reactive protein (CRP) was normal(4.08 mg/dl, normal <5 mg/dl). Repeat chest x ray showed a full remission of the pathological findings (Figure 4).

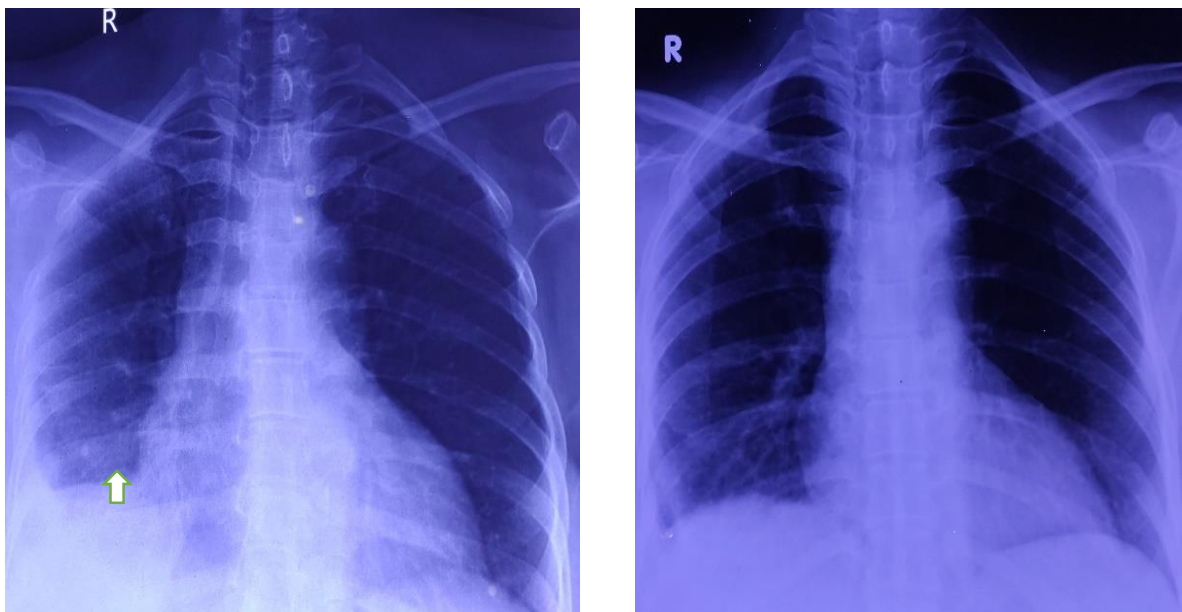


Figure 3 and 4: Chest x ray on 5th day showing right sided effusion and complete resolution of effusion 10 days after clarithromycin therapy.

Discussion:

Legionella was first recovered from the blood of a soldier more than 50 years ago [6], but its importance as a human pathogen was not recognized until 1976, when a mysterious epidemic of pneumonia struck members of the Pennsylvania American Legion. The clinical manifestations of *Legionella* infections are primarily respiratory. Clinical characteristics of *Legionella* pneumonia vary from a mild infection to severe pneumonia that often requires admission to the intensive care unit [3]. Non-specific systemic symptoms such as high grade fever, arthralgias or myalgia, headache, anorexia and confusion are usually present at onset [3]. Furthermore, gastrointestinal symptoms develop frequently and include nausea, vomiting, abdominal pain and diarrhea [3]. Typical respiratory symptoms that may develop in the course of the disease include dry cough, dyspnoea and less frequently pleuritic chest pain and hemoptysis³. In case of clinical aggravation, symptomatology reminds pneumonia with productive cough, dyspnea and pleuritic chest pain [4]. Most patients respond promptly to appropriate antimicrobial therapy, but convalescence is often prolonged (lasting many weeks or even months). The second form of respiratory illness is called Pontiac fever after the city in Michigan where the first epidemic was recognized. This uncommon manifestation of infection resembles acute influenza, including fever, headache, and severe muscle aches. It is self-limited, and convalescence is uneventful.

The epidemiology of *Legionella* infections is a complex equation that is composed of the aquatic environment (including representatives of multiple microbial phyla, humans, mechanical devices and medical facilities), dissemination from the environment to the host, and host susceptibility. The complexity of the environmental interactions rivals those of viral and parasitic infections. The only documented source of *Legionella* species is water, particularly the surface waters of rivers and lakes and drinking water [3].

There are no reliable distinguishing clinical features of *Legionella* pneumonia, so the diagnosis must come from the laboratory. Some clinical features suggest legionnaire's disease; however, and should prompt the selection of appropriate laboratory tests. The diagnosis is confirmed in the laboratory by culture, demonstration of bacterial antigen in body fluids including urine, or detection of a serologic response.

In regards to laboratory characteristics of legionellosis, liver and renal function test abnormalities, thrombocytopenia and leukocytosis are frequently present [3]. Hyponatremia secondary to diarrhea and loss of water and sodium may also occur [5]. The preferred diagnostic method is culturing, because it is both sensitive and specific; however, appropriate specimens are not always available. The medium of choice is buffered charcoal-yeast extract - α -ketoglutarate medium. The gold standard tool for the diagnosis of *Legionella pneumophila* serogroup 1 infection is the urine antigen test since it is characterized by high sensitivity and specificity (of over 95 percent) [6]. It is not influenced by antibiotherapy and remains positive for weeks after infection³. For diagnostic confirmation of legionellosis acute and convalescent serology is useful to be tested. A fourfold increase in titres to 1:128 within 4 weeks is considered positive [3]. It should be considered as an adjunct to diagnosis by culture. Cross-reactions among *Legionella* species and serogroups make assignment of a species-specific diagnosis impossible on serologic grounds.

Currently, the most efficient antibiotics are considered macrolides or fluoroquinolones [7]. Intravenous administration of azithromycin is strongly suggested [3]. In complex cases the later can be combined with a quinolone or rifampicin [3]. Duration of antibiotic therapy is 2 weeks in immunocompetent adults with extension to 3 weeks in immunocompromised hosts [3].

Prompt detection of *Legionella* infection and timely administration of appropriate antibiotic therapy in the patient admitted to the acute care setting is of crucial importance [8]. However, as in our case, early diagnosis can be difficult when respiratory symptoms are lacking [3] and clinical manifestations are not reliable [8]. This leads frequently to an alternate diagnosis and the appropriate antibiotic therapy is delayed [3]. In the same direction, clinical criteria proposed for the diagnosis of Legionellosis are of limited usefulness in the emergency care setting since they present low sensitivity and specificity of less than 80 percent [9]. However, it has been reported that high grade fever, the presence of gastrointestinal symptoms that precede respiratory manifestations, hyponatremia and hepatic dysfunction are key clinical clues that can trigger the diagnostic suspicion [3]. In alignment, in a retrospective study that assessed the likelihood of *Legionella* community acquired pneumonia in patients presenting to the emergency department were reported six parameters (high body temperature, absence of sputum production, low serum sodium concentrations, high levels of lactate dehydrogenase and C-reactive protein and low platelet counts) that could independently predict the accurate detections of patients with *Legionella* community acquired pneumonia [8]. Additionally, lack of patient's response to previous beta-lactam antibiotics, severe hyponatremia, and elevation of creatinine kinase levels and absence of expectorative cough are important features in order physicians consider *Legionella* infection in their differential diagnosis [10].

In the case reported here, due to the absence of early respiratory symptoms, chest x ray was overlooked and the diagnostic work-up was orientated towards imaging investigation of the abdomen. Therefore the non-specific clinical presentation led to an inaccurate diagnosis and management in the emergency care setting. Similarly, in a case series have been reported that patient's systemic symptoms masked the accurate diagnosis in the emergency setting [3, 11]. More specifically they had received altered diagnoses such as acute cholecystitis and bacterial meningitis [3, 11].

Conclusion:

Emergency care physicians have to be aware and consider *Legionella* community acquired pneumonia in the differential diagnosis of right flank pain and fever even in the absence of respiratory symptoms. Awareness of the unreliable systemic clinical features of patients with legionellosis at onset in combination with a careful clinical examination as well as methodological appraisal of the laboratory findings may assist in timely diagnosis.

References:

1. Franzin L, Cabodi D, Scolfaro C, et al. (2004) Microbiological investigations on a nosocomial case of *Legionella pneumophila* pneumonia associated with water birth and review of neonatal cases. *Infez Med.* 12:69–75.
2. Falco V, Fernandez de Sevilla T, Alegre J, et al. (1991) *Legionella pneumophila*. A cause of severe community acquired pneumonia. *Chest.* 100:1007–1011.
3. Darby J, Buising K. (2008) Could it be *Legionella*? *Aust Fam Physician.* 37:812–815.
4. Stanley P, Yung A. (1989) Community acquired pneumonia in older children and adults. In: Kincaid-Smith P, Larkins R, Whelan G, editors. *Problems in clinical medicine*, 2nd edition. Sydney: MacLennan and Petty. 347–356.
5. Birkin C, Biyani CS, Browning AJ. (2011) *Legionella* pneumonia presenting with bilateral flank pain, hyponatraemia and acute renal failure. *Can Urol Assoc J.* 5:96–100.
6. Stout JE, Yu VL. (1997) Legionellosis. *N Engl J Med.* 337:682–687.

7. Carratalà J, Garcia-Vidal C. (2010) An update on Legionella. *Curr Opin Infect Dis.* 23:152–157.
8. Fiumefreddo R, Zaborsky R, Haeuptle J, et al. (2009) Clinical predictors for Legionella in patients presenting with community-acquired pneumonia to the emergency department. *BMC Pulm Med.* 9:4.
9. Gupta SK, Imperiale TF, Sarosi GA. (2001) Evaluation of the Winthrop-University Hospital criteria to identify Legionella pneumonia. *Chest.* 120:1064–1071.
10. opena N, Sabria-Leal M, Pedro-Botet ML, et al. (1998) Comparative study of the clinical presentation of Legionella pneumonia and other communityacquired pneumonias. *Chest.* 113:1195–1200.
11. Busing K, O'Reilly M, Paull A, et al. (2001) Legionella pneumophila: not just pneumonia. *Med J Aust.* 174:476–477.



This work is licensed under Creative Commons Attribution 4.0 License

To Submit Your Article Click Here: [Submit Article](#)

DOI: [10.31579/2690-4861/052](https://doi.org/10.31579/2690-4861/052)

Ready to submit your research? Choose Auctores and benefit from:

- ❖ fast, convenient online submission
- ❖ rigorous peer review by experienced research in your field
- ❖ rapid publication on acceptance
- ❖ authors retain copyrights
- ❖ unique DOI for all articles
- ❖ immediate, unrestricted online access

At Auctores, research is always in progress.

Learn more www.auctoresonline.org/journals/international-journal-of-clinical-case-reports-and-reviews