

## Signet Ring Cell Neuroendocrine Tumor

Sabbah M<sup>1</sup>\*, Trad D<sup>2</sup>, Bellil N<sup>2</sup>, Jouini R<sup>2</sup>, Ouakaa A<sup>2</sup>, Elloumi H<sup>2</sup>, Bibani N<sup>2</sup>, Gargouri D<sup>2</sup>

<sup>1</sup>Departement of gastroenterology. Habib Thameur Hospital

<sup>2</sup>Departement of pathology. Habib Thameur Hospital

\*Corresponding author: Sabbah Meriam, Departement of gastroenterology. Habib Thameur Hospital. Email: [sabbah\\_meriam@yahoo.fr](mailto:sabbah_meriam@yahoo.fr)

Received Date: November 8, 2019; Accepted Date: November 12, 2019; Published Date: November 29, 2019

Citation: Sabbah M, Trad D, Bellil N, Jouini R, Ouakaa A. et al. (2019) Signet ring cell neuroendocrine tumor. Surgical Case Reports and Images, 2(1); Doi:10.31579/JSCR/2019/009

Copyright: ©2019. Sabbah Meriam. This is an open-access article distributed under the terms of the Creative Commons Attribution License, which permits unrestricted use, distribution, and reproduction in any medium, provided the original author and source are credited.

### Case report

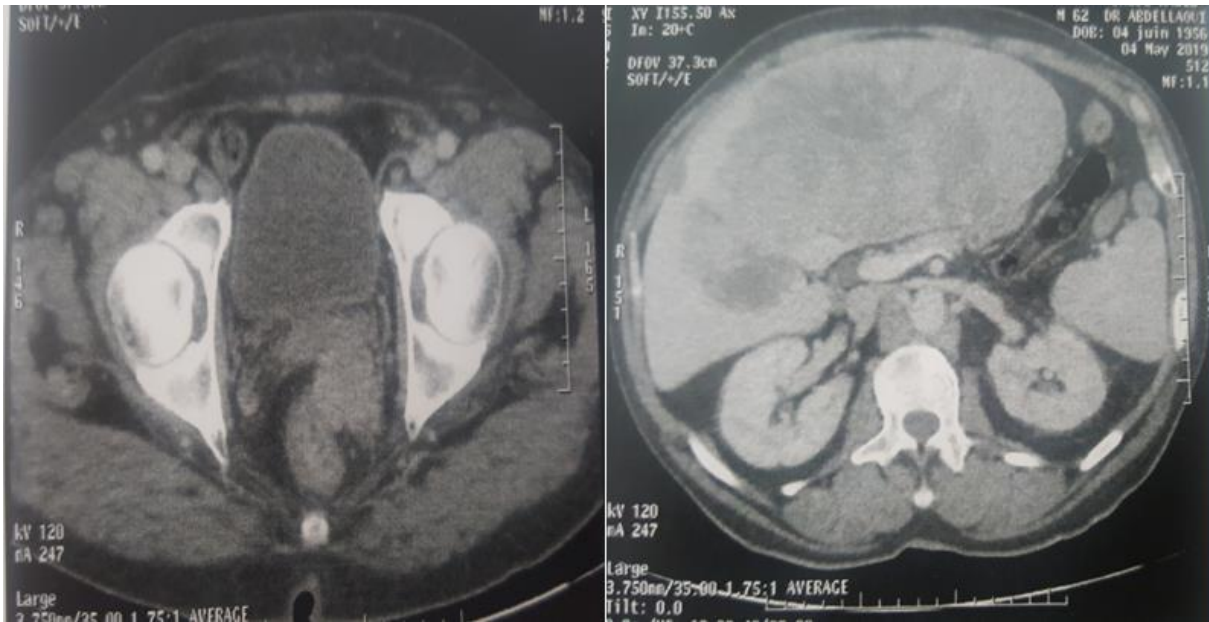
A 63 years old woman with history of diabetes and hypertension, presented for bone pain. Pelvic X Ray showed multiple osteoconsent lesions of the iliac wings, the sacrum and the femurs (figure 1). CT scan objectified multiple hepatic metastases with a laterorectal mass (figure 2). Colonoscopy showed aspect of extrinsic compression. Endoscopic

ultrasound objectified a rectal mucosal lesion of 5x3,5 centimeters appearing in contact with the prostate (figure 3). Histologically, hepatic biopsy confirmed a tumor proliferation that was made of two architectural aspects independent cells, and trabeculolobular classical endocrine architecture with expression of synaptophysin on immunochemistry (figure 4).

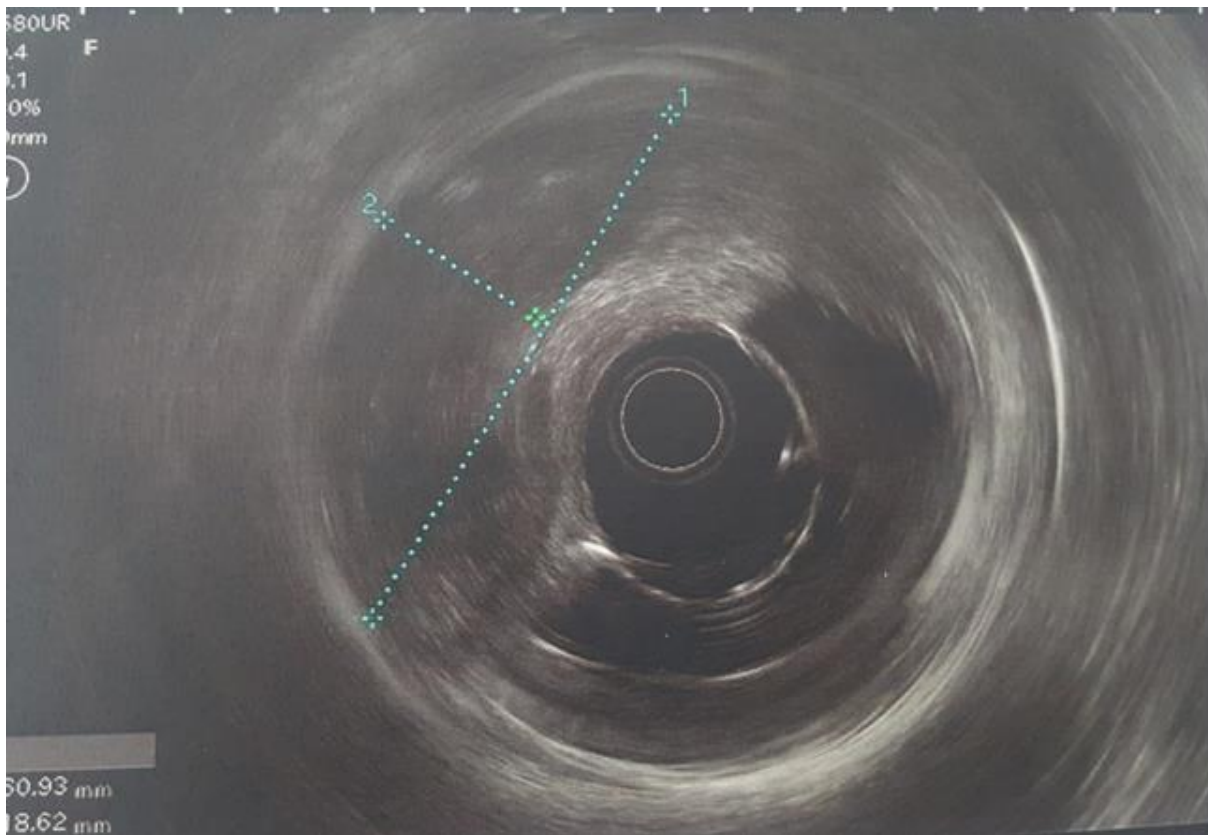
### Figures

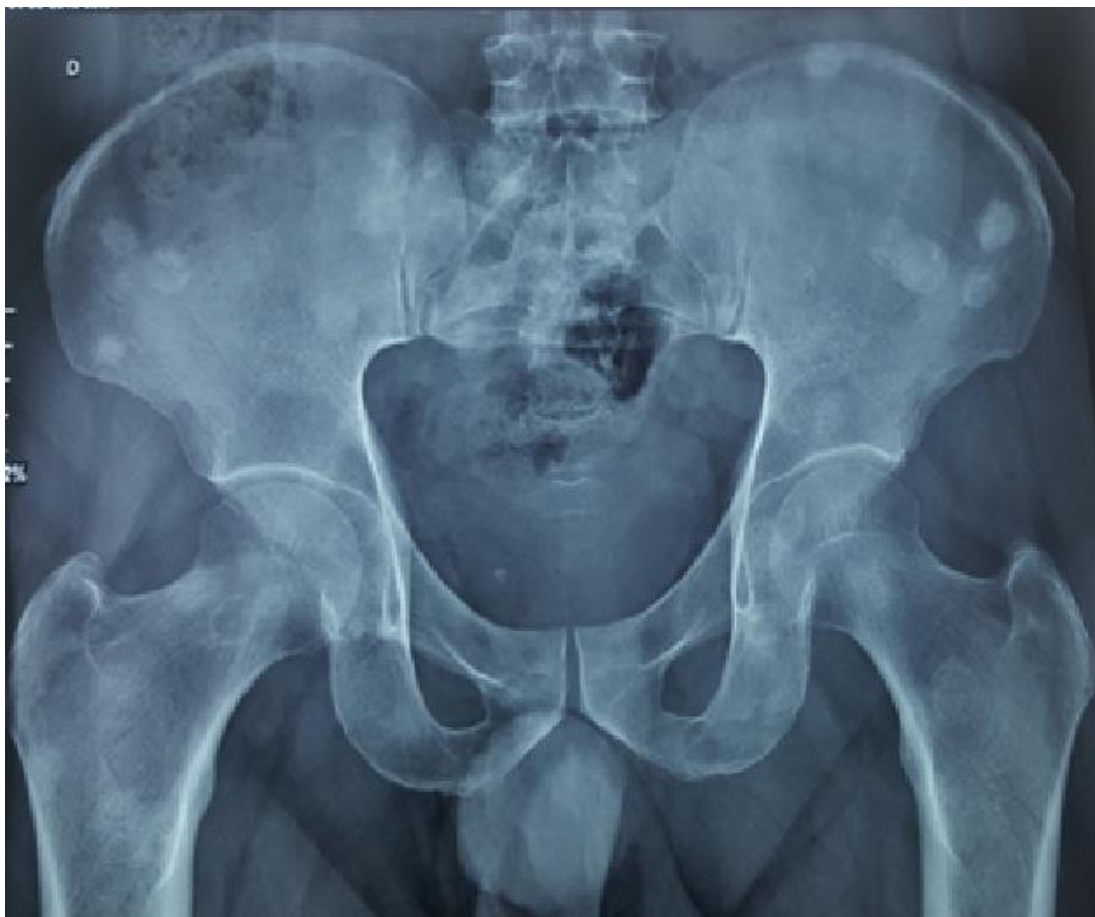

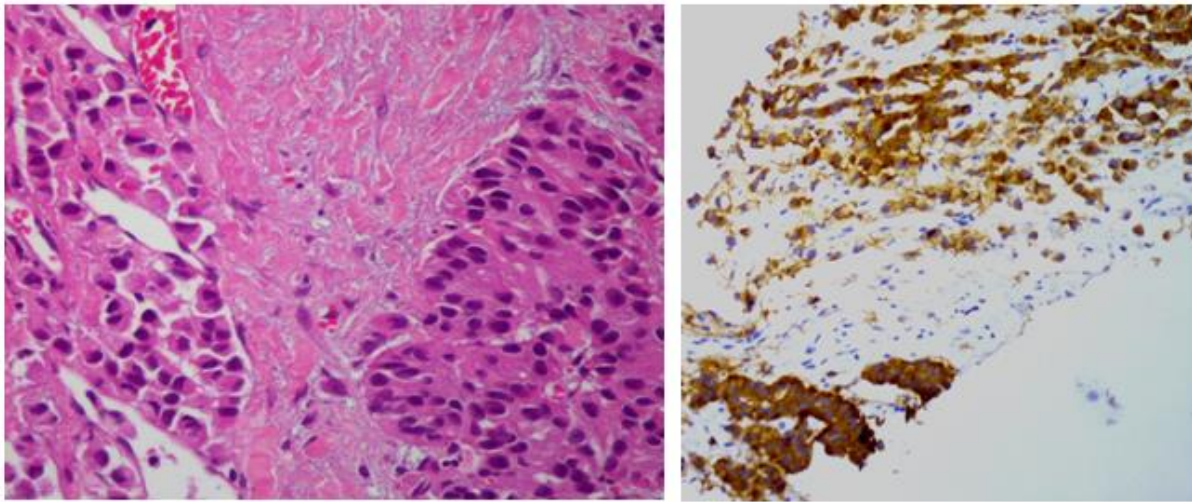
Figure 1: Pelvic X Ray showed multiple osteoconsent lesions of the iliac wings, the sacrum and the femurs



**Figure 2:** CT scan objectified multiple hepatic metastases with a laterorectal mass



**Figure 3:** Endoscopic ultrasound objectified a rectal mucosal lesion of 5x3, 5 centimeters appearing in contact with the prostate



**Figure 4:** hepatic biopsy showing a tumor proliferation that was made of two architectural aspects independent cells, and trabeculolobular classical endocrine architecture with expression of synaptophysin on immunochemistry

## References

1. Haq S, Batra VV, Majumdar K, Javed A, Agarwal AK. et al (2015) Signet ring cell neuroendocrine tumor liver with mesenteric metastasis: Description of a rare phenomenon, with literature review *J Cancer Res Ther.*, 11(3):658.
2. Madakshira MG, Radotra BDn Singh V. *Indian J Pathol Microbiol.* (2019) Signet ring: A rare morphology of metastatic neuroendocrine tumor. (62): 335-336.
3. Shaieb W, Krishna K, Kim S, Godman M, Rock J, Chen Z and al. (2016) Appendiceal Neuroendocrine, Goblet and Signet-Ring Cell Tumors: A Spectrum of Diseases with Different Patterns of Presentation and Outcome. *Cancer Res Treat.* 48 (2): 596-604
4. He F, Nie L. (2019) Synchronous neuroendocrine tumor and signet-ring cell carcinoma in the stomach. *Clinics and research in hepatology and gastroenterology.* (43): 505-507.
5. Korphaisarn, K., Morris, V., Davis, J.S and al. (2019) Signet ring cell colorectal cancer: genomic insights into a rare subpopulation of colorectal adenocarcinoma. *Br J Cancer* (121), 505–510