

# Two macro-vascular thrombotic complications in a single patient due to COVID-19 treated successfully: case report

Ahmad Fouad Mady<sup>1,3</sup>, Muhammad Asim Rana<sup>2</sup>, Alfateh M. Noor<sup>1\*</sup>, Ahmed H Kuhail<sup>1</sup>, Mohammed Haddad Lhmdi<sup>1</sup>, Waleed Tharwat Al-Etreby<sup>1</sup>, Abdulrahman Mishaal Alharthy<sup>1</sup>

<sup>1</sup>Department of Critical Care Medicine, King Saud Medical City, Riyadh, Saudi Arabia.

<sup>2</sup>Department of Critical Care Medicine, Bahria International Hospital, Lahore, Pakistan.

<sup>3</sup>Department of Anesthesiology and ICU, Tanta University Hospitals, Tanta, Egypt.

\*Corresponding Author: Alfateh M. Noor, 1Department of Critical Care Medicine, King Saud Medical City, Riyadh, Saudi Arabia.

Received date: August 14, 2020; Accepted date: September 04, 2020; Published date: September 08, 2020

**Citation:** A F Mady, M A Rana, A M. Noor, Ahmed H K, Mohammed H L et al. (2020) Two macro-vascular thrombotic complications in a single patient due to COVID-19 treated successfully: case report. International Journal of Clinical Case Reports and Reviews. 3(3); DOI: [10.31579/2690-4861/049](https://doi.org/10.31579/2690-4861/049)

**Copyright:** © 2020 Alfateh M. Noor, This is an open-access article distributed under the terms of the Creative Commons Attribution License, which permits unrestricted use, distribution, and reproduction in any medium, provided the original author and source are credited.

## Abstract

Human infection with Sars CoV-2 named COVID-19 by WHO causes micro and macro vascular thrombosis which is one of the major complications along with Acute Respiratory Distress Syndrome (ARDS). Although the mechanisms involved are poorly understood but appear to consist of a cascade of inflammation with involvement of many inflammatory cytokines, coagulation factors and platelets and results in some kind of immune-thrombosis. The thrombotic and thrombo-embolic events have caused major morbidities and mortalities and have been topic of extensive research in present pandemic. Timely recognition of these events and intervention with anticoagulation has been the key to successful management of critically ill COVID-19 patients.

**Keywords:** covid-19; arterial thrombosis; critical limb ischemia; ischemic stroke; severe acute respiratory syndrome coronavirus 2

## Introduction:

Infection with Sars CoV-2 (also called COVID-19) has been known to cause severe respiratory infection which can lead to respiratory failure and death if no prompt intervention is done to save life. Other significant morbidity and mortality caused by this infection is due to its tendency to make clots. The patients infected with Corona virus 2 are especially prone to develop clots owing to its immune mediated thrombogenesis. We present a case who had two major thromboembolic events simultaneously but was saved due to in time intervention carried out.

## Case Report:

A 38-year-old female with a past medical history of Diabetes Mellitus presented to Emergency room of a regional secondary care hospital with complaints of acute painful discoloration of her right arm. Pain had developed suddenly and was excruciating in severity and her arm turned pale and the tips of fingers turned blue. Patient was urgently transferred to our hospital which is a tertiary care referral center for limb saving procedure.

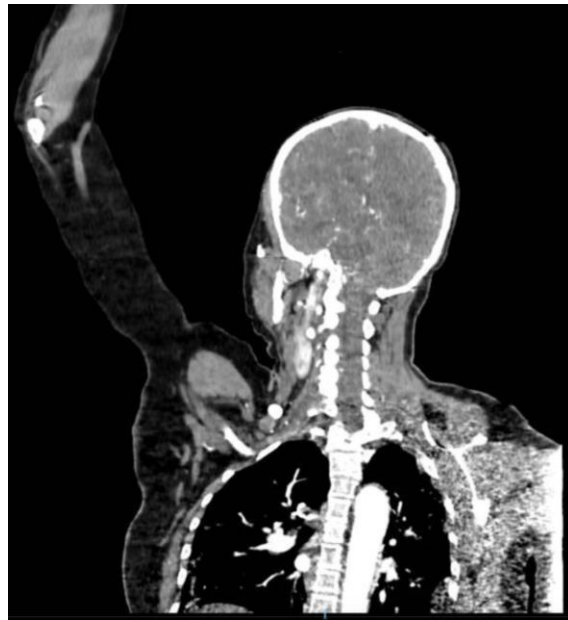During transfer her conscious level deteriorated and she became unconscious.

At presentation she has unconscious with and GCS of 8/15, her right arm was pale, cold to touch and her hand was cyanosed.

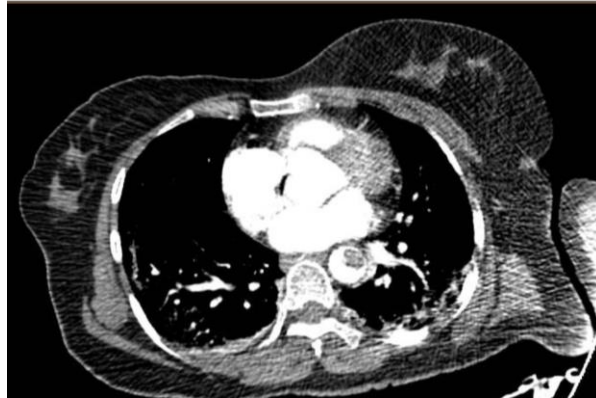Vital signs on presentation were: heart rate 108 /min, blood pressure 120 /80 mmHg, oxygen saturation 95% on room air, and temperature 37°C.

The patient had bilateral crackles on lung auscultation and an absent right arm pulses from axillary artery downwards.

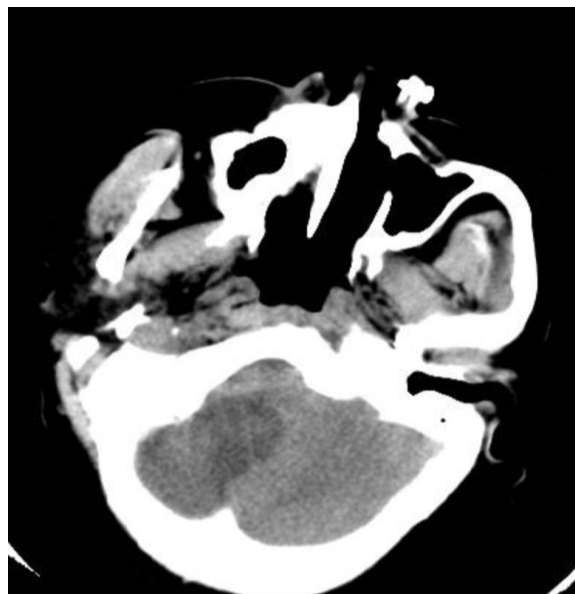
Urgent CT Brain and angiogram of limb was performed and she was found to have posterior circulation stroke [figure 3], Brain edema and obstructed hydrocephalus along with multiple filling defects (thrombi) seen at the Descending Thoracic Aorta [figure 2], Brachycephalic and right Subclavian arteries with no contrast opacification seen at the proximal right axillary as it was completely occluded hence there was no flow in distal right upper limb arteries [figure 1].



**Figure 1** CT angiogram descending aorta thrombosis. And axillary artery thrombosis



**Figure 2** CT angiogram descending aorta thrombosis.



**Figure 3** CT brain without contrast is showing occipital ischemia infarction.

She had bilateral basal crackles and her CT chest showed peripheral ground glass opacities and diagnosis of COVID-19 was confirmed as her nasopharyngeal swab for Sars CoV-2 came positive.

All her biochemical profile was favoring COVID-19 with raised CRP, D-Dimers and Ferritin (see table 1) While a search for thrombophilia screening turned out to be negative (Table 2).

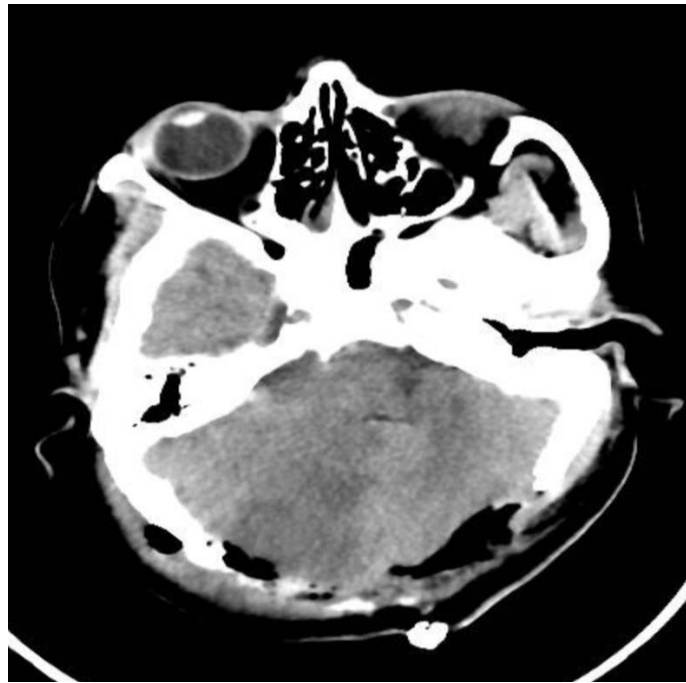
**Table 1**

Blood test	Normal range	Result
Complete Blood Count		
White cell count	4.0 – 11 x 10 <sup>9</sup> /L	11.1 x 10 <sup>9</sup> /L
Platelet	140-400 10 <sup>9</sup> /L	241 x 10 <sup>9</sup> /L
Prothrombin time	11-14.5 sec	14.4
Activated prothrombin time a(PTT)	26-40 sec	31.4
INR	0.8-1.2	1.13
D – dimer	0-0.5 g/L FEU	1.52
Fibrinogen	1.8-3.6 g/l	5.51
Renal function test		
Urea	2.5 – 6.4 mmol/L	5.59
Lactate	< 2 mmol/L	1.4
Creatinine	71 – 115 umol/L	51
Inflammatory markers		
C – reactive protein	0-10 mg/L	105
Creatine Kinase (CK)	39-308 U/L	30
Serum Ferritin	30-300	780
ESR		120

**Table 2**

Thrombophilia screening	
Test & Value	Result
B2- Glycoprotein 1 IgG (U/ml)	negative
Anti MPO (p-ANCA) (AU/ml)	negative
B2- Glycoprotein 1 IgM (U/ml)	Equivocal
C3	1.34
C4	0.294
Factor VII (60-150 sec)	16
Factor V leiden APCR (120-300 sec)	153
Protein C (70-130 % of normal)	107
Protein S (55-140 % of normal)	54
Anti-thrombin (80-120)	109
ANA	Negative
Lupus anticoagulant	negative

Patient underwent decompressive craniectomy [figure 4] and endarterectomy of right axillary artery. Unfortunately, the vessel got another thrombus in embolectomy was done again.



**Figure 4** CT brain without contrast post decompressive craniotomy.

It took us two weeks to take her off from ventilator but she made good recovery afterwards and was successfully discharged home.

### Discussion:

Severe Acute Respiratory Syndrome Coronavirus 2 (SARS-CoV-2) is a coronavirus infection which causes respiratory infection in human beings, labeled as COVID-19 by the World Health Organization (WHO) [1].

The clinical gamut of COVID-19 is very broad, varying from minor indeterminate symptoms, such as fever, dry cough, diarrhea, mild pneumonia and mild dyspnea, to severe pneumonia accompanied by dyspnea, tachypnea and severe respiratory failure with necessity of ventilation to sustain life, shock or multiple organ failure in roughly 5% of patients [2].

Amidst the many parameters analogous to poor prognosis, high levels of D-Dimers have proven to be particular indicators of the development of acute respiratory distress syndrome (ARDS) with the need for admission to intensive care, or may lead to death [3].

Infectious complications in critically ill patients are known to activate multiple systemic coagulation and inflammatory responses that are vital for host defense but can lead to DIC [4, 5].

The details of the agents or mechanisms responsible for the activation of coagulation cascade in patients of COVID 19 are thus far poorly understood, but appear to be connected to inflammatory responses generated by body itself rather than particular properties of the coronavirus.

Patients inflicted with SARS-CoV-2 display significant inflammation, evident from raised levels of C-reactive Protein (CRP), Erythrocyte Sedimentation Rate (ESR), and fibrinogen, pro-inflammatory cytokines (i.e., IL-2, IL6, IL-7, IL-10, G-CSF, IP-10, MCP-1, MIP-1A and TNF- $\alpha$ ), but it is yet unclear what causes the cytokine outburst.

All the aforementioned components of inflammatory response show a mutual relationship between thrombosis and inflammation, as these two

processes augment each other because both coagulation factors (pro- and anti-coagulants) and platelets are directly involved in the regulation of the host immune response, as well as in thrombogenesis. Hence, the terms thromboinflammation or immunothrombosis have been coined [6,7].

Interestingly complement factors also affect the activation of the coagulation [8]. Situation becomes more serious when coagulation can lead to consumptive coagulopathy and disseminated intravascular coagulation (DIC) which is evident from raised fibrinogen levels in a severely ill covid-19 patient (10-14 g/L), compared with normal (2-4 g/L). The International Society of Thrombosis and Hemostasis (ISTH) has introduced diagnostic criteria for overt DIC and has developed and validated a sepsis-induced coagulopathy (SIC) score [9-11] If the underlying etiology of sepsis is not resolved SIC can progress to DIC [12]

In a recent Dutch study by Iba T et al. 49% of patients out of a total of 184 admitted to an intensive care unit displayed occurrence of thrombotic complications- majorly diagnosed on computed tomography pulmonary angiograms (CTPA) [12].

Additionally, studies from France and the Netherlands have also reinforced that thrombosis is a major complication, incident in 20-30% of critically ill COVID-19 patients, despite prophylaxis [13, 14, 15].

Postmortem studies of COVID-19 patients have discovered clots in the lung capillaries, which limit the flow of oxygenated blood through the lungs [16].

Clinically speaking, the systemic hypercoagulability and the possibility of thromboembolic complications, and the discussed microvascular and endothelial injury with microcirculatory clot formation observed in post-mortem evaluation are congruous with the occurrence of thrombotic microangiopathy in patients.

Such patients (with newly confirmed and presumptive COVID-19 infection) should have coagulation testing performed on admission, along with D-dimers, PT, aPTT, Fibrinogen, platelet count and tests that can provide useful prognostic information.

The increased levels of D-Dimers connected to non-survivors, and the rapid fall in fibrinogen levels associated with DIC, can be observed within 7 to 11 days after the onset of symptoms or 4 to 10 days post-hospitalization [17].

### Conclusion:

The incidence of thromboembolic complication in COVID-19 is high. Until definitive evidence is confirmed, attention to it need to be paid in order to avoid drastic consequences. We think pharmacologic VTE prophylaxis should be considered and more studies are strongly advised.

### Funding

This research did not receive any specific grant from funding agencies in the public, commercial, or not-for-profit sectors.

### Declaration of conflicting interest

The authors declare no conflicts of interest in preparing this article.

### Ethical approval

The study was approved by the Ethics committee of the hospital. Written informed consent was obtained from the patient.

### References

1. Wu F, Zhao S, Yu B, et al. (2020) A new coronavirus associated with human respiratory disease in China [published correction appears in *Nature*.;580(7803): E7]. *Nature*. 2020; 579(7798):265-269.
2. Wu Z, McGoogan JM. (2020) Characteristics of and important lessons from the coronavirus disease 2019 (COVID-19) outbreak in China: summary of a report of 72,314 cases from the Chinese Center for Disease Control and Prevention. *JAMA*.
3. Tang N, Li D, Wang X, Sun Z. (2020) Abnormal coagulation parameters are associated with poor prognosis in patients with novel coronavirus pneumonia. *J Thromb Haemost*. 18: 844-847.
4. Iba T, Levy JH, Wada H, Thachil J, Warkentin TE, Levi M. (2019) Subcommittee on Disseminated Intravascular Coagulation. Differential diagnoses for sepsis-induced disseminated intravascular coagulation: communication from the SSC of the ISTH. *J Thromb Haemost*. 17(2):415-419.
5. Iba T, Levy JH, Thachil J, Wada H, Levi M. (2019) Scientific and Standardization Committee on DIC of the International Society on Thrombosis and Haemostasis. The progression from coagulopathy to disseminated intravascular coagulation in representative underlying diseases. *Thromb Res*. 179:11-14.
6. Sarzi-Puttini P, Giorgi V, Sirotti S et al. (2019) COVID-19, cytokines and immunosuppression: what can we learn from severe acute respiratory syndrome? *Clin Exp Rheumatol* 202; 38: 337-342.
7. Jackson SP, Darbousset R, Schoenwaelder SM, et al. (2017) Thromboinflammation: challenges of therapeutically targeting coagulation and other host defense mechanisms. *Blood*. 133: 906-918.
8. Subramaniam S, Jurk K, Hobohm L, et al. Distinct contributions of complement factors to platelet activation and fibrin formation in venous thrombus development. *Blood*. 129(16):2291-2302
9. Iba T, Levy JH. (2018) Inflammation and thrombosis: roles of neutrophils, platelets and endothelial cells and their interactions in thrombus formation during sepsis. *J Thromb Haemost*.16 (2):231-241.
10. Suzuki K, Wada H, Imai H, Iba T, Thachil J, Toh CH. (2018) Subcommittee on Disseminated Intravascular Coagulation. A re-evaluation of the D-dimer cut-off value for making a diagnosis according to the ISTH overt-DIC diagnostic criteria: communication from the SSC of the ISTH. *J Thromb Haemost*.16 (7):1442-1444.
11. Taylor FB Jr, Toh CH, Hoots WK, Wada H, Levi M. (2001) Scientific Subcommittee on Disseminated Intravascular Coagulation (DIC) of the International Society on Thrombosis and Haemostasis (ISTH). Towards definition, clinical and laboratory criteria, and a scoring system for disseminated intravascular coagulation. *Thromb Haemost*.86 (5):1327-1330.
12. Iba T, Levy JH, Yamakawa K, Thachil J, Warkentin TE, Levi M. (2019) Scientific and Standardization Committee on DIC of the International Society on Thrombosis and Haemostasis. Proposal of a two-step process for the diagnosis of sepsis-induced disseminated intravascular coagulation. *J Thromb Haemost*.17 (8):1265-1268.
13. Klok F, Kruip M, van der Meer N, et al. (2020) Confirmation of the high cumulative incidence of thrombotic complications in critically ill ICU patients with COVID 19. *Thromb Res*.
14. Middeldorp S, Coppens M, van Haaps TF, et al. (2020) Incidence of venous thromboembolism in hospitalized patients with COVID-19. *J Thromb Haemost*.
15. Poissy J, Goutay J, Caplan M, et al. Lille ICU Haemostasis COVID-19 group. Pulmonary embolism in covid-19 patients: awareness of an increased prevalence. *Circulation* 2020.
16. Wise J. (2020) Covid-19 and thrombosis: what do we know about the risks and treatment? *BMJ*. m2058.
17. Zhou F, Yu T, Du R, et al. (2020) Clinical course and risk factors for mortality of adult inpatients with COVID-19 in Wuhan, China: a retrospective cohort study. *Lancet*.395 (10229): 1054-1062.
18. Bikdeli B, Madhavan MV, Jimenez D, et al. COVID-19 and thrombotic or thromboembolic disease: implications for prevention, antithrombotic therapy, and follow-up. *J Am Coll Cardiol*.
19. Wada H, Thachil J, Di Nisio M, et al. (2013) The Scientific Standardization Committee on DIC of the International Society on Thrombosis Haemostasis. Guidance for diagnosis and treatment of disseminated intravascular coagulation from harmonization of the recommendations from three guidelines. *J Thromb Haemost*.11 (4):761-767.
20. Thachil J, Tang N, Gando S, et al. (2020) ISTH interim guidance on recognition and management of coagulopathy in COVID-19. *J Thromb Haem*.18 (5):1023-1026.
21. Jean M. Connors, Jerrold H. Levy. (2020) COVID-19 and its implications for thrombosis and anticoagulation. *Blood*. 135 (23): 2033–2040.



This work is licensed under Creative Commons Attribution 4.0 License

To Submit Your Article Click Here: [Submit Article](#)

DOI: [10.31579/2690-4861/049](#)

**Ready to submit your research? Choose Auctores and benefit from:**

- ❖ fast, convenient online submission
- ❖ rigorous peer review by experienced research in your field
- ❖ rapid publication on acceptance
- ❖ authors retain copyrights
- ❖ unique DOI for all articles
- ❖ immediate, unrestricted online access

At Auctores, research is always in progress.

Learn more [www.auctoresonline.org/journals/international-journal-of-clinical-case-reports-and-reviews](http://www.auctoresonline.org/journals/international-journal-of-clinical-case-reports-and-reviews)