

Pleomorphic adenoma of the nasal cavity

I. Brudasca¹, I. Beschet² and G. Buiret^{1*}

¹ Service d'ORL et de chirurgie cervicofaciale, Centre Hospitalier de Valence, 179 Boulevard du Maréchal Juin, 26953 Valence, France.

² Service d'anatomopathologie, Centre Hospitalier de Valence, 179 Boulevard du Maréchal Juin, 26953 Valence, France.

***Corresponding Author:** G Buiret, Service d'ORL et de chirurgie cervicofaciale, Centre Hospitalier de Valence, 159 Boulevard du Maréchal Juin, 26953 Valence.

Received date: January 24, 2021: Accepted date: February 26, 2021: Published date: March 09, 2021

Citation: Brudasca I, Beschet. I, Buiret G.(2021) Pleomorphic adenoma of the nasal cavity. *J. of Clinical Otorhi* 3(1); DOI: [10.31579/2692-9562/026](https://doi.org/10.31579/2692-9562/026)

Copyright: © 2021, G Buiret. This is an open access article distributed under the Creative Commons Attribution License, which permits unrestricted use, distribution, and reproduction in any medium, provided the original work is properly cited.

Abstract

Pleomorphic adenomas represent 80% of the salivary gland's benign tumors. They are most often found in the parotid gland or in the submandibular gland. Pleomorphic adenomas of the nasal cavity are rare, with less than fifty cases reported to date. There are no treatment or follow up guidelines. The purpose of this article is to review the cases already described in the literature and to share our clinical experience.

We describe the case of a 38-year-old woman with a history of a slow growing intranasal tumor with recurrent epistaxis, obstruction, and aesthetic deformation. The pre-operative assessment suggested a benign tumor, but the biopsies were inconclusive. The decision was taken to perform an open rhinoplasty to have an en bloc resection with margins control. The diagnosis of pleomorphic adenoma was established on the excised tumor. There were no post-operative complications. The early follow-up showed no signs of recurrence. We decided to closely follow the patient with frequent clinical examinations and yearly enhanced-MRIs for at least five years due to the recurrence and malignant transformation risks.

Key words: pleomorphic adenoma, intra-nasal tumor, salivary gland tumors, carcinoma ex pleomorphic adenoma, chronic epistaxis

Introduction

Salivary gland tumors are rare, they represent around 3 % of all neoplasms. They are mainly located within the major salivary glands. Pleomorphic adenomas (PAs) represent 80% of benign tumors and are mostly found in the parotid gland or in the submandibular gland. Only 8 to 10 % of PAs grow in the minor salivary glands [1, 2].

PAs are benign tumors which are at a risk of transforming into malignant tumors, mostly into carcinoma ex pleomorphic adenoma [3]. In the literature [1, 4], this risk is estimated between 0% and 6% and increases further when the diagnosis of the tumor is delayed. If there is a malignant change, the prognosis gets worse, with a 5 years survival rate ranging between 30 to 50% [2].

Only a few case reports and case series have described PAs of the sinusonasal tract. There are no clear guidelines today regarding their diagnosis, treatment and follow up.

Having managed of a case of a woman with a pleomorphic adenoma of the nasal cavity, we therefore aim to describe its clinicopathological

characteristics and treatment outcomes and to review the literature.

Case report

We are presenting the case of a 38-year-old woman (who has given her consent about the present report) with a history of multiple sclerosis. She had developed over 2 years a mass in the right nasal cavity causing an obstruction, recurrent bleeding and deformation of the nasal pyramid. There were no pain symptoms.

The clinical examination showed no abnormalities of the skin but the anterior rhinoscopy revealed a round mass on the lateral wall of the nasal cavity with a normal aspect of the mucosa. Biopsies under local anesthesia were performed but were inconclusive, showing inflammatory tissues and mycelial filaments. The CT-scan (Figure 1) without contrast injection showed a nodular formation with well-defined limits, measuring 22mm x 15mm in the right nasal cavity. There was a doubt on a slightly lytic nature on the septum. The density was tissular, heterogenous, without necrosis and with slightly calcified borders. There were no lymphadenopathies.

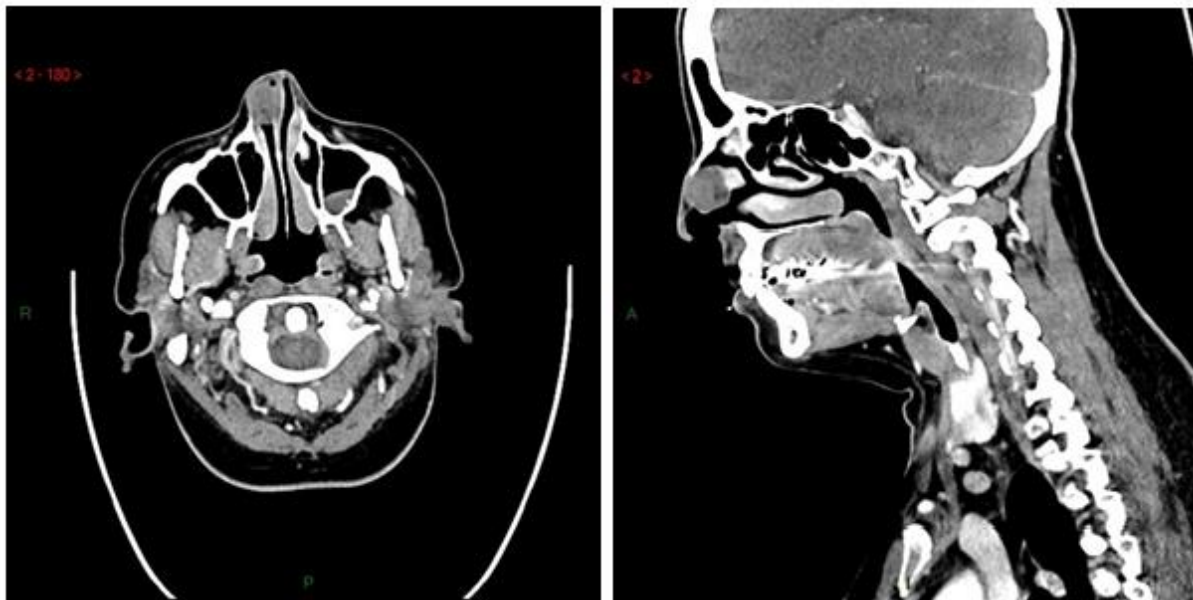
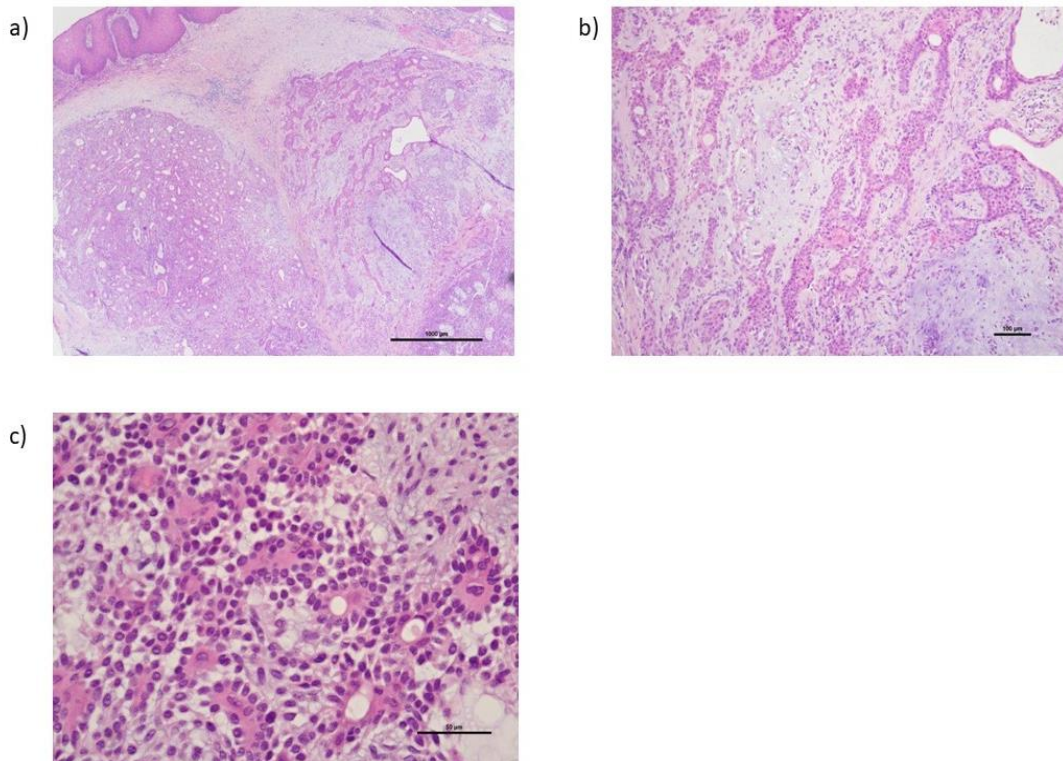


Figure 1. Enhanced CT-scan axial and sagittal views of the tumor

Since the exact nature of the tumor was unknown, we decided to surgically remove it performing an “opened rhinoplasty” under general anesthesia, which allowed to control the margins for an en bloc resection and to preserve the cartilages. The patient was released on day one after

the surgery and there were no post-operative complications such as bleeding or wound infection. The anatomopathological diagnosis was in favor of a pleomorphic adenoma without any sign of malignancy (Figure 2).



- a) Magnification x2.5
- b) Magnification x10
- c) Magnification x40: Ducts showing luminal cells and several layers of abluminal cells, the latter being merged into myxoid stroma.

Figure 2. Pathological sections with the two contingents: predominant epithelial (in the form of cords or tubes) and mesenchymal, of myxoid appearance

At the 3 months follow-up there were no clinical or MRI (Figure 3) signs of recurrence. The healing process was satisfying, with a discrete columella scar.

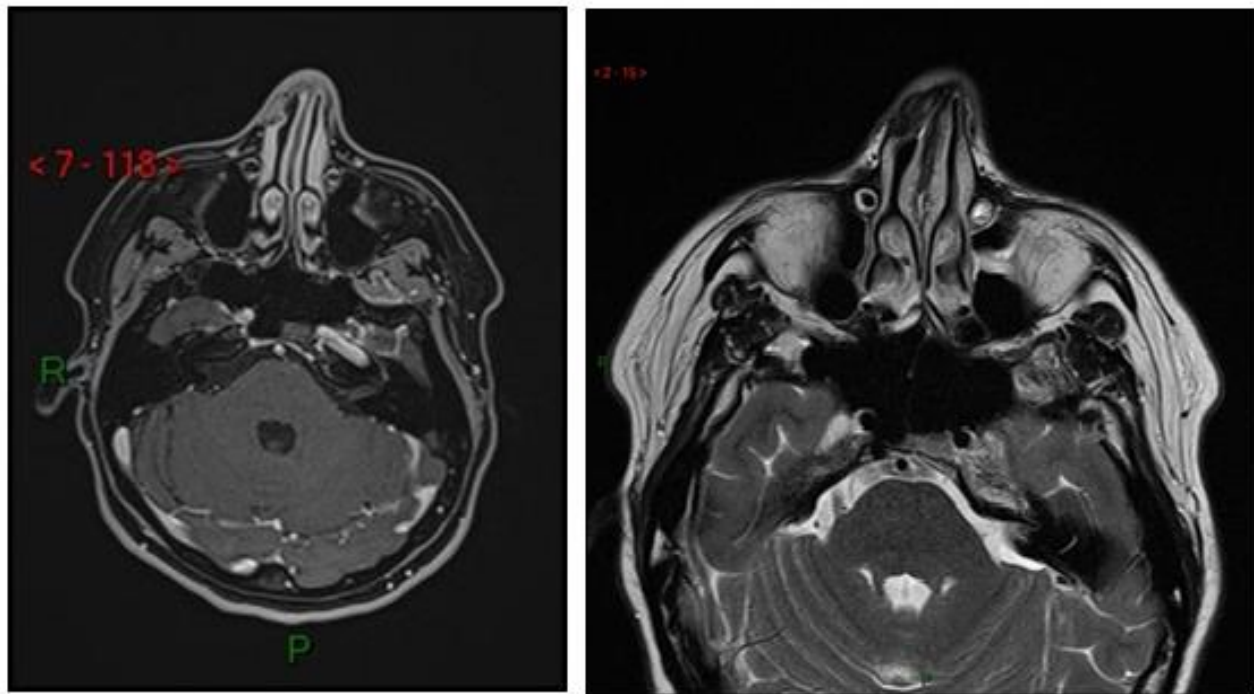


Figure 3. Post-operative MRI results at 3 months: no signs of recurrence. Left: enhanced fat sat sequence; right: T2 sequence

Discussion

Heterotopic salivary glands are abnormally located; they are different from the accessory salivary glands which are a detached part of a major salivary gland that develops along the external ductal systems. They might originate from ectopic embryonic epithelial cells derived from ectoderm or from remanent vomero-nasal organs [5]. The heterotopic salivary glands are rarely the site of diseases [11].

The clinical presentation of our patient was quite similar to the other cases of intra-nasal PAs described in literature (Table 1). PAs of minor salivary glands affect mainly women with a mean age of around 40 years old [5, 7]. The most frequent symptoms are nasal obstruction and recurrent epistaxis [2], the aesthetic deformation of the nose is found in long evolving cases. The diagnosis is often delayed with symptoms evolving for over a year before diagnosis [5].

	Number of PA cases	Number of sinuso-nasal location (%)	Age (average)	Sex (%)		Number of recurrence (%)	Number of malignant transformation (%)	Follow up (months) (mean)
				Male	Female			
Suzuki K et al. [4]	41	41 (100%)	16-74 (44.6)	NA	NA	1 (2.4%)	1 (2.4%)	NA
Compagno J et al. [5]	40	40 (100%)	3-82 (42)	17	23	3 (7.5%)	0 (0%)	12-492 (90)
Kathuria B et al. [6]	1	1 (100%)	32	0	1	0 (0%)	0 (%)	6
Vento SI et al. [7]	10	10 (100%)	19-75 (44)	2	8	0 (0%)	0 (0%)	2-55 (19)
Prager et al. [8]	1	1 (100%)	55	0	1	NA	NA	NA
Unlu H. et al. [2]	1	1 (100%)	39	0	1	0 (0%)	0 (0%)	30
Kuan et al. [9]	3	1 (33%)	55	1	0	1 (100%)	1 (100%)	12
Rha et al. [1]	7	7 (100%)	25-74 (48,3)	3	4	1 (14%)	0 (0%)	13-117 (34,4)
Wakami et al. [10]	2	2 (100%)	26-51 (38,5)	1	1	0 (0%)	0 (0%)	NA

Table 1: Overview of the sinusonasal tract PA cases described in literature

PAs of the nasal cavity mainly originate from the septum, although most of the mucosal glands of the nasal cavity are located on the lateral wall [6]. Cases have been reported in the nasal cavity, paranasal sinuses, nasopharynx, oropharynx, hypopharynx and the larynx.

In the upper respiratory tract, the most favorable site is the nasal cavity, followed by the maxillary sinus and the nasopharynx.

The differential diagnosis of intra-nasal PAs are: inverting papilloma, nasal polyp, malignant tumor such as carcinoma ex pleomorphic adenoma, unclassified mixed tumors, pyogenic granuloma, chondroma, and adenoid cystic carcinoma [5, 12]. Despite the variety of tumors, the role of preoperative biopsy is discussed. In our case the biopsy was performed under local anesthesia without endoscopic guidance which might have produced too many superficial fragments. In their review, Rha et al found the biopsy and the final anatomopathological diagnosis to be different in 6 out of 14 preoperative biopsies [1].

Multiple surgical techniques are described. The main goal of the PA surgery is to remove the tumor completely, if possible en bloc. This can be achieved endoscopically or through an open surgery such as lateral rhinotomy, midfacial degloving or transpalatal surgery [1]. There is no gold standard surgical technique today. Karakus et al. argues that an endoscopic approach might produce less morbidity, reduce blood loss during surgery, decrease hospital stay, avoid external scars and excessive unnecessary resection, and enable the surgeon to better visualize the margins of the tumor [13].

The recurrence rate of intranasal PAs is reported to be of 8% with a mean follow up of 29 months. The known risk factors of recurrence are: the paranasal sinus location and a carcinoma ex pleomorphic adenoma component [1]. For PAs located in the parotid, the recurrence rate ranges from 2% to 5%, it occurs when the removal is subtotal. Zbären et al showed that stroma-rich tumors (myxoid PAs) are more likely to have an incomplete capsule and satellite tumors, making their recurrence potential higher [14].

There are no guidelines for intranasal PA follow up. Conventional surveillance regimens in PAs include a detailed history and clinical examination every 1-3 months for the first year after completion of treatment, every 2-6 months in the second year, and every 4-8 months for years 3 to 5. Five years after the completion of the treatment and if there is no evidence of recurrence, the patient may go on life-long yearly follow-ups. The role of imaging in the follow-ups is debated and is not compulsory. It is admitted that the first post-operative imaging should be made at least 6 months after treatment. After that, it is up to the clinician to individually adapt the frequency of enhanced MRIs [15, 16]. We decided to perform an annual MRI for the first five years as the patient is at high risk of recurrence [17].

Conclusion

PAs must be kept in mind as a potential diagnosis for intranasal tumor with slow evolution and persistent symptoms. A biopsy alone does not allow to make a reliable diagnosis. The treatment of these tumors is surgical. There are no guidelines on the follow-ups, and in our experience and according to literature, the follow-up must be done clinically and with repeated MRI controls due to the recurrence and malignant transformation risks.

Compliance with Ethical Standards

There are no conflicts of interest for the authors in this study. The patient

gave an informed consent.

References

1. Rha M-S, Jeong S, Cho H-J, Yoon J-H, Kim C-H. (2019) Sinonasal pleomorphic adenoma: A single institution case series combined with a comprehensive review of literatures. *Auris Nasus Larynx*. 46(2):223–9.
2. Unlu HH, Celik O, Demir MA, Eskiizmir G. (2003) Pleomorphic adenoma originated from the inferior nasal turbinate. *Auris Nasus Larynx*. 30(4):417–20.
3. Cimino-Mathews A, Lin BM, Chang SS, Boahene KD, Bishop JA. (2011) Carcinoma ex Pleomorphic Adenoma of the Nasal Cavity. *Head Neck Pathol*. 5(4):405–9.
4. Suzuki K, Moribe K, Baba S. (1990) A rare case of pleomorphic adenoma of lateral wall of nasal cavity--with special reference of statistical observation of pleomorphic adenoma of nasal cavity in Japan. *Nihon Jibiinkoka Gakkai Kaiho*. 93(5):740–5.
5. Compagno J, Wong RT. (1977) Intranasal Mixed Tumors (Pleomorphic Adenomas): A Clinicopathologic Study of 40 Cases. *Am J Clin Pathol*. 68(2):213–8.
6. Katuria B. (2017) Pleomorphic Adenoma a Salivary Gland Tumor as Nasal Mass; Rarest Presentation. *Glob J Otolaryngol*.
7. Vento SI, Numminen J, Kinnunen I, Rautiainen M, Tarkkanen J, Hagström J, et al. (2016) Pleomorphic adenoma in the nasal cavity: a clinicopathological study of ten cases in Finland. *Eur Arch Otorhinolaryngol*. 273(11):3741–5.
8. Prager DA. PLEOMORPHIC ADENOMA OF THE NASAL CAVITY. :1.
9. Kuan EC, Diaz MFP, Chiu AG, Bergsneider M, Wang MB, Suh JD. (2015) Sinonasal and skull base pleomorphic adenoma: a case series and literature review. *Int Forum Allergy Rhinol*. 5(5):460–8.
10. Wakami S, Muraoka M, Nakai Y. (1996) Two cases of pleomorphic adenoma of the nasal cavity. *Nippon Jibiinkoka Gakkai Kaiho*. 99(1):38–45,121.
11. Desai RS, Meshram D, Jangam SS, Singh JS. (2015) Pleomorphic adenoma of an accessory submandibular salivary gland: a rare entity. *Br J Oral Maxillofac Surg*. 53(8):e33–5.
12. Toluie S, Thompson LDR. (2012) Sinonasal Tract Adenoid Cystic Carcinoma Ex-Pleomorphic Adenoma: A Clinicopathologic and Immunophenotypic Study of 9 Cases Combined with a Comprehensive Review of the Literature. *Head Neck Pathol*. 6(4):409–21.
13. Karakus MF, Ozcan KM, Dere H. (2007) Endoscopic resection of pleomorphic adenoma of the nasal septum. *Tumori*. 93(3):300–1.
14. Zbären P, Stauffer E. (2007) Pleomorphic adenoma of the parotid gland: Histopathologic analysis of the capsular characteristics of 218 tumors. *Head Neck*. 29(8):751–7.
15. Mantravadi AV, Moore MG, Rassekh CH. (2018) AHNS series: Do you know your guidelines? Diagnosis and management of salivary gland tumors. *Head Neck*. hed.25499.
16. Sood S, McGurk M, Vaz F. (2016) Management of Salivary Gland Tumours: United Kingdom National Multidisciplinary Guidelines. *J Laryngol Otol*. 130(S2):S142–9.
17. Fakhry. (2020) Prise en charge de l'adénome pléomorphe - Pathologies des glandes parotides et submandibulaires de l'adulte et de l'enfant. Rapport de la société française d'ORL et de chirurgie cervico-faciale. PN. COMITE D'ORGANISATION. :33.