

Prevalence of palatal diseases in adults; an observational study in a tertiary care hospital

Sameh M Zamzam

Department of Otorhinolaryngology, Cairo University, Cairo, Egypt.

Corresponding Author: Sameh M Zamzam. Department of Otorhinolaryngology, Cairo University, Cairo, Egypt.

Received date: January 12, 2021; **Accepted date:** January 20, 2021; **Published date:** February 16, 2021

Citation: Sameh M Zamzam. (2021) Prevalence of palatal diseases in adults; an observational study in a tertiary care hospital. *J. of Clinical Otorhi* 3(1); DOI: 10.31579/2692-9562/017

Copyright: © 2021, Sameh M Zamzam This is an open access article distributed under the Creative Commons Attribution License, which permits unrestricted use, distribution, and reproduction in any medium, provided the original work is properly cited.

Abstract

Aim: The aim of this study is to spot the light on palatal diseases and their prevalence in adults from otolaryngologists' point of view.

Materials and Methods: This is an observational study that was conducted on adult patients presented to otolaryngology department of Cairo university hospital in the period from January 2016 to January 2018. Patients were routinely examined by the author however the chief complaint either related to palate or not.

Results: Out of 4800 patients have been examined over 2 years, 289 cases have been affected by palatal disease or lesion either primary or secondary. It was clearly noted that the most common pathology affecting the palate is the gastric reflux, 248 patients; the remaining 41 cases have been affected by different diseases of variable etiologies.

Conclusion: The palate is a part of routine examination by otolaryngologists. It may carry signs of different diseases and lesions which are not uncommon. The author observed palatal diseases in 6% of the study's sample. Prevalence of those diseases has been entailed in this study.

Keywords: palate, reflux, cleft, mucormycosis, minor salivary gland, carcinoma

Introduction

The palate is anatomically located between the nasal cavities and the oral cavity, developmentally formed of anterior bony part and posteriorly soft part ending posteriorly with the uvula. The oral surface of the palate is histologically covered by stratified squamous epithelium. The palate is derived from the 1st pharyngeal arch & reaches its definitive development at 10th-12th week intra uterine life [1-2].

The palate is routinely examined by otolaryngologists every day and other. Many diseases and lesions may affect palate either 1ry like congenital cleft palate, traumatic injury, malignant neoplasms or 2ry like gastric reflux [3-4].

The literature lacks of many studies that show incidence and prevalence of affection of the palate by diseases and lesions. The aim of this study is

to spot the light on palatal diseases and their prevalence from otolaryngologists' point of view.

Materials and Methods

This is an observational cross sectional study to determine prevalence and incidence of palatal diseases in adults, that was conducted on a population sample of 4800 adult patients with age range 22-78 years old (Table 1) presented to otolaryngology department of Cairo university hospital, which is one of the main tertiary medical care provider hospitals in Egypt in the period from January 2016 to January 2018. Patients were routinely examined by the author however the chief complaint either related to palate or not. Data of patients of palatal diseases or lesions have been collected for this study and each one was treated according to his/her disease.

Epidemiological characters		
Number	Total patients	Palatal cases
		4800
Sex	Males	Females
	162 (56%)	127 (44%)
Age	22-78 years	

Table 1. Epidemiological characters of the study's patients

Results

Out of the sample of the study over the 2 years duration, 289 cases (6%) have been affected by palatal disease either 1ry or 2ry (Table 2) (Figure. 1). It was clearly noted that the most common pathology affecting the palate is the gastric reflux, 248 patients, especially the soft part in the form of congestion and edema associated with the remaining clinical picture of the reflux. Another male, 26 years old patient of cleft hard and soft palate has been reported, it's considered an odd presentation at that age (Figure 2).

The study has also reported 6 cases of traumatic injury of the soft palate, all of these cases were iatrogenic in cause due to endotracheal intubation either associated with tonsillar injury or not (Fig. 3). 13 patients with nasal mucormycosis involving the hard palate have been participated in this

study in the form perforation due to gangrenous necrosis (Figure 4).

One case of minor vascular malformation has been reported, the patient showed bluish discoloration of the palate with little distortion of the uvula (Figure 5), this case has been discovered accidentally as the patient hasn't presented with a complaint related to his palate or mouth.

The study has reported 3 patients diagnosed clinically and pathologically as rhinoscleroma, associated with shrunken and fibrosed uvula. Another 5 cases have represented by defective palatal movement & choking & drooling of saliva and hoarseness of voice were diagnosed clinically as pseudobulbar palsy.

Neoplastic lesions have played a role in this study, the study have reported 4 cases of palatal squamous cell carcinoma (Figure 6) and 8 cases of benign pleomorphic adenoma of minor salivary glands.

Disease	Number of cases	Percentage	Age range in years	Sex	
				Males	Females
GERD	248	85.9%	27-62	142	106
Cleft palate	1	0.3%	26	1	0
Traumatic tear	6	2%	55-72	2	4
Vascular malformation	1	0.3%	22	1	0
Mucormycosis	13	4.5%	42-78	3	10
Scleroma	3	1%	24-52	3	0
Carcinoma	4	1.4%	58-70	4	0
Pleomorphic adenoma	8	2.8%	43- 51	3	5
Defective movement	5	1.8%	40-64	3	2

Table 2. Types of palatal diseases in this study and their incidence

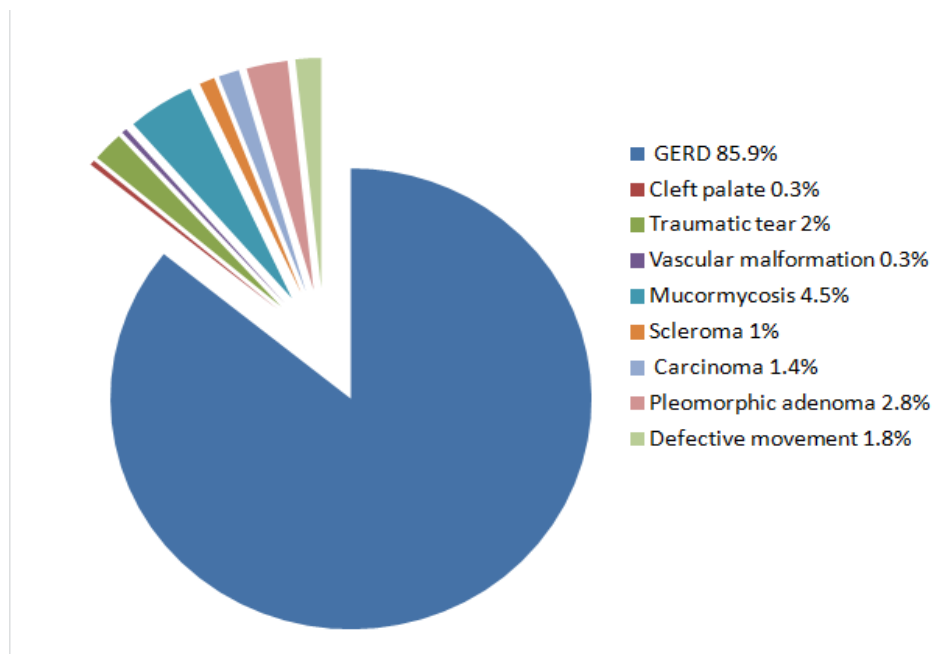


Figure 1. Pie chart shows types of palatal diseases in the study's patients & their incidence

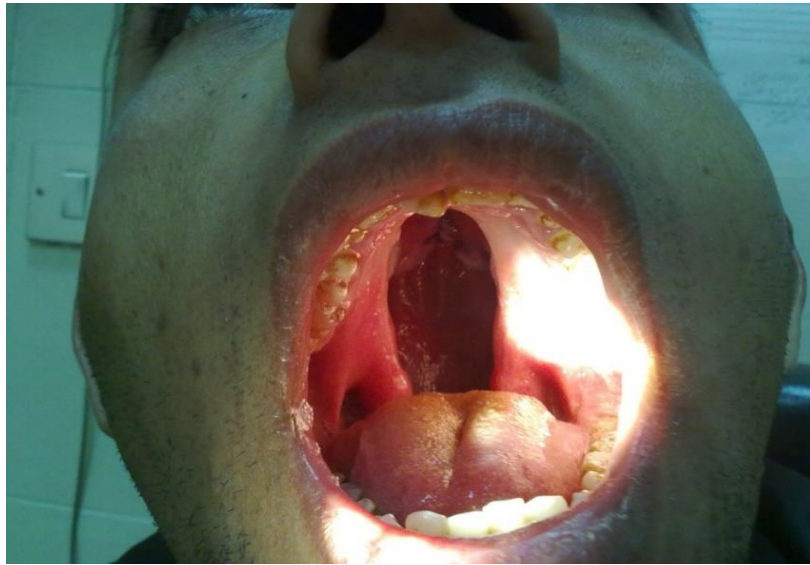

Figure 2. The case of cleft palate, 26years old patient

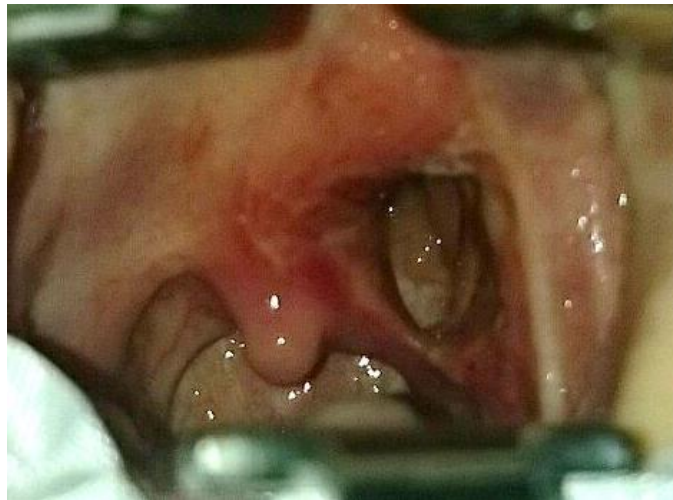

Figure 3. A case of palatal injury

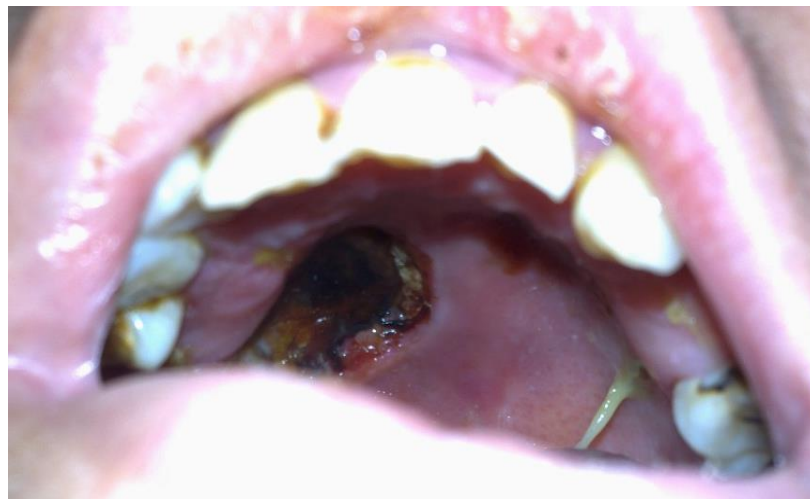

Figure 4. A case of palatal mucormycosis

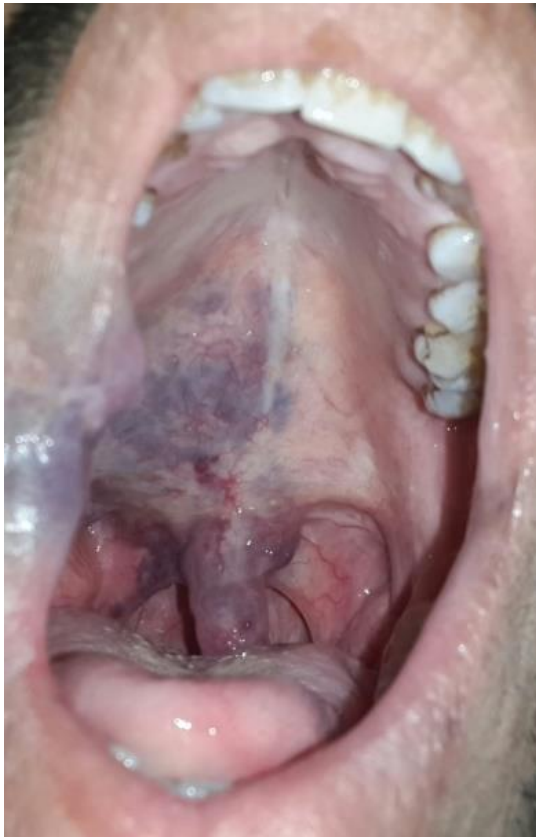

Figure 5. The case of palatal minor vascular malformation

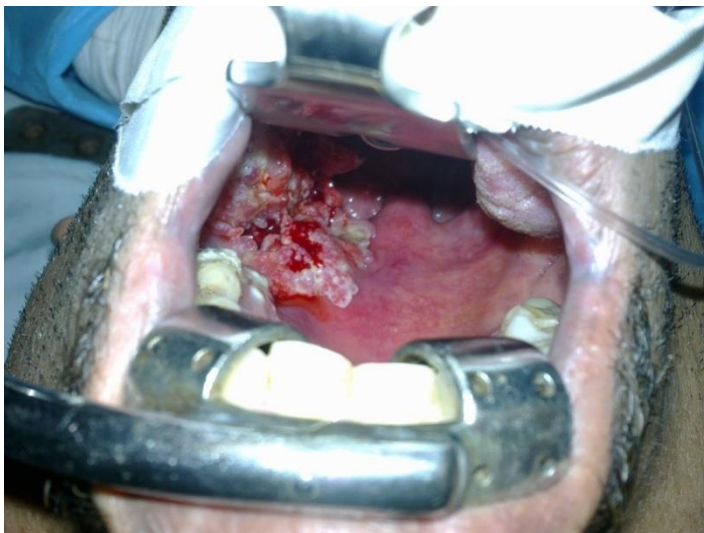

Figure 6. A case of palatal squamous cell carcinoma

Discussion

The majority of this study's cases affected with palatal diseases were due to gastroesophageal reflux disease "GERD", 248 cases, either symptomatic or not "silent refluxers" [5-6], soft palatal and oropharyngeal mucosal congestion and edema were clearly seen. Reflux in severe or chronic cases may lead to dental caries [5-7]. There are 2 theories explains the oral tissue damage in GERD: reflux theory which is due to direct contact between the acid and the mucosa. The other one is

the reflex theory in which there is vagal reflex from distal esophageal exposure to gastric acid [8].

Cleft palate and/or lip are the most common congenital anomalies occur during craniofacial development due to both genetics and environmental causes with incidence in Africa is about 1/2500 live births [9], cases are usually surgically repaired at early childhood to allow proper correct feeding and speech [10]. This study has faced a 26 years old male patient with cleft hard and soft palate with marked rhinolalia aperta and he has trained himself over years on proper feeding to avoid regurge (Figure 1).

This study has reported one case of palatal vascular malformation in the form of bluish or purple discoloration of the palate with minor distortion of the soft part and uvula & was accidentally discovered (Figure 2), this color was blanched when application of pressure on hard palate. Literature has prescribed hemangiomas in 3 debating terms true neoplasm & malformation and hamartomas [11], so choosing the term to describe that case was really confusing. Capillary hemangiomas can be sessile or polyp in shape, they grade in color from deep red to purple, those on the palate are of the capillary in origin [12].

Mucormycosis is an opportunistic invasive fungal infection affecting immune-compromised patients like uncontrolled diabetes or leukemia [13], usually involves the nasal and paranasal sinuses bone leading to vasculitis and gangrenous necrosis and that infection may extends to the bony palate [14-15]. This study has reported 13 cases of nasal and paranasal mucormycosis with palatal involvement, 11 cases of them have showed uncontrolled diabetes and the other 2 cases have given history of leukemia on treatment by chemotherapy.

Penetrating injuries to the palate may be iatrogenic or accidental by using sharp objects, injury may not be limited to the palate only also oropharyngeal mucosa, tonsils and tongue may be involved [16-17]. All the 6 patients who have been included in this study were iatrogenically injured in the soft palate due to vigorous or low experienced endotracheal intubation, only 2 cases have associated with unilateral tonsillar injury.

Palatal carcinomas account for 2% of head and neck malignancies, 50% of all hard palate carcinoma are of squamous cell in nature, other types including minor salivary gland carcinomas & melanomas and sarcomas account for the other 50% [18]. Pleomorphic adenomas the most common salivary gland tumor, it is a benign tumor composed of mixed cellular patterns surrounded by fibrous capsule [19]. This study has reported 12 patients with neoplastic lesion in the palate, all patients have been subjected to biopsy and pathological examination which revealed 4 cases of palatal squamous cell carcinoma and 8 cases of pleomorphic adenoma, carcinoma patients have been proceeding for CT/MRI for staging and mapping. Patients of pleomorphic adenoma were treated by palatectomy/ inferior maxillectomy, on the other hand cases of carcinoma were treated by inferior/total maxillectomy with adjuvant chemo-radiotherapy.

Palatal motor innervation may be affected by any pathology that damages bilateral corticobulbar tracts, the condition usually associated with dysarthria, dysphagia and choking that is what termed pseudobulbar palsy [20-21]. This study has recorded 5 cases of pseudobulbar palsy that referred from neurology department for consultation for tracheostomy.

Literature describes scleroma as an uncommon granulomatous lesion that most commonly affects nose & nasopharynx and larynx, the palate is not a site of primary affection but it may be a site of extension of the granulomatous lesion of the second stage of the disease [22], a study by Badrawy in 1965 had described what was called the "uvula sign" which means retraction or elevation of the uvula in case of diffuse nasopharyngeal infiltration by granulomatous scleroma [23], and that is what was noticed in the present study.

Conclusion

The palate is a part of routine examination by otolaryngologists. It may carry signs of different diseases and lesions which are not uncommon. The author observed palatal diseases in 6% of the study's sample. Prevalence of those diseases has been entailed in this study.

Competing interests

No conflicts of interest

Funding

Not applicable

Authors' contribution

Not applicable, as it's just one author

Acknowledgements

Not applicable

References

- Bush JO, Jiang R. Palatogenesis (2012) Morphogenetic and molecular mechanisms of secondary palate development. *Development*. 139:231-43
- Schoenwolf GC, Bleyl SB, Brauer PR, Francis-West PH. (2015) Larsen's Human Embryology, 4th ed. 568-71.
- Neville BW, Damm DD, Allen CM. (2001) Oral and Maxillofacial Pathology. 2nd ed. 400.
- Sutherland KG. (1968) The pathology and treatment of diseases of the palate. *Australian Dental Journal*. 13:111-24
- Monini S, Stadio DA, Vestri A, Barbara M. (2006) Silent reflux: ex juvantibus criteria for diagnosis and treatment of laryngeal disorders. *Acta Otolaryngol*. 126:866-71.
- Riscili BP, Parsons JP, Mastronarde JG. (2010) Treating silent reflux disease does not improve poorly controlled asthma. *Cleve Clin J Med*. 77:155-60.
- Bartlett DW, Evans DF, Anggiansah A, Smith BG. (1996) A study of the association between gastro-oesophageal reflux and palatal dental erosion. *Br Dent J*. 1996; 24:125-31.
- Petruzzi M, Lucchese A, Campus G, Crincoli V, Lauritano D, Baldoni E. (2012) Oral stigmatic lesions of gastroesophageal reflux disease (GERD). *Rev Med Chil*. 140:915-8.
- Beaty TH, Murray JC, Marazita ML, Munger RG, Ruczinski I, Hetmanski JB. (2010) A genome-wide association study of cleft lip with and without cleft palate identifies risk variants near MAFB and ABCA4. *Nat Genet*. 42:525-9.
- Arosarena OA. (2007) Cleft lip and palate. *Otolaryngol Clin North Am*. 40:27-60.
- Barnes L. (1985) Tumours and tumour-like lesions of the soft tissues. In: Barnes L, ed. *surgical pathology of the head and neck*. New York, NY: Marcel Dekker. 725-880
- Acikgoz A, Sakallioğlu U, Ozdamar S. (2000) Rare benign tumours of oral cavity—capillary hemangioma of palatal mucosa: a case report. *Int J Paediatr Dent*. 10:161-5.
- McNulty JS. (1982) Rhinocerebral mucormycosis: predisposing factors. *Laryngoscope*. 92: 1140-3.
- Rosen PP. (1976) Opportunistic fungal infections in patients with neoplastic diseases. *Pathol Annu*. 11:255-315.
- Damante JH, Fleury RN. (1998) Oral and rhino orbital mucormycosis: case report. *J Oral Maxillofac Surg*. 56:267-71.
- Smyth DA, Fenton J, Timon C. (1996) Occult pharyngeal perforation secondary to 'pencil injury'. *J Laryngol Otol*. 110:901-3.
- Dubey SP, Ghosh LM. (1993) Neck abscess secondary to perforation and complete extraluminal migration of a pharyngeal foreign body (wire): a case report. *Auris Nasus Larynx*. 20:47-51.
- Sadeghi N, Al-Sebeih K. (2013) Malignant Tumors of the Palate. *Medicine*. 213:44-8.
- Rodman R, Watts TL. (2011) Tumors of the hard palate and upper alveolar ridge. Grand Rounds Presentation, The University of Texas Medical Branch (UTMB). 211:1-8
- McCormick WE, Lee JH. (2002) pseudobulbar palsy caused by a large petroclival meningioma: report of two cases. *Skull base. Official journal of North American Skull Base Society*. 12:67-71.
- Hong C. (2006) Thirty-six cases of pseudobulbar palsy treated by needling with prompt and deep insertion. *J of traditional Chinese medicine*. 26:184-5.
- Hasson O, Levi G, Huszar M. (2005) Scleroma of the Soft and Hard Palate. *J of Oral and Maxillofacial Surgery*. 63:1536-38.
- Badrawy R. (1965) The Uvula Sign in Scleroma of the Nasopharynx. *Ann Otol Rhinol Laryngol*. 74:441-4.



This work is licensed under Creative Commons Attribution 4.0 License

To Submit Your Article Click Here: [Submit Manuscript](#)

DOI: [10.31579/2692-9562/017](https://doi.org/10.31579/2692-9562/017)

Ready to submit your research? Choose Auctores and benefit from:

- ❖ fast, convenient online submission
- ❖ rigorous peer review by experienced research in your field
- ❖ rapid publication on acceptance
- ❖ authors retain copyrights
- ❖ unique DOI for all articles
- ❖ immediate, unrestricted online access

At Auctores, research is always in progress.

Learn more www.auctoresonline.org/journals/journal-of-clinical-otorhinolaryngology