

Coronary Artery Embolism and Antiphospholipid Syndrome: A Case Report and Review of the Literature

Tianbao Xu^{1#}, Esmayilaji Patiway^{1#}, Gulistan Alim¹, Chenghui Tong¹, Jinghe Zhao¹, Patigul Rozi¹, Eslamgul Hayrilla¹, Zemu Wang², Dianfu Li^{2*}, Yanrong Liu^{1,2*}.

¹Department of Cardiovascular Medicine, Kizilisu Krihiz, The People's Hospital of Kizilisu Kirghiz Autonomous Prefecture, Xinjiang, China.

²Department of Cardiology, the First Affiliated Hospital of Nanjing Medical University.

***Corresponding Author:** Yanrong Liu and Dianfu Li, Department of Cardiology, the First Affiliated Hospital of Nanjing Medical University.

#**Co-first author:** Tianbao Xu, and Esmayilaji Patiway, Department of Cardiovascular Medicine, Kizilisu Krihiz, The People's Hospital of Kizilisu Kirghiz Autonomous Prefecture, Xinjiang, China.

Received Date: November 27, 2020; **Accepted Date:** December 01, 2020; **Published Date:** December 09, 2020

Citation: Tianbao Xu, Esmayilaji Patiway, Gulistan Alim, Chenghui Tong, Jinghe Zhao, Patigul Rozi, Eslamgul Hayrilla, Zemu Wang, Dianfu Li, Yanrong Liu (2020) Coronary Artery Embolism and Antiphospholipid Syndrome: A Case Report and Review of the Literature. *J. Clinical Cardiology and Cardiovascular Interventions*, 3(13); Doi:10.31579/2641-0419/116

Copyright: © 2020 Yanrong Liu and Dianfu Li, This is an open-access article distributed under the terms of the Creative Commons Attribution License, which permits unrestricted use, distribution, and reproduction in any medium, provided the original author and source are credited.

Abstract

Coronary artery embolism is an uncommon cause of acute myocardial infarction (AMI), while antiphospholipid syndrome (APS) is one of the rare reasons due to premature AMI. Coronary angiography can diagnose coronary artery embolism, and the positive serum of aPLs may infirm APS. We report a 32 years old man with ST-elevation AMI, without any high-risk factors of coronary artery disease. Coronary thrombosis was founded in the M1 sub-coronary of Left Anterior Descending (LAD), and the coronary artery was recanalized, the artery was not obstructive. Thrombolysis in Myocardial Infarction (TIMI) grade was III. He became shortness after exercise, the echocardiography showed his left ventricular was enlarged and LVEF was decreased. High titers of an anticardiolipin antibody (aCL) IgG of 46U (positive >20.0U), and it was positive at two dosages with an interval greater than 12 weeks. But there was no evidence of any other serum markers suggesting other associated pathologies such as SLE, so the primary APS was diagnosed. We gave him anticoagulation with warfarin and a single antiplatelet with Aspirin, the target INR was 2.5-3.0. Meanwhile, statins and hydroxychloroquine (HCQ) were all prescribed. After 6-months follow-up, his heart failure symptoms were disappeared, the LVDD and LVEF were all normal, the titer was decreased to nearly normal. In clinical background, young AMI without traditional high-risk factors of CAD, we should suspect APS. Therefore, we believed that HCQ may low thrombotic rate, down-trending aPLs titer, and prevent thrombotic recurrences in patients with primary antiphospholipid syndrome.

Keywords: coronary embolism; antiphospholipid syndrome; anticoagulation; hydroxychloroquine (HCQ); statins.

Introduction

Coronary artery embolism is an uncommon cause of acute myocardial infarction (AMI), being identified as an etiology in 3-4% of the diagnosed cases, and it is easy to be ignored in clinical practice [1]. AMI is rarely associated with antiphospholipid syndrome (APS), therefore, the development of thrombosis in the coronary arteries is highlighted, and it is estimated that approximately 2.8-5.5% of cases of AMI in young individuals are secondary to APS [2].

The APS is defined by a state of hypercoagulability secondary to a wide spectrum of presentations. Its presentation is quite variable, constituting a spectrum of findings ranging from the presence of cutaneous alterations to the involvement of multiple organs, leading to systemic collapse. It is associated with thrombotic events involving venous and arterial territories, large arteries and veins as well as microvascular circulation and obstetrical events, in association with persistent antiphospholipid antibodies (aPLs), one or more of lupus anticoagulant (LA), and anticardiolipin antibodies (aCL) and /or IgM anti-beta 2 glycoprotein 1(β2GPI) [3], which are implicated in the development of endothelial

dysfunction among the factors. This syndrome is classified as primary when there is no association with other pathologies or secondary when it is linked to an underlying disease [4].

In APS, the mechanism of myocardial ischemia differs from that which occurs classically in coronary artery disease, a fact that implies the need for a specific therapeutic approach for patients with this syndrome [5].

Herein, we describe the case of a patient with APS who had AMI with ST-segment elevation on electrocardiogram and subsequent coronary stent thrombosis and then the thrombosis was autolysis. But the myocardial cells were damaged, left ventricular was enlarged and the LVEF was decreased.

Case Presentation

A young Chinese man, 32 years old, was admitted with chest pain for six hours in 6 months before, according to the ECG of V1-V4 ST elevation (**Figure 1**) and increased troponin T, the diagnosis of AMI was confirmed.

Figure 1

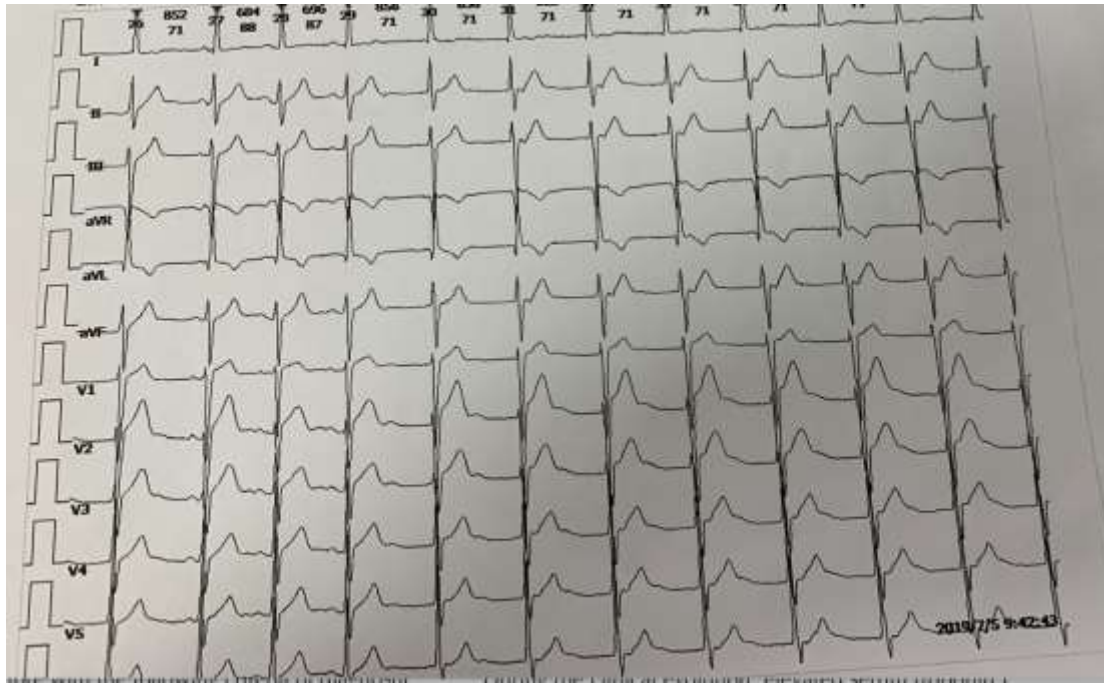


Figure 1. The electrocardiography showed sinus rhythm; ST-segment elevation in the anterior walls (V1-V4), and the inversion of T wave was in high lateral wall (aVL).

The laboratory findings were as follows: hemoglobin, platelets count, prothrombin time, liver and renal functions were all normal. But the troponin T and NT-proBNP were elevated. He received dual antiplatelet aggregation therapy (aspirin and Ticagrelor) and performed with coronary

angiography after 6 hours of the symptom onset. Coronary thrombosis was founded in the M1 sub-coronary of LAD, and the coronary artery was recanalized, the artery was not obstructive, TIMI grade was III (**Figure 2**).

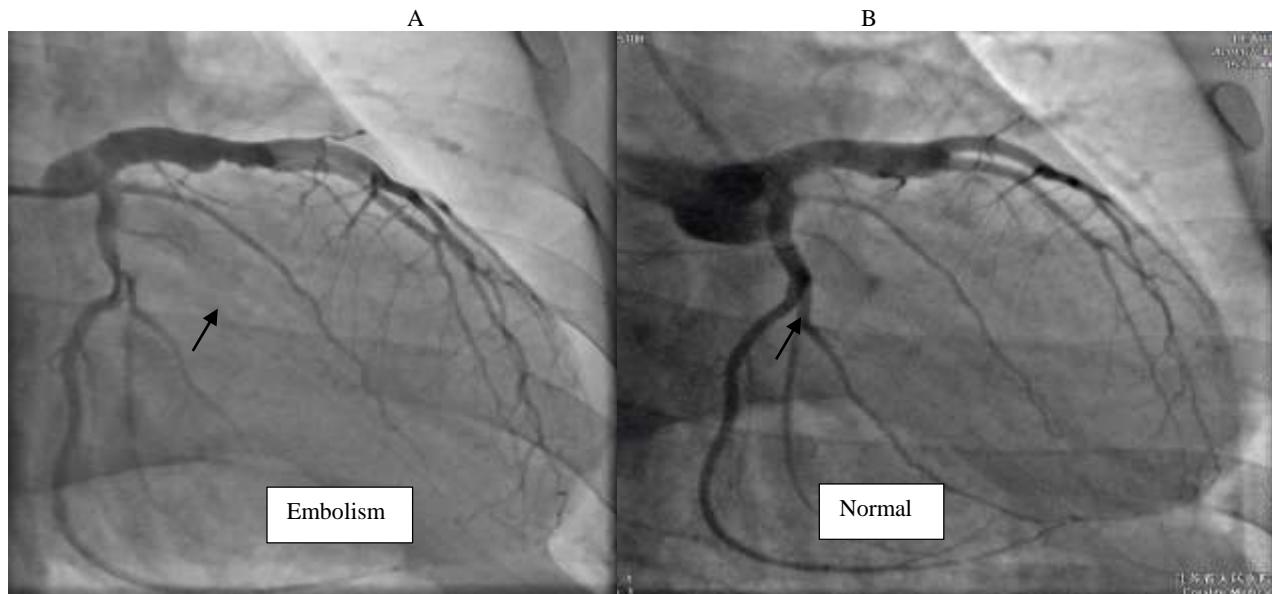


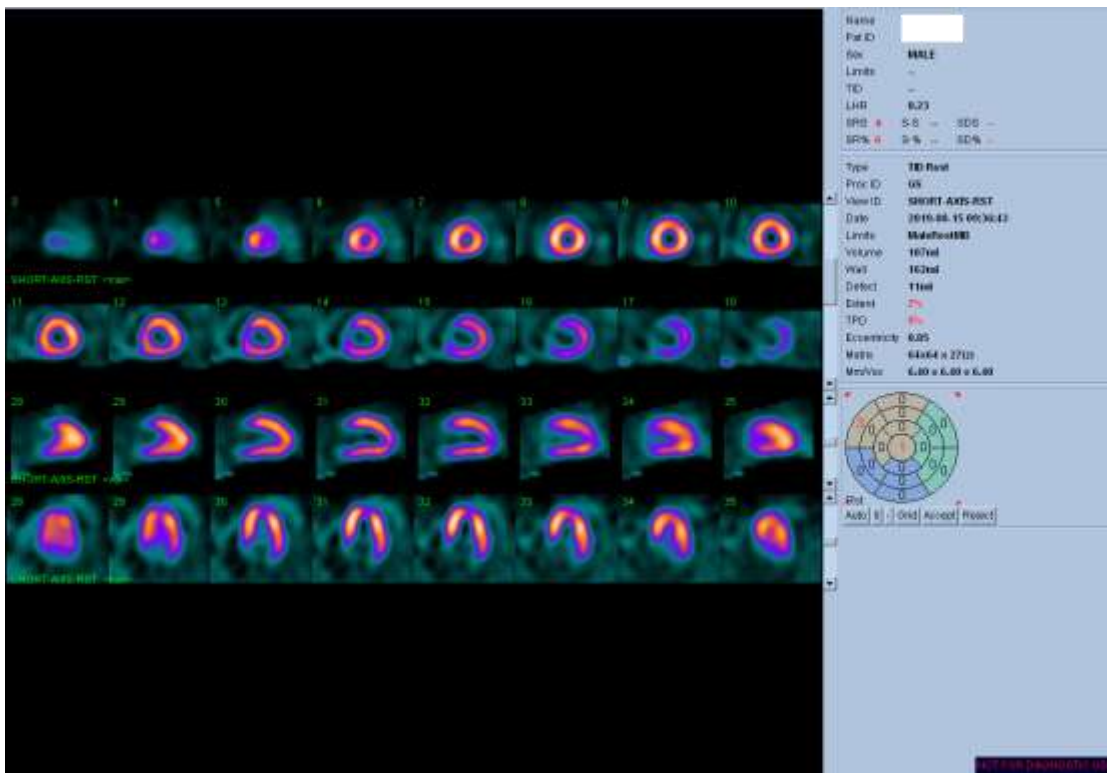
Figure 2: A: Coronary thrombosis was founded in the M1 sub-coronary of LAD;
B: Coronary artery was recanalized, the artery was not obstructive.

On the 20 days after discharge, the patient was readmitted with fatigue and a little shortness while he was climbing upstairs. During the laboratory evaluation, there was no significant change in the results,

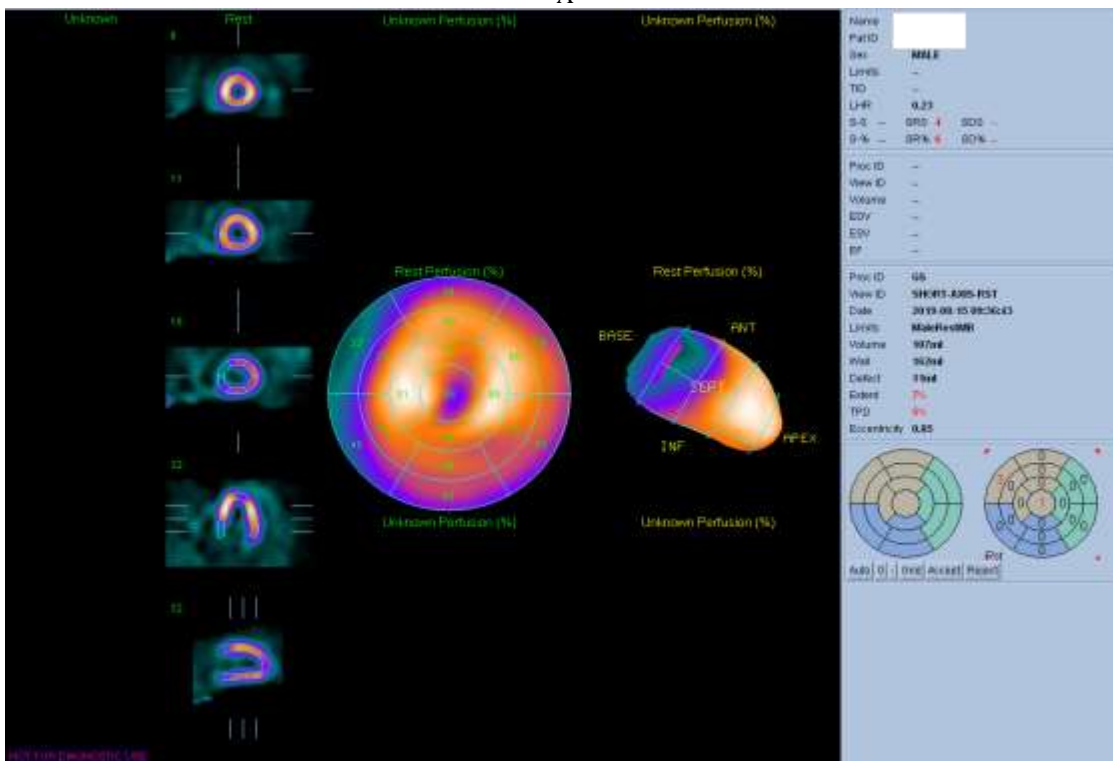
except for high titers of an anticardiolipin antibody IgG of 46U (positive >20.0U) and IgM of 14.6U (negative < 20.0U) and anti-β2-Glycoprotein

I with IgG of 10.6RU/ml (negative < 20.0RU/ML). This test result was positive at two dosages with an interval greater than 12 weeks, there was no evidence of any other serum markers suggesting other associated pathologies such as SLE.

The myocardial scintigraphy with Thallium-201 at rest was performed to evaluate myocardial viability on 1-month of re-hospitalization, demonstrating viability associated with LAD artery territory [6]. It was an abnormal motion of the left ventricular and the left ventricular was enlarged (**Figure 3**).



A



B

Figure 3: A and B demonstrate that abnormal motion of left ventricular and the left ventricular was enlarged with myocardial scintigraphy with Thallium-201 at rest.

Transthoracic echocardiography was also demonstrated that the left ventricular was enlarged (LVDd 59mm) the ejection fraction was decreased as 43.8%, and akinesis of segments: basal anterior septal, mid-anterior septal [7].

As such, primary APS was diagnosed according to the Sydney consensus statement on classification of APS [8] and oral anticoagulation (Warfarin) plus low-dose aspirin (LDA). Hydroxychloroquine (HCQ, 400mg/day, 200mg twice a day) and statin (fluvastatin 80mg/day) with early outpatient follow-up were indicated [9]. According to the patient has symptoms and signs of heart failure, ACEI, beta-blocker, and spiro lactone were added to anti-heart failure, and we added ACEI and beta-blocker and titrated to target dosage gradually.

This patient is a young man without any other high-risk factors of coronary artery disease. The diagnosis of APS was established by the presence of antiphospholipid antibodies and coronary thrombosis formation and the cTnT was higher and the evolution of ECG characteristics.

We followed him six months, the anticardiolipin antibody IgG of 27.8U and IgM of 15.6U, anti- β 2-Glycoprotein I with IgG of 10.7 RU/ml (negative < 20.0RU/ML), NT-proBNP <5.0pg/mL, D-dimer 0.18mg/L. The echocardiography showed that LVDd 49mm, LAD 36mm, EF was normal. And six minutes' walk was 602 miles, and we prescribed him for Mon-antiplatelet therapy of Aspirin and antithrombotic agents of warfarin adjusted the INR between 2.5-3.0.

Literature Review and Discussion

The pathology of acute coronary syndrome involves coronary thrombosis and platelet accumulation [10]. Acute Coronary Syndrome (ACS) is categorized into unstable pectoris, ST-segment elevation, and non-ST-segment elevation. Coronary embolism is uncommon and is difficult to distinguish from other causes of AMI solely based on symptoms. The common risk factors of ST-segment myocardial infarction were hypertension, diabetes mellitus, dyslipidemia, glucocorticoid use, and smoking [11]. If a young male suddenly appears as AMI, without any atherosclerotic risk factors, but with a history of one of the following: atrial fibrillation, endocarditis, valve replacement, or venous thrombosis should be suspected as coronary embolism, while APS was an uncommon cause of coronary embolism. In this case, the patient did not have such risk factors as mentioned above, so we believed that the hypercoagulable state resulting from APS contributes to the progression and development of ST-elevation myocardial infarction.

Since the first description of APS in 1983, a long way has already been overcome [12]. However, new exciting knowledge is coming up in this field since the wider awareness of this disease has increased in interest. The heart is an important target organ in APS. Cardiac manifestations of APS include heart valve disease, stenotic or occlusive thrombotic coronary artery disease, intracardiac thrombus, left ventricular hypertrophy and dysfunction, and pulmonary hypertension. Myocardial small vessel involvement can be highly prevalent in APS patients [13].

APS may be a cause of coronary embolism as these above situations are absent [14]. Typically, APS has 3 major presentations: arterial and venous thrombosis, pregnancy loss and thrombocytopenia. Clinically, APS patients are divided into 4 types: I, positive for at least one laboratory indicator; type IIa, only positive for LA; type IIb, only positive for aCL; type IIc, only positive for β 2GPI [15].

The frequency of myocardial infarction in patients with APS is reportedly 4% and the presence of antiphospholipid antibodies has been associated with myocardial infarction in young patients [16] There is an increased

risk of myocardial infarction in patients with APS caused by coronary thrombosis rather than by premature atherosclerosis.

Anticoagulation should be achieved with warfarin or a novel anticoagulant rather than antiplatelet drugs [17]. Patients who received a coronary stent at the time of coronary angiography are more complex. Management may either be with triple therapy or a single antiplatelet agent coupled with oral anticoagulation, such as warfarin and Aspirin. Again, in the absence of guidelines, decisions are at the discretion of the individual clinician and assessment of bleeding risk against the risk of further thromboembolic events [18]. If the underlying vessel appears free of atherosclerosis according to coronary angiogram and without implanting the stent, the patient may be managed with anticoagulation alone.

Standard-of-care secondary thromboprophylaxis with dose-adjusted VKAs such as warfarin has several drawbacks, including adverse interactions with food and other drugs, the need for careful monitoring to keep patients with a desired range of the international normalized ratio (INR) and increased risk of bleeding [19]. The Non-Vitamin K Antagonists Oral Anticoagulants (NOACs) are designed to provide predictable anticoagulation that can be delivered at a consistent dose and that does not require continuous monitoring [20]. But there are possible disadvantages to their use because of their pharmacokinetic profiles. Unlike warfarin, direct oral anticoagulants (DOACs) have only 1 molecular target so could be less effective in potent thrombophilic states. Anticoagulant doses needed to prevent arterial thrombosis are higher, so DOACs may not be adequate. Lastly, DOACs short half-lives may theoretically lead to additional "breakthrough" thrombosis and anticoagulation failures. Evidence is needed before we can widely adopt the use of DOACs in these high-risk populations [21]. DOACs role in the therapy of APS is under investigation but not verified [22]. It seems clear that the identification of subgroups of patients with distinct clinical features will allow a more precise therapeutic strategy and better patients care. However, the best clustering strategy is still a matter of debate. Probably, several other underappreciated factors might influence the risk of moving the balance to or away from the thrombotic state [23].

The actual mechanism of thrombosis in APS is as yet unknown, but numerous mechanisms have been proposed. Mammalian target of rapamycin (mTOR) is associated with APS-related vasculopathy. Of note, a growing pool of evidence suggests that mTOR inhibitors might induce a prothrombotic phenotype in patients, leading to thrombosis and limiting their use in patients with aPL [24]. mTOR inhibitors such as sirolimus may be especially useful in APS patients with AMI requiring percutaneous intervention (PCI) to decrease in-stent vascular proliferation occurring several months after stent implantation [25].

The relapse rate in APS remains high, around 20%-21% at 5 years in thrombotic APS. Several pharmacological mechanisms explain the therapeutic potential of Hydroxychloroquine in rheumatic and related diseases. Hydroxychloroquine (HCQ) has various immunomodulatory, metabolic, cardiovascular, antithrombotic, and antineoplastic effects [26]. And HCQ has shown its efficacy in primary and secondary thromboprophylaxis, both in aPL positive and aPL negative SLE patients. HCQ could exert its anti-thrombotic ability through more than one mechanism and it shows an excellent safety profile [27]. HCQ can low thrombotic rate, down-trending aPL titer, and prevent thrombotic recurrences in patients with systemic lupus erythematosus and recently also in patients with primary antiphospholipid syndrome [28]. Despite the promising result, further evidences are needed in order to confirm the effective role of HCQ in preventing thrombotic recurrences in APS setting.

The patient's decreased titer of aPL maybe relate to the HCQ, according to the previous studies, although other studies did not confirm this association. The titers of aPL frequently decrease and eventually become negative during the follow-up period [29]. The negativization has been related to a lower risk of thrombotic event, allowing to discontinuation of anticoagulation after aPL seroconversion seems to be reasonably safe, at least in primary APS [30].

While APS patients' autoantibodies to phospholipid-binding proteins are thought to be pathogenetic through a variety of mechanisms, including interacting with the coagulation and fibrinolytic systems, monocyte and neutrophil activation, endothelial cell activation, and complement-mediated processes [31]. Statins are widely used for the treatment of hypercholesterolemia and in secondary prevention of atherosclerotic coronary disease. Statins have pleiotropic effects including the inhibition of vascular adhesion molecules, interleukin 6, and tissue factor in endothelial cells. In humans, Fluvastatin has been shown to significantly reduce pro-inflammatory and prothrombotic markers in APS patients [32].

Conclusions

Coronary embolism is uncommon in young adults and generally presents with chest pain and dyspnea. The diagnosis of coronary embolism is made definitively by cardiac catheterization. Echocardiography is needed to explore the origin of the thrombus. The antiphospholipid syndrome may be one of the etiologies. Thus, immunological tests should be performed. Long-term anticoagulant and antiplatelet therapies are recommended. HCQ and statins may reduce the titer of aPL to reduce the recurrence of coronary artery thrombosis. But we need more studies and case-control studies to confirm this conclusion. It is still needed to clarify if the future integration of artificial intelligence and big data to patient care might help in the management of the patients with APS considering hundreds of other risk factors unappreciated until now.

Reference

1. Lacey MJ, Raza S, Rehman H, Puri R, Bhatt DL, and Kalra A. Coronary Embolism: A Systematic Review. *Cardiovascular Revascularization Medicine*. 2020;21(3):367-374.
2. Vendittelli PS, Botros B, Rosman HS, Govindaraju V, Zaitoun A, and Marroush TS. Coronary Artery Embolism: Two Case Reports and a Review of the Literature. *Am J Med Sci*. 2019;357(4):333-337.
3. Zuily S, Cohen H, Isenberg D, Woller SC, Crowther M, Dufrost V, et al. Use of Direct Oral Anticoagulants in Patients with Thrombotic Antiphospholipid Syndrome: Guidance from the Scientific and Standardization Committee of the International Society on Thrombosis and Haemostasis. *J Thromb Haemost*. 2020;18(9):2126-2137.
4. Miyakis S, Lockshin MD, Atsumi T, Branch DW, Brey RL, et al, International Consensus Statement on an Update of the Classification Criteria for Definite Antiphospholipid Syndrome (APS). *J Thromb Haemost*. 2006;4:295-306.
5. Smukowska-Gorynia A, Mularek-Kubzdela T, and Araszkiwicz A. Recurrent acute Myocardial Infarction as an Initial Manifestation of Antiphospholipid Syndrome: Treatment and Management. *Blood Coagul Fibrinolysis*. 2015;26(1):91-94.
6. Jurić I, Fazlibegović E, Pravdić D, Starčević B, Punda A, Huić D, et al The Significance of Thallium-201-Chloride SPECT Myocardial Perfusion Imaging in the Management of Patients with Stable Chronic Coronary Artery Disease. *Clin Med Insights Cardiol*. 2018; 12:1-8.
7. Price S, Platz E, Cullen L, Tavazzi G, Christ M, Cowie MR, et al. Expert Consensus Document: Echocardiography and Lung

8. Chaturvedi S, and McCrae KR. Diagnosis and Management of the Antiphospholipid Syndrome. *Blood Rev*. 2017;31(6):406-417.
9. Erkan D, Willis R, Murthy VL, Basra G, Vega J, Ruiz-Limon P, et al. A Prospective Open-label Pilot Study of Fluvastatin on Proinflammatory and Prothrombotic Biomarkers in Antiphospholipid Antibody Positive Patients. *Ann Rheum Dis*. 2014;73(6):1176-1180.
10. Harrington DH, Stueben F, and Lenahan CM. ST-Elevation Myocardial Infarction and Non-ST-Elevation Myocardial Infarction: Medical and Surgical Interventions. *Crit Care Nurs Clin North Am*. 2019;31(1):49-64.
11. Alishiri G, Moshkani Farahani M, Sadr A, Salehi M, Rahemi M, and Rezapoor B. The Frequency of Anti-phospholipid Antibody Syndrome in Patients with Premature Coronary Artery Disease. *Journal of Cardiovascular and Thoracic Research*. 2018;10(4):227-230.
12. Hughes, G. R. The anticardiolipin syndrome. *Clin. Exp. Rheumatol*. 1985; 3, 285–286.
13. Siddique S, Risse J, Canaud G, and Zuily S. Vascular Manifestations in Antiphospholipid Syndrome (APS): Is APS a Thrombophilia or a Vasculopathy? *Curr Rheumatol Rep*. 2017;19(10):64.
14. Miranda CH, Gali LG, Marin-Neto JA, Louzada-Júnior P, Pazin-Filho A. Coronary Thrombosis as the First Complication of Antiphospholipid Syndrome. *Arq Bras Cardiol*. 2012; 98(4): e66-69.
15. Zuo Y, Barbhuiya M, and Erkan D. Primary Thrombosis Prophylaxis in Persistently Antiphospholipid Antibody-Positive Individuals: Where Do We Stand in 2018? *Curr Rheumatol Rep*. 2018;20(11):66.
16. Andrade D, Bortolotto L, Bonfa E, Borba E. Primary Antiphospholipid Syndrome: Absence of Premature Atherosclerosis in Patients without Traditional Coronary Artery Disease Risk Factors. *Lupus*. 2016;25(5):472-475.
17. Cuadrado MJ, Bertolaccini ML, Seed PT, Tektonidou MG, Aguirre A, Mico L, et al. Low-dose Aspirin vs Low-dose Aspirin plus Low-intensity Warfarin in Thromboprophylaxis: A Prospective, Multicentre, Randomized, Open, Controlled Trial in Patients Positive for Antiphospholipid Antibodies (ALIWAPAS). *Rheumatology (Oxford)*. 2014;53(2):275–284
18. Raphael CE, Heit JA, Reeder GS, Bois MC, Maleszewski JJ, Tilbury RT, et al. Coronary Embolus: An Underappreciated Cause of Acute Coronary Syndromes. *JACC Cardiovasc Interv*. 2018;11(2):172-180.
19. Son M, Wypasek E, Celinska-Lowenhoff M, Undas A. The Use of Rivaroxaban in Patients with Antiphospholipid Syndrome: A Series of 12 cases. *Thromb Res*. 2015; 135:1035–1036.
20. Ordi-Ros J, Saez-Comet L, Perez-Conesa M, Vidal X, Riera-Mestre A, Castro-Salomo A. Rivaroxaban Versus Vitamin K Antagonist in Antiphospholipid Syndrome: A Randomized Noninferiority Trial. *Ann Intern Med*. 2019;171(10):685-694.
21. Skeith L. Anticoagulating Patients with High-risk Acquired Thrombophilias. *Blood*. 2018;132(21):2219-2229.
22. Pengo V, and Denas G. Diagnostics and Treatment of Thrombotic Antiphospholipid Syndrome (APS): A Personal Perspective. *Thrombosis Research*. 2018; 169:35-40.
23. Rodriguez-Pinto I, Espinosa G, and Cervera R. Precision Medicine and the Antiphospholipid Syndrome: What is the Future? *Clin Rheumatol*. 2020;39(4):1015-1017.
24. Sciascia S, Amigo MC, Roccatello D, and Khamashta M. Diagnosing Antiphospholipid Syndrome: 'Extra-criteria'

- Manifestations and Technical Advances. *Nat Rev Rheumatol*. 2017;13(9):548-560.
25. Canaud G, Bienaime F, Tabarin F, Bataillon G, Seilhean D, Noel LH, et al. Inhibition of the mTORC Pathway in the Antiphospholipid Syndrome. *N Engl J Med*. 2014;371(4):303-312.
 26. Belizna C, Pregolato F, Abad S, Alijotas-Reig J, Amital H, Amoura Z, et al. HIBISCUS: Hydroxychloroquine for the Secondary Prevention of Thrombotic and Obstetrical Events in Primary Antiphospholipid Syndrome. *Autoimmun Rev*. 2018;17(12):1153-1168.
 27. Massimo R, Irene C, Elena R, Grazietta FS, Alice B, Elisa M, et al. Treatment of Antiphospholipid Syndrome. *Clinical Immunology*. 2020.
 28. Mekinian A, Costedoat-Chalumeau N, Masseau A, et al. Obstetrical APS: Is There a Place for Hydroxychloroquine to Improve the Pregnancy Outcome? *Autoimmun Rev*. 2015; 14:23-29.
 29. Riancho-Zarrabeitia L, Daroca G, Munoz P, Lopez-Hoyos M, Haya A, and Martinez-Taboada VM. Serological Evolution in Women with Positive Antiphospholipid Antibodies. *Semin Arthritis Rheum*. 2017;47(3):397-402.
 30. Zen M, Loreda Martinez M, Benvenuti F, Gatto M, Saccon F, Larosa M, et al. Prevalence, Outcome and Management of Patients with SLE and Secondary Antiphospholipid Antibody Syndrome after aPL Seroconversion. *Rheumatology (Oxford)*. 2020.
 31. Chaturvedi S, McCrae KR. Diagnosis and Management of the Antiphospholipid Syndrome. *Blood Rev*. 2017;31(6):406-417.
 32. Rodziewicz M, and D'Cruz DP. An Update on the Management of Antiphospholipid Syndrome. *Therapeutic Advances in Musculoskeletal Disease*. 2020;12.



This work is licensed under Creative Commons Attribution 4.0 License

To Submit Your Article Click Here: [Submit Manuscript](#)

DOI: [10.31579/2641-0419/0116](https://doi.org/10.31579/2641-0419/0116)

Ready to submit your research? Choose Auctores and benefit from:

- ❖ fast, convenient online submission
- ❖ rigorous peer review by experienced research in your field
- ❖ rapid publication on acceptance
- ❖ authors retain copyrights
- ❖ unique DOI for all articles
- ❖ immediate, unrestricted online access

At Auctores, research is always in progress.

Learn more www.auctoresonline.org/journals/clinical-cardiology-and-cardiovascular-interventions