

## Cervical manipulation and cerebrovascular ischemia. A rare but dangerous association. Monocentric experience in a high CEA volume center and literature review.

Ascoli Marchetti Andrea<sup>1\*</sup>, Oddi Fabio Massimo<sup>1</sup>, Battistini Martina<sup>1</sup>, De Liso Alfredo<sup>2</sup>, Testa Alessandro<sup>2</sup>, Pallocchi Matteo<sup>2</sup> Ippoliti Arnaldo<sup>1</sup>

<sup>1</sup>Vascular Surgery Unit. Biomedicine and Prevention Department. University of Rome Tor Vergata.

<sup>2</sup>Faculty of Medicine and Surgery. University of Rome Tor Vergata, Rome, Italy.

**\*Corresponding Author:** Andrea Ascoli Marchetti, Vascular Surgery Unit. Biomedicine and Prevention Department. University of Rome Tor Vergata. Viale Oxford 81 00133 Rome Italy.

**Received date: June 27, 2020; Accepted date: July 09, 2020; Published date: July 14, 2020.**

**Citation:** Ascoli Marchetti A., Oddi F.M., Battistini M., De Liso A., Testa A, Pallocchi M., Ippoliti A. (2020) Cervical manipulation and cerebrovascular ischemia. A rare but dangerous association. Monocentric experience in a high CEA volume center and literature review. *J Neuroscience and Neurological Surgery*. 6(4); DOI:10.31579/2578-8868/125

**Copyright:** © 2020 Andrea Ascoli Marchetti, This is an open-access article distributed under the terms of the Creative Commons Attribution License, which permits unrestricted use, distribution, and reproduction in any medium, provided the original author and source are credited.

### Abstract

**Background:** A correlation between stroke and cervical manipulation in the neck is reported in the literature with increasing frequency, and each new publication seems to rekindle the debate. The manipulations in the cervical region is potentially dangerous for arterial vessels. The aim of this work is to analyze the incidence of these events in the experience of a center with high volume surgery, in which emergency interventions are performed for acute cerebrovascular Ischemia.

**Methods:** Data were collected regarding patients undergoing carotid endarterectomy surgery for neurological symptoms of cerebrovascular insufficiency over a seven-year period.

**Results:** The intervention was conducted urgently in 66 cases for acute symptoms (7.6%) with a median symptom interval / CEA:  $39.4 \pm 5.4$  h) in 32 cases for hemispheric transient ischemic attack, while in 34 for minor stroke. Only in 1 case (1.5%) did a condition of severe spondyloarthrosis of the cervical spine occur in acute carotid plaque in C4-C5. In another case (1.5%) a cervical trauma caused by beatings is documented.

**Conclusions:** Manipulations of the neck and cervical spine can rarely cause or contribute to worsening neurological symptoms, however they should always be considered.

**Keywords:** cerebral ischemia; carotid surgery; neck manipulation; cervical spine; emergency surgery; artery dissection; vascular surgery volume center; cervical trauma; cerebrovascular insufficiency; acute carotid plaque; cervical manipulation; rehabilitation

### Introduction

The manipulations of the cervical spine and neck, performed by the physiotherapy specialist or as a part of assault, involve a maneuvers which may influence the carotid and vertebral arteries [1]. A correlation between stroke and cervical manipulation is reported in the literature with increasing frequency. Specific risk factors related to cerebrovascular complications following manipulation of the cervical spine have not yet been identified [2]. for this reason, each patient is to be considered susceptible to this risk, especially if over 45 [3]. Patients undergoing spinal manipulative therapy must, therefore, informed of the possible risk, express a consent, aware of the possibility, albeit remote, of stroke or vascular lesions [4].

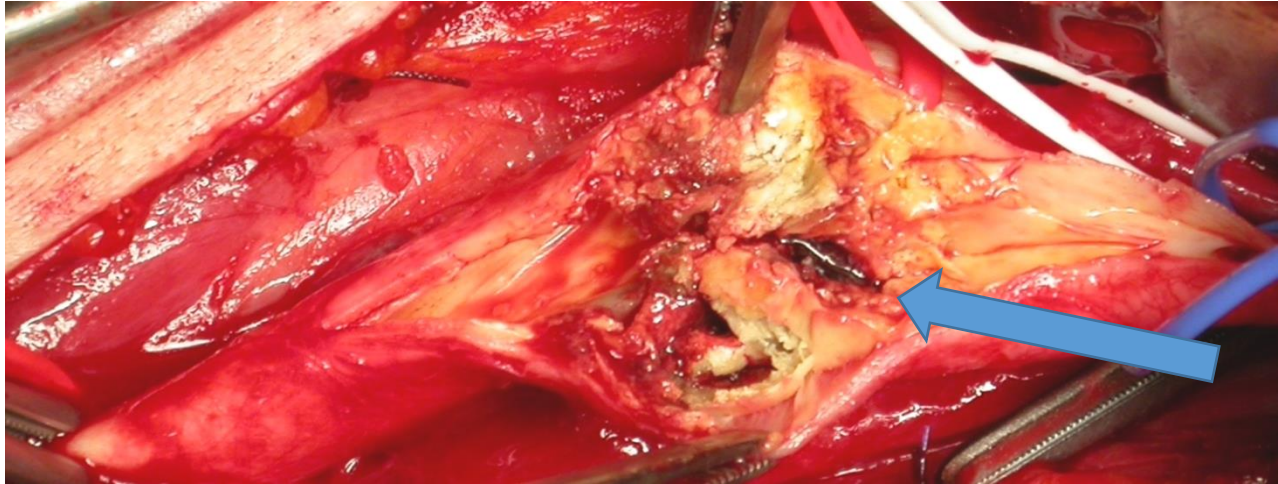
### Materials and Methods

Institutional review board approval for the study and written informed consent from all patients or surrogate decision-makers were obtained. A retrospective analysis of prospective data collected from consecutive patients with TIA or ischemic stroke admitted to the hospital between October 2012 and December 2019 was analyzed. We collected 873 carotid

endarterectomy (CEA) operations. Of these surgical procedures, 66 (7.6%) were conducted in an emergency for acute neurological symptoms (median symptom interval / CEA:  $39.4 \pm 5.4$  h), in 32 cases for hemispheric transient ischemic attack (TIA), while in 34 for minor stroke. Color duplex ultrasound (US) imaging and/or multislice computed tomographic (CT) angiography examination were employed to define the site, length, and degree of stenosis as well as the structure of the carotid bifurcation morphology. An ischemic stroke was defined as any new, persistent neurologic deficit caused by disturbances in the blood supply to the brain with acute infarction visible on MRI or CT scan. Selection criteria for a possible extracranial revascularization procedure were the presence of an atherosclerotic carotid artery lesion located on the clinically relevant side with a stenosis of 70% or an unstable 50%–69% stenosis (i.e.: ulcerated lesions and/or thrombus in the lumen) [5-6].

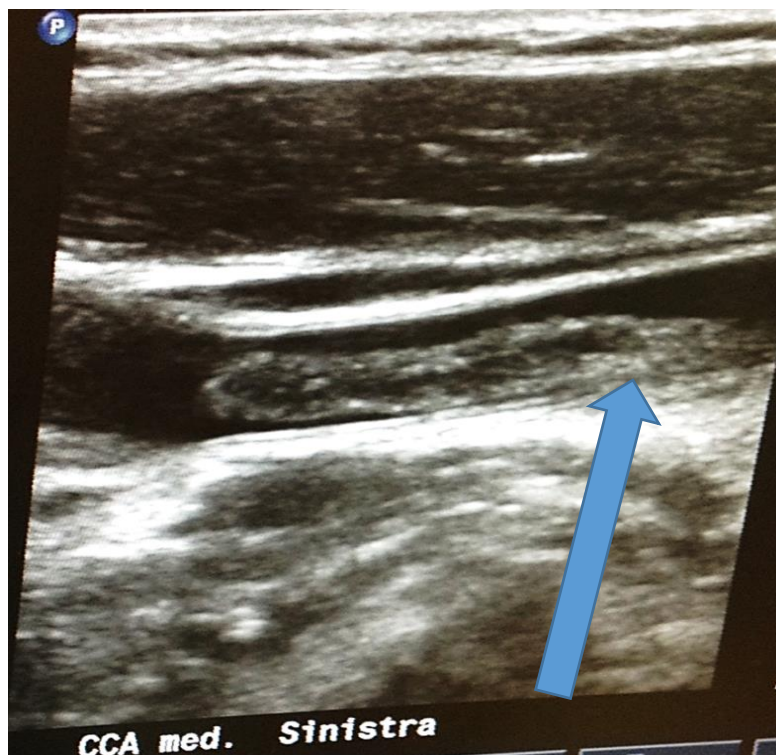### Results

Only in 1 case (1.5%) did a condition of severe spondyloarthrosis of the cervical spine occur in acute carotid plaque in C4-C5 (**Figure 1**).



**Figure 1:** Carotid Endarterectomy performed in emergency. Intraoperative image of carotid endarterectomy performed in emergency: tight stenosis. The arrow indicates the thrombus

In another case, CEA was performed in a patient with an ischemic stroke and floating thrombosis in dissection of the common carotid artery after cervical trauma caused by beatings (**Figure 2**) [7].



**Figure 2:** Ecodoppler of left carotid bifurcation: the arrow indicate the site of dissection and the origin of floating thrombosis

The results of our urgent case studies are in line with those reported in the literature [8]. The 30-day IMA/stroke rate was 7.6% (5 cases), with a mortality rate of 1.8%. In 53.1% of cases, we reported an improvement in neurological deficits. At follow-up (FU-mean of 22 months, with interval 3-39), we observed 2 carotid restenosis (3.1%) and a new neurological deficit in 4 cases (6.1%).

## Discussion

### Etiology

It is well known that in chronic inflammatory rheumatic diseases, systemic inflammation can act independently or in synergy with traditional cardiovascular risk factors, contributing to the development of

cerebrovascular complications [3]. and Gonzalez-Gay et al. [9], studied 64 ankylosing spondylitis patients and documented a greater carotid myointimal thickness (IMT) and a higher frequency of atrophic carotid plaques than the control population. To date, numerous absolute and relative contraindications to the FKT maneuvers to treat these arthritic patients have been identified. Patients with severe herniated discs are exposed to greater risks of cerebrovascular complications during these practices. [10] In 1934 the first scientific-legal work was published on the detection of cerebrovascular accidents after manipulation of the spine. In a recent paper Thomas and colleagues report the manipulation of the neck as a risk factor for dissection in cervical area [11]. The proximity of the vertebral artery to the vertebral bodies (in C1 and C2) can play a crucial role in the development of dissection. The greater mobility compared to the anatomical planes of the vertebral artery in V1-V2 can also be a favoring factor for

stretching injuries [12]. To confirm this hypothesis, segment V3 is the most frequent site where dissection takes place. However, dissections are also described in other segments of the vertebral artery. Dissection of the carotid artery is rarer during chiropractic maneuvers, probably because it is surrounded by soft tissues and less contiguous with the bone planes. For this reason, carotid dissection is presumed to result from compression of the artery against both transverse processes or against the soma of the cervical vertebrae, as in our previous described case [7]. The pharyngeal segment of the internal carotid artery, extending from the carotid bifurcation to its entry into the petrous portion of the temporal bone is less mobile, and therefore more susceptible to injury. Although these adverse events tend to be self-limiting, serious cerebrovascular adverse events, such as TIA and stroke, are reported in various series in the literature (**Table 1**).

First Author (year)	Patients	Country	Length of observation	Therapist(s)	Nature of adverse effect	Case previously published	Outcomes	Causality
Haldemann (2002) (24)	64 mostly young women	USA and Canada	16 years	Not mentioned	Cerebrovascular accidents	no	2 deaths. Most patients had persistent deficits	Cannot be evaluated
Young (2003) (25)	9 patients (8 women, 1 men) aged 34-70 years	Taiwan	3 years	5x chiropractor 4xTCM practioner	Acute vertigo	Not mentioned	Complete recovery in all cases after dextram infusions	Likely
Hansis (2004) (26)	57 cases of legal malpractice referred to the North Rhine General Medical Council	Germany	28 years	Not mentioned	Any	Not mentioned	Varied	Cannot evaluated
Oppenheim (2005) (27)	18 patients from one neurosurgical practice with non-vascular complications after SM an worsening of syntoms immediately after DM	USA	6 years	Chiropractor	Non-vascular	Not mentioned	Mostly excellent or good	In most cases certain or likely
Reuter (2005) (28)	40 cases after upper SM from 13 neurological departments	Germany	3 years	Any type of health-care professional	Vertebral artery dissection	Not mentioned	10 symptom-free, 1 fatality, remaining patients had symptoms of varying severity	In most cases certain or likely
SM, spinal manipulation								

**Table 1:** Retrospective case series of adverse events after spinal manipulation

More specifically, lesions such as dissection of the common, vertebral, internal carotid artery, or vertebrobasilar segment have been found following manipulation of the cervical spine. ). Sports, assault and road accidents are the principal etiology for blunt trauma of the neck and no definitive management guidelines regarding this type of injury exist, our reports emphasizes the role of conservative anticoagulation therapy in the

management of this rare condition, on the contrary in our experience, the approach was surgical. [13].

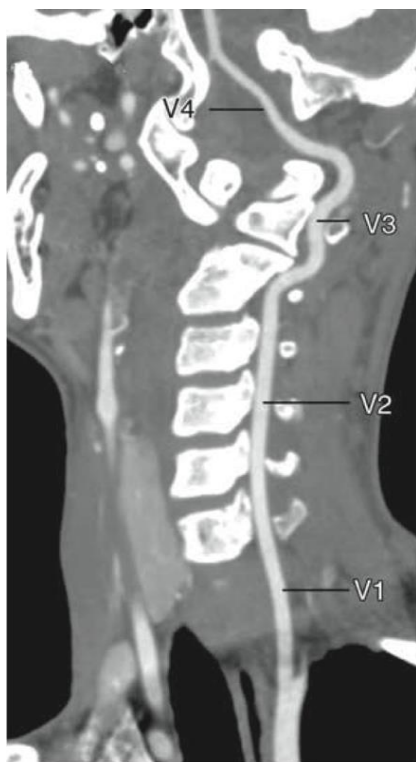**Physiopathology**

Shari W et al. confirm with their study the rarity of cerebrovascular events following physiotherapy maneuvers. Of these events, 70% are vertebral artery and carotid dissections [12]. These injuries are due to intimal

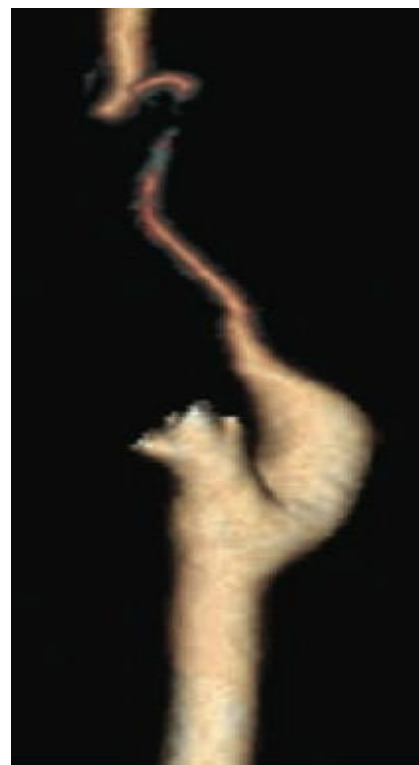
laceration related to excessive stretching of the artery during rotational manipulation. This seems to occur more commonly on the wall of the vessel which runs at the atlanto-epistrophe joint. Intimal injury can be followed by hemorrhage, pseudoaneurysm, intramural formation, resulting in thrombosis, embolism or arterial spasm. Currently, in consideration of the possible complications related to cervical manipulations, some physiotherapists require pre-treatment diagnostic screening in those patients who have cardiovascular risk factors. In fact, based on post-mortem studies on human vertebral arteries, Cagnie et al. [14] have suggested that, in the presence of atherosclerotic alterations, the maneuvers of elongation of the spine and the compression effects related to rotational manipulations of the head represent a concrete risk factor for the aforementioned vascular lesions. Therefore, therapists should avoid performing manipulative techniques at all levels of the cervical spine in the presence of any direct or indirect signs of atherosclerotic disease or in the presence of calcified or tortuous arteries [15-17]. Sports, assault and road accidents are the principal etiology for blunt trauma of the neck and no definitive management guidelines regarding this type of injury exist, our reports emphasizes the role of conservative anticoagulation therapy in the management of this rare condition, on the contrary in our experience the approach was surgical [18,19].

## Diagnosis

The ecocolor Doppler is considered the gold standard in identifying lesions of the epi-aortic vessels in their extracranial course [17]. The ecocolor Doppler allows determining the direction of the blood flow (i.e., antegrade or retrograde), using the color and flowmetric method, which is particularly useful in identifying lesions upstream and downstream of the extracranial traits that can be explored and in determining a functional assessment of intracranial circulation. Particularly useful in the evaluation of proximal subclavian stenosis with subclavian steal syndrome. In addition to the directional information, the ultrasound method can provide flow velocity and therefore to allow hemodynamic analysis of any vascular lesion [17]. Unfortunately, this instrumental method has as its limit the precise morphological evaluation of the vertebral arteries in its ostia and intracranial features. Normal flow in the vertebral artery is typically pandiastolic, because the supply is for a low resistance vascular bed (LR). A high-resistance signal (HR) in vertebral territory with the loss of the characteristic diastolic flow, may indicate a more distal vertebrobasilar lesion. Magnetic resonance imaging (MRI) and CT angiography (CTA) offer potential advantages for the non-invasive assessment of vascular lesions; in particular, they have proved to be useful for the evaluation of dissections (Figure 3 a, b) [13,19,20].



A



B

**Figure 3 a:** Classification of vertebral artery segments. (20)

**Figure 3 b:** Dissection of the left cervical ICA. (20)

Typically, the most used magnetic resonance imaging (MR) techniques for the evaluation of arterial dissection include T1-weighted images (T1WI), T2-weighted images (usually with spatial presaturation), with or without fat suppression, and magnetic resonance angiography (MRA). In particular, the diffusion sequences (T1WI) can provide direct visualization of intramural

hematoma, even if subacute. T1-weighted images (3D - BB - T1WI) can also improve the evaluation of intramural hematomas, further completing the diagnostic evaluation. The MRI appears the gold standard in early thrombectomy protocols, when intracranial vessels are involved [19].

## Treatment

Dissections, if diagnosed, are managed through conservative treatment, involving the use of anticoagulants<sup>(21)</sup>. The prognosis of medical treatment is generally favorable, where it concerns self-limiting lesions. Surgical or endovascular revascularization is reserved for patients with persistent or recurrent symptoms that do not respond to anticoagulant therapy<sup>(7)</sup>. As for medical therapy, there is no evidence from randomized studies<sup>(21-22)</sup> to determine whether, in carotid dissections, the use of antiplatelet therapy is superior to anticoagulant therapy. Endovascular interventions conducted for the treatment of cerebral ischemic complications following the dissection of epiaortic vessels represent an effective method especially in the case of distal lesions. These interventions are represented by mechanical thrombectomy and stenting of intracranial vessels. Stenting of the carotid or vertebral artery has been reported in patients with recurrent embolism, hemodynamic stroke, or in case of a volumetric increase in pseudoaneurysmal lesions. Besides, stenting on dissection, followed by intra-arterial infusion of thrombolytic agents, is considered a further therapeutic chance in the selected cases, where acute thrombotic occlusion phenomena of dissecative lesions or in the case of intramural hematomas complicated by thrombotic events are concomitant. In the event of phenomena of acute thrombosis affecting the common carotid and internal extracranial carotid artery, mechanical thrombectomy and stenting or thromboendoarterectomy of carotid bifurcation are reported, where, even if there are no bleeding or distal thrombotic complications, according to the study protocols implemented with the Stroke Unit<sup>(23)</sup>.

## Conclusion

Patients with carotid or vertebral atheromasia associated with chronic inflammatory disease of the spine seems to present a higher risk of cerebrovascular complications, but further analysis should be necessary to establish the exact role in cerebrovascular disease. An adequate diagnostic screening to prevent possible vascular cerebrovascular complications in patients with cardiovascular risk factors, should be done, before manipulations of the cervical spine. In case of assault the carotid axis is anatomically predisposed to dissection and in case of neurological symptoms a diagnostic evaluation should be done.

## References

- Di Fabio R P. (1999) Manipulation of the cervical spine: risks and benefits. *Physical Therapy* 79(1): 50-65.
- Wynd S, Estaway M, Vohra S, Kawchuk G (2015) Correction: The Quality of Reports on Cervical Arterial Dissection following Cervical Spinal Manipulation. *PLOS ONE* 10(6): e0130221
- Biller J, Sacco RL, Albuquerque FC, Demaerschalk BM, Fayad P., et al. (2014) on behalf of the American Heart Association Stroke Council. Cervical arterial dissections and association with cervical manipulative therapy: a statement for healthcare professionals from the American Heart Association/American Stroke Association. *Stroke*. 45: 3155–3174.
- Ernst E, (2010) Vascular accidents after neck manipulation: cause or coincidence? *Int J Clin Pract*, May 64, 6, 673–677.
- Jauch EC, Saver JL, Adams HP Jr, Bruno A, Connors JJ, Demaerschalk BM,; (2013) Guidelines for the early management of patients with acute ischemic stroke: a guideline for healthcare professionals from the American Heart Association/American Stroke Association. American Heart Association Stroke Council; Council on Cardiovascular Nursing; Council on Peripheral Vascular Disease; Council on Clinical Cardiology. *Stroke*. Mar;44(3):870-947.
- Powers WJ, Rabinstein AA, Ackerson T, Adeoye OM, Bambakidis NC. (2018) Guidelines for the Early Management of Patients With Acute Ischemic Stroke: A Guideline for Healthcare Professionals From the American Heart Association/American Stroke Association. American Heart Association Stroke Council. *Stroke*. Mar;49(3):e46-e110
- Ascoli Marchetti et al. (2019) Ischemic stroke and floating thrombosis in dissection of the common carotid artery in patient at third week of pregnancy: Surgical technical success and maintenance of pregnancy; *SAGE Open Medical Case Reports*. Feb. Vol 7: 1–4
- Brott TG, Halperin JL, Abbara S, Bacharach JM, Barr JD, Bush RL, et al. (2013) ASA/ACCF/AHA/AANN/AANS/ACR/ASNR/CNS/SAIP/SCAI/SIR/SNIS/SVM/SVS Guideline on the management of patients with extracranial carotid and vertebral artery disease: executive summary. Developed in collaboration with the American Academy of Neurology and Society of Cardiovascular Computed Tomography. *Catheter Cardiovasc Interv*. Jan1;81(1):E76-12
- Gonzalez-Gay MA, Gonzalez-Juanatey C, Piñeiro A, et al. (2005) High-grade C-reactive protein elevation correlates with accelerated atherogenesis in patients with rheumatoid arthritis. *J Rheumatol*. 32(7):1219-1223.
- Paciaroni M, Bogousslavsky J. (2009) Cerebrovascular Complications of Neck Manipulation. *European Neurology*. *Eur Neurol* 61:112–118
- Thomas LC, (2016) Cervical arterial dissection: an overview and implications for manipulative therapy practice, *Man Ther*. Feb;21:2-9
- Shari Wyndet, Michael Westaway, Sunita Vohra, Greg Kawchuk,; (2013) The Quality of Reports on Cervical Arterial Dissection following Cervical Spinal Manipulation. *PLOS ONE* 1 March Volume 8; Issue 3; e59170
- Cheddie S, Pillay B, Goga R. (2013) Bilateral blunt carotid artery injury: a case report and review of the literature. *S Afr J Surg*. May 3;51(2):77-79.
- Cagnie B, Barbaix E, Vinck E, D'Herde K, Cambier D: (2006) Atherosclerosis in the vertebral artery; an intrinsic risk factor in the use of spinal manipulation? *Surg Radiol Anat* 28:129–134.
- Pezzini A, Del Zotto E, Padovani A: (2002) Hyperhomocysteinemia: a potential risk factor for cervical artery dissection following chiro-practic manipulation of the cervical spine. *J Neurol* 249:1401–1403.
- Ernst E: Spinal manipulation: its safety is un-certain. *Can Med Assoc J* 2002; 166:40–41.
- Haynes MJ: (2002) Vertebral arteries and cervical movement: Doppler ultrasound velocimetry for screening before manipulation. *J Manipulative Physiol Ther* 25:556–567.
- Takano K. MRI of intracranial vertebral artery dissection: evaluation of intramural haematoma using a black blood, variable-flip-angle 3D turbo spin-echo sequence. *Neuroradiology* (2013) 55:845–851
- Provenzale JM, Sarikaya B. (2009) Comparison of test performance characteristics of MRI, MR angiography, and CT angiography in the diagnosis of carotid and vertebral artery dissection: a review of the medical literature. *Am J Roentgenol* 193:1167–1174
- Rodallec MH, Marteau V, Gerber S et al. (2008) Craniocervical arterial dissection: spectrum of imaging findings and differential diagnosis. *Radiographics* 28:1711–1728
- A. Arauz, A. Ruiza, G. Pacheco, P. Rojas, M. Rodríguez-Armida, C. et al. (2010) Barinagarmenteriae, Aspirin versus anticoagulation in intra- and extracranial vertebral artery dissection *European Journal of Neurology* 2013, 20: 167–172
- Lyrer P,; Antithrombotic drugs for carotid artery dissection (Review) *The Cochrane Library* 10; 6. CD000255.

23. Rocco A, Sallustio F, Toschi N, et al. (2018) Carotid Artery Stent Placement and Carotid Endarterectomy: A Challenge for Urgent Treatment after Stroke-Early and 12-Month Outcomes in a Comprehensive Stroke Center..J Vasc Interv Radiol. Sep;29(9):1254-1261.e2.
24. Haldeman, Et Al. (2002) Unpredictability of Cerebrovascular Ischemia Associated With Cervical Spine Manipulation Therapy. Spine 1:27
25. Young YH, Chen CH. (2003) Acute Vertigo Following Cervical Manipulation. Laryngoscope. Apr;113(4):659-662.
26. Hansis ML, Weber B, Smentkowski U, Schröder P. (2004) Accusations of Malpractice in Chirotherapeutic Treatment. Orthopedic. Sep;33(9):1051-1060.
27. Oppenheim JS, Spitzer DE, Segal DH. (2005) Nonvascular Complications Following Spinal Manipulation. Spine J, Nov-Dec 5(6):660-666
28. Reuter U E M Hämling M, I Kavuk I, Einhüpl KM, Schielke E. (2006) Vertebral artery dissections after chiropractic neck manipulation in Germany over three years. Journal of Neurology 253(6):724-730



This work is licensed under Creative Commons Attribution 4.0 License

To Submit Your Article Click Here: [Submit Article](#)

DOI: [10.31579/2578-8868/125](https://doi.org/10.31579/2578-8868/125)

**Ready to submit your research? Choose Auctores and benefit from:**

- ❖ fast, convenient online submission
- ❖ rigorous peer review by experienced research in your field
- ❖ rapid publication on acceptance
- ❖ authors retain copyrights
- ❖ unique DOI for all articles
- ❖ immediate, unrestricted online access

At Auctores, research is always in progress.

Learn more [www.auctoresonline.org/journals/neuroscience-and-neurological-surgery](http://www.auctoresonline.org/journals/neuroscience-and-neurological-surgery)