

Diagnosis Error of a Tuberculoma: Case Report and Review of the Literature

Bekralas H^{1*}, Habchi N¹, Bouallag M¹, Boulaouad W¹, Oumchiche W¹, and Djafer M¹.

¹Department of Neurosurgery, Mustapha PACHA Hospital Algiers, Algeria.

*Corresponding Author : Bekralas Houria , Department of Neurosurgery, Mustapha PACHA Hospital Algiers.

Email: <mailto:nawelmedbio@yahoo.fr>

Received date: **March 07, 2019**; Accepted date : **April 25, 2019**; Published date: **May 03, 2019**.

Citation : Bekralas H , Habchi N , Bouallag M , Boulaouad W , Oumchiche W , and Djafer M. et al. (2019) Diagnosis Error of a Tuberculoma: Case Report and Review of the Literature , J. Neuroscience and Neurological Surgery, Doi: 10.31579/2578-8868/049

Copyright : © 2019 Bekralas H. This is an open-access article distributed under the terms of The Creative Commons Attribution License, which permits unrestricted use, distribution, and reproduction in any medium, provided the original author and source are credited.

Abstract

Among the diagnoses to be mentioned before a brain tumor, that of tuberculosis, has retained a significant place in the developing countries. The extra axial form poses a real problem of differential diagnosis especially with meningioma. We report a case of a cerebral tuberculoma mimicking meningioma. A histological study is necessary in order to make a correct diagnosis and plan an adequate and early medical procedure.

Keywords: cerebral tuberculoma, brain tumor, meningioma.

Introduction

Cerebral tuberculoma represents 1/3 of brain lesions at the beginning of the century,

Its frequency currently varies between 0.15 to 0.18% (U.S.A) and 1.4% to 1.89% in developing countries [1, 3 and 5]. It is often caused by the pathogen MYCOBACTERIUM TUBERCULOSIS.

The extra axial form poses a real problem of differential diagnosis especially with meningioma because often the clinical signs are not very specific with constant absence of an extra cerebral localization and the bacteriological examinations are often negative. Conventional imagery can be evocative [7]. However, it is the cerebral biopsy with histological study which makes it possible to invalidate or confirm the diagnosis.

Case Report :

A young 16-year-old patient is hospitalized in our department for intense headaches with generalized tonic-clinical epileptic seizures evolving since 03 months without any infectious context. These epileptic seizures change in intensity and frequency with two seizures a day. The neurological examination finds a conscious patient, well oriented in time and space without neurological signs in focus. A cerebral CT performed in 5 mm sections, without and with injection of contrast medium, made it possible to demonstrate an expansive formation located at the level of the 1/3 average of the 47/18 mm diameter scythe whose external contour is irregular and intensely enhances after injection of the contrast medium.

A mass effect is noted on the frontal horn and the anterior part of the forearm slightly deviated to the left, this aspect strongly suggests the diagnosis of meningioma. It associates a lesion of the same nature of right fronto-parietal seat. Juxta-50 mm of great axis, surrounded by a peri-lesional edema (figure 1). A cerebral MRI (SE) with axial, sagittal and coronal sequences without and after gadolinium injection revealed two extra-axial edematogenous, well-limited processes of respective sieges at the level of the right frontal-parietal convexity and the middle third of false signal iso signal in T1, hypo signal in T2 enhances strongly after injection of gadolinium and exerting an important mass effect on the corpus callosum and medial structures. They measure respectively 52/33/17 and 74/46/13 mm of major axes (figure 1).

The angio-MR sequence does not aim at abnormality of the superior longitudinal sinus nor of vascular blush. This lesion status argues in favor of a dual localization meningioma.

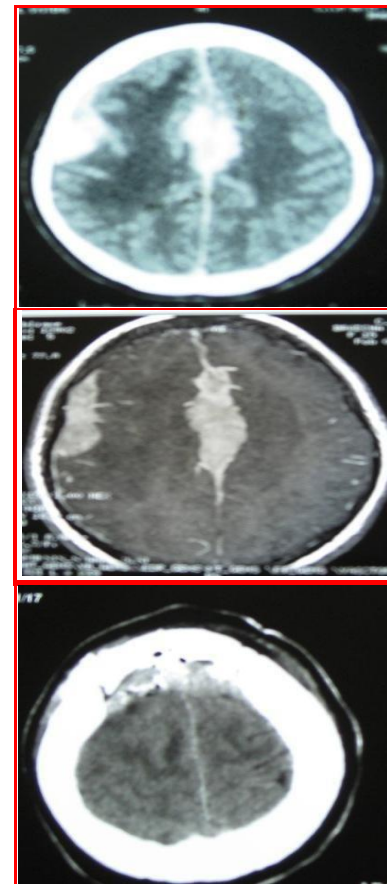


Figure 1 : Imagery of the cerebral tuberculoma

The patient was operated on and tumor excision concerned the falcipital location. A bi-frontal flap with an inter-hemispheric approach revealed, after opening of the thickened dura, an irregularly-shaped encapsulated lesion of yellowish-white color whose cleavage plane is clear with the cortical surface and whose contents are cheesy.

The implantation base of this lesion sits at the level of 1/3 medium of the false without infiltration of the upper longitudinal sinus. The excision is considered total with coagulation of the implantation base.

The postoperative course is considered favorable in the short and long term marked by a decrease and total disappearance of epileptic seizures without associated neurological sequelae. The anatomic pathological study of the mass revealed a central caseous necrosis surrounded by granulomatous lesion made of epithelial cells and lymphocytes.

The histological diagnosis is that of a tuberculoma. Antituberculous treatment was then initiated based on isoniazid (INH) and pyrazinamide (PZA) for 2-4 months followed by an association (INH, rifampicin) and the whole for a total average duration of 12-18 months.

Discussion:

Some tuberculomas can simulate meningiomas [1, 2, 3 and 4] with angiography / signs of vascularization of the mass by the branches of the middle meningeal artery. The only characteristic that can distinguish them from meningioma is iso-intensity on MRI with marked peri-lesional edema on the T2 sequence[7]. However, these images are inconstant and the definitive diagnosis is based on all the biological, radiological and histological examinations [1,2 and 6].

Intra-cranial tuberculosis responds well to anti-tuberculosis treatment, however an increase in the size of the tuberculoma can be seen during the treatment period and it should be continued for 12-30 months without change of anti-tuberculosis agents. The indication for surgery is based on signs of HIC, epileptic seizures, neurological signs in focus and in case of non-response to medical treatment. The clinical improvement is seen after 3 months of treatment of 9-12 months, although the radiological signs tend to regress after 6 to 8 weeks.

Conclusion:

Cerebral tuberculoma is a significant lesion in developing countries. Although the diagnosis of tuberculoma rarely conceals that of meningioma in extra axial locations; its possibility is not to be discarded and must be taken as a differential diagnosis.

References:

1. Shindo A, Honda C, Baba Y. (1999), A case of an intracranial tuberculoma, Mimicking meningioma That developed during treatment with anti-tuberculous agents. *No Shinkei Geka* 27:837–41 [(medline)
2. Isenmann S, Zimmermann DR, Wichmann W, (1996), Tuberculoma mimicking meningioma of the falx cerebri. PCR diagnosis of mycobacterial DNA from formalin-fixed tissue. *Clin Neuropathol* 15:155–58[Medline)
3. Di Patre PL, Radziszewski W, Martin NA, Alexander Vinters, and Harry V, et al. (2000), A meningioma mimicking tumor caused by Mycobacterium avium complex in an immunocompromised patient. *Am J Surg Pathol* 24:136–39
4. Adachi K, Yoshida K, Tomita H . (2004), Tuberculoma mimicking falx meningioma–case report. *Neurol Med Chir Neurol Med Chir (Tokyo)* 44:489–92 (medline)
5. Bauer J, Johnson RF, Levy JM, Donald V. Pojman and John R. Ruge et al. (1996), Tuberculoma presenting as an en plaque meningioma. Case report. *J Neurosurgery* 85:685–88
6. Lindner A, Schneider C, Hofmann E, N.SoerensenM.D.K.V.Toyka M.D. et al. (1995) Isolated meningeal tuberculoma mimicking meningioma: case report. *Surg Neurol* 43:81–84
7. Batra A, Tripathi RP. (2004) Diffusion-weighted magnetic resonance Imaging and magnetique résonance spectroscopy in the evaluation of focal cerebral tubercular lesions. *Acta Radiol* 45:679–88