

Selective Neurectomy of the Vestibular nerve through a Retrosigmoid approach for the Treatment of vertigo in Ménière's Disease

Duniel Abreu Casas^{1*}, Orestes Lopez Piloto², Norbery J. Rodríguez de la Paz³, Oscar Quiroz Osorio¹, Emmanuel Batista Geraldino², Liana Pórtela Hernández³, Calixto Machado⁴

¹Functional Surgery Working Group, Department of Neurosurgery of the Institute of Neurology and Neurosurgery, Havana, Cuba.

²Endoscopic and Skull Base Surgery Working Group, Department of Neurosurgery of the Institute of Neurology and Neurosurgery, Havana, Cuba.

³Spinal Surgery Working Group, Department of Neurosurgery of the Institute of Neurology and Neurosurgery, Havana, Cuba.

⁴Department of Clinical Neurophysiology of the Institute of Neurology and Neurosurgery, Havana, Cuba.

***Corresponding Author:** Duniel Abreu Casas, MD, Institute of Neurology and Neurosurgery of Cuba, Department of Neurosurgery, Spinal Surgery Working Group, 29th street to D, Vedado, Habana. Cuba.

Received date: March 13, 2021; **Accepted date:** April 26, 2021; **Published date:** May 05, 2021

Citation: Duniel Abreu Casas., Orestes Lopez Piloto., Norbery J. Rodríguez de la Paz., Oscar Quiroz Osorio., Emmanuel Batista Geraldino., et al., (2021) Selective Neurectomy of the Vestibular nerve through a Retrosigmoid approach for the Treatment of vertigo in Ménière's Disease. *J. Neuroscience and Neurological Surgery*. 8(4); DOI:[10.31579/2578-8868/170](https://doi.org/10.31579/2578-8868/170)

Copyright: © 2021 Duniel Abreu Casas, This is an open-access article distributed under the terms of The Creative Commons Attribution License, which permits unrestricted use, distribution, and reproduction in any medium, provided the original author and source are credited

Abstract:

Ménière's disease (also known as Ménière's vertigo) is a condition characterized by disabling recurrent vertigo, sensorineural hearing loss, otic fullness, and tinnitus. There are various treatments to manage this entity, however, in certain cases, the lack of improvement with less aggressive strategies and the great impact on the quality of life of the patient requires radical procedures such as vestibular neurectomy. By means of a lateral suboccipital approach (retrosigmoid craniectomy) the best exposure of the vestibular nerve, its selective isolation and section is obtained, also allowing to preserve hearing and the entire facial nerve supported with neurophysiological monitoring techniques.

Keywords: ménière's disease; retrosigmoid approach; treatment

Introduction

Ménière's disease is a complex and multifactorial disease of the inner ear, characterized by a combination of episodic vertigo with neurovegetative symptoms, sensorineural hearing loss, auditory fullness and tinnitus. Different hypotheses on the mechanism of the disease have been proposed. But currently there is no universally accepted theory about the underlying pathophysiology. Controversy about the relationship between endolymphatic hydrops and Ménière's disease has always been existing, although the cause remains unclear [1].

In its most severe forms it is a very disabling disease¹, mainly due to the vertiginous picture, preventing the patient from leading a normal life. When the disease is resistant to conservative treatment, a vestibular neurectomy should be considered [2,3].

Over the years, different neurosurgical or otoneurological approaches have been proposed to control seizures by sectioning the vestibular nerve and trying to preserve hearing while respecting the cochlear fibers or the structure of the inner ear. One of the treatment options is to perform a neurectomy through a retrosigmoid craniectomy [3,4]

CASE REPORT

It is a 37-year-old man, of skillful handcraft, with no other pathological antecedents, with disabling recurrent rotational vertiginous crises of 5 years of evolution, with severe worsening in recent months, and with a feeling of increasing and continuous instability, causing great impact on their quality of life. He also has severe hearing loss in the right ear. There is no improvement with vestibular rehabilitation exercises, or with the administration of other medical treatments. After the case was evaluated by the Neurosurgeons Collective in the Skull Base Pathology section of the Institute of Neurology and Neurosurgery of Havana, a selective neurectomy of the vestibular nerve is proposed through a right retrosigmoid approach.

In the ¾ prone position, head in the Mayfield-kees head, lateralized to the left (**Figure. 1**), an approach was performed by means of a retrosigmoid craniectomy, about 2cm in diameter. After the dural opening and with the use of a 0 ° endoscope (Karl-zeiss), the cerebellum is carefully separated to reach the cerebellomedullary cistern, where cranial nerves IX, X and XI are identified, ascending later until locating the facial complex - vestibulocochlear at the level of the IAC (**Figure. 2**). After dissection of the arachnoid membranes that cover the vestibulocochlear nerve, identification of the Antero Inferior Cerebellar Artery (AICA) is performed, which is forming a loop over the vestibule-cochlear nerve, indentating the complex and partially separating it. The different nerves

of the complex are identified below, according to existing references in the scientific literature. Neurophysiological monitoring was used at different intensities to identify the facial nerve and respect its anatomical integrity (**Figure. 3**). Subsequently, the vestibular nerve was dissected, selectively separating it from the cochlear nerve, and the neurectomy was performed respecting the fibers of the cochlear nerve to preserve the residual hearing of the patient (**Figure. 4**). A careful hermetic dural

closure was performed with 4.0 braided suture, without the need for dural plasty. After surgery, the patient spent 24 hours in the Intensive Care Unit. In the control CT, no complications derived from the approach were observed, such as the existence of pneumocephalus or cerebellar contusions due to retraction (**Figure. 5**). He was discharged 4 days after surgery,

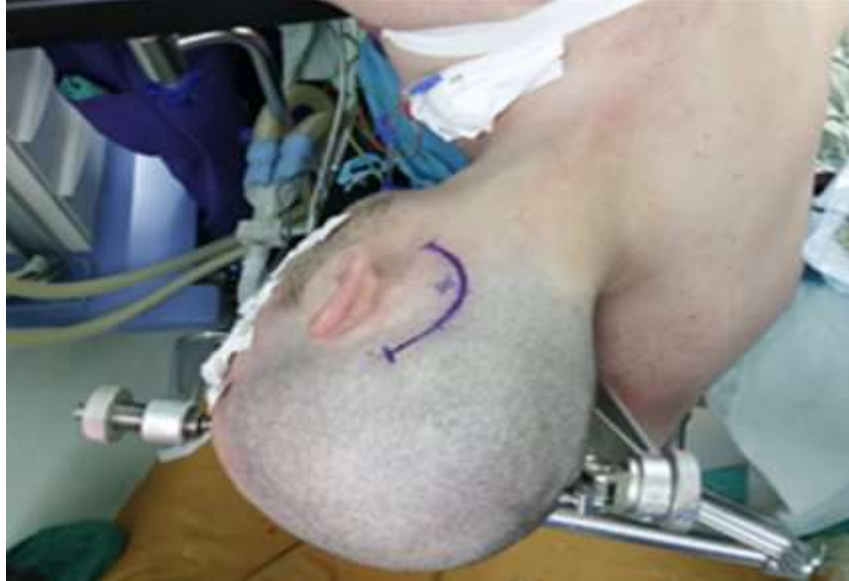

Figure 1. In subsequent clinical check-ups, the patient has experienced a great improvement, with remission of the vertiginous crises. Hearing has experienced a decrease in its level without recovery, after 6 months of control. Finally, it should be noted that given the severe previous right hearing loss and the great impact that Ménière's disease had on their quality of life, the patient and the family reported great satisfaction with the surgical result.

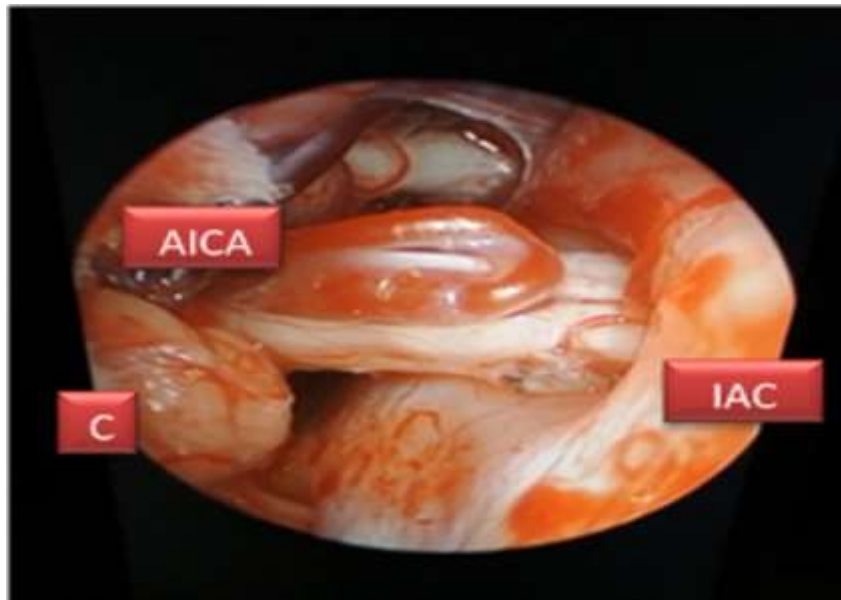


Figure 2. Operative image of the facial-vestibulocochlear complex at the level of its entry into the IAC. The antero-inferior cerebellar artery is looping over the nerve complex, indentating and separating it. C: cerebellum; AICA: antero-inferior cerebellar artery; IAC: internal auditory canal.

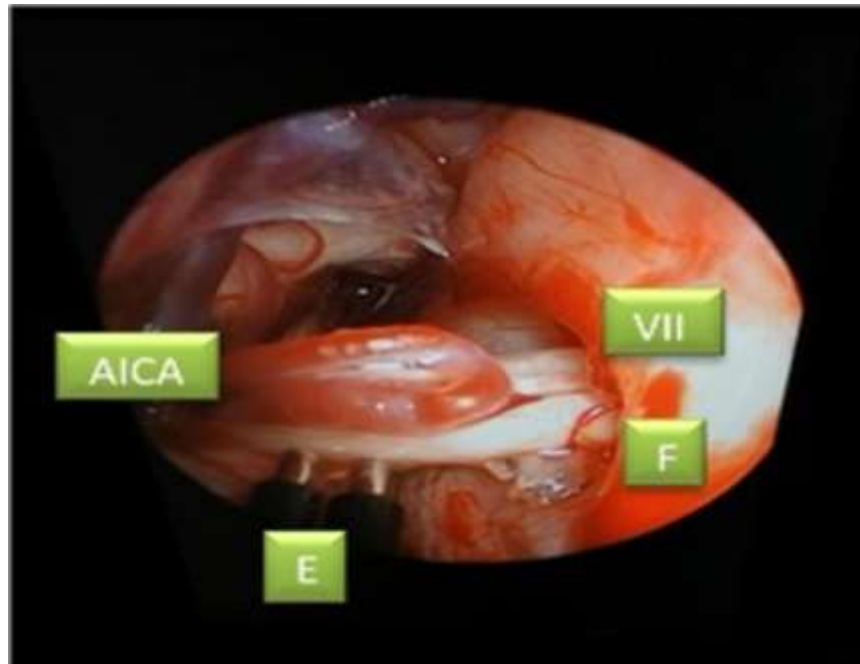


Figure 3. Identification of the facial nerve with neurophysiological help. VIII: Vestibulo-cochlear nerve; F: Facial nerve; AICA: anteroinferior cerebellar artery; E: neurostimulator.

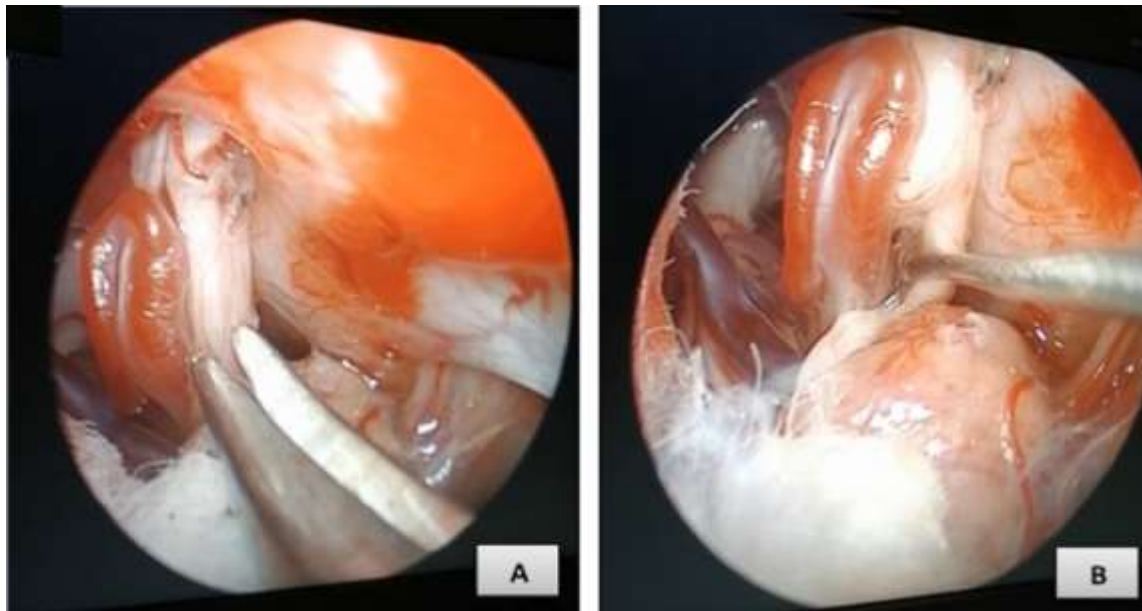


Figure 4. Selective vestibular neurectomy. B. Image showing the section of the vestibular nerve, with preservation of the cochlear component.

In subsequent clinical follow-up studies, the patient has experienced a great improvement, with remission of the vertiginous crises. Hearing has experienced a decrease in its level without recovery, after 6 months of control. Finally, it should be noted that given the severe previous right

hearing loss and the great impact that Ménière's disease had on their quality of life, the patient and the family reported great satisfaction with the surgical result.

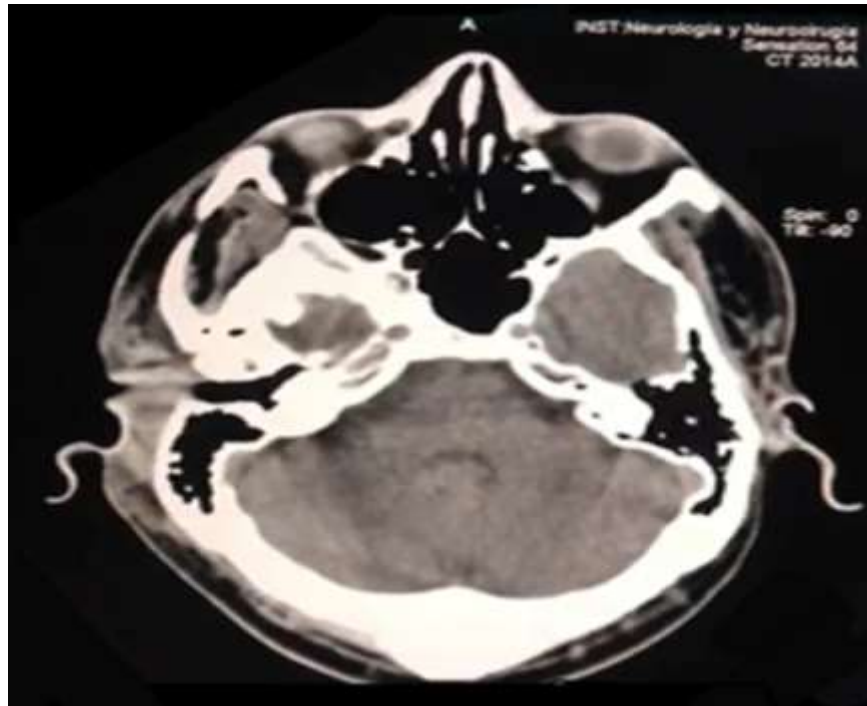
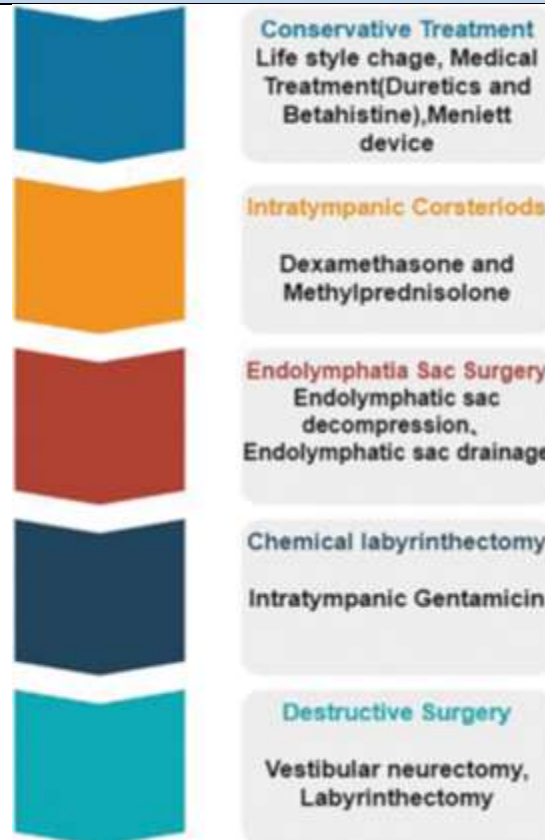

Figure 5. Post-surgical CT at 24h. Note the absence of cerebellar or pneumocephalic contusions.



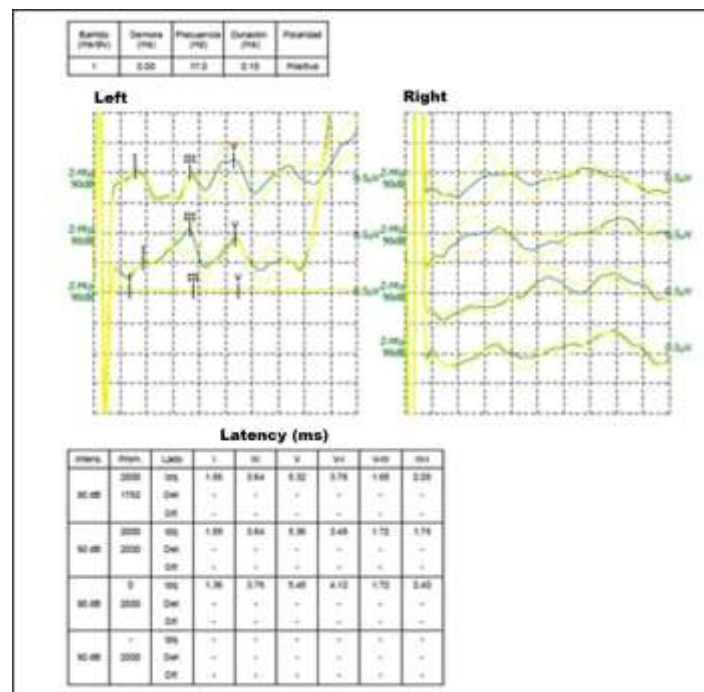


Figure 7. BAEPs (Brainstem Auditory Evoked Potentials). The left-sided waves are normal in latency and amplitude. Note that right-sided waves are delayed in latency, and not-well delineated.

DISCUSSION

Ménière’s disease was described by the French physician Prosper Ménière in 1861, going from being considered a mental illness to a clearly defined entity. Since then, multiple treatments have been proposed to improve the vertiginous crises that constitute the most disabling fact of the disease [5]. In a more conservative way, drug treatments such as loop diuretics (acetazolamide), betahistine, etc., are used to move to more aggressive therapies such as injections of gentamicin or intratympanic corticosteroids, achieving control of the disease between 72-95 %, although it can be associated with hearing loss in a significant percentage of cases [6,7].

It is considered that when this ablative therapy fails, there is the alternative of performing a surgical treatment for which destructive surgeries are performed that entail a complete loss of hearing (labyrinthectomies through its different routes) or performing a selective vestibular neurectomy, managing to respect the hearing [3,7]. There are different surgical routes for this purpose. Historically, in 1898 Krause performed the first neurectomy of the VIII cranial nerve through a retrosigmoid intracranial route. Subsequently, it would be Dandy, one of the pioneers of neurosurgery, who proposed a selective vestibular neurectomy, being performed by McKenzie for the first time in 1936, becoming the approach of choice for many years [6,7]. Later in 1961, House described an extradural microscopic approach to the internal auditory canal through the middle fossa to avoid the complications that occurred in intradural approaches. With this approach, only a neurectomy of the upper vestibular nerve was performed, with poor dizziness control rates. Fisch [9] and Glasscock modify House’s technique to also perform a section of the inferior vestibular nerve, getting good control of seizures and respecting hearing. However, they presented high rates of facial paresis, which is why this approach was not widely used [10].

Currently, thanks to advances in microscopic, endoscopic and neuroanesthesia neurosurgery, the complications of posterior fossa approaches are minimal. By means of the retrosigmoid approach, the best

exposure of the vestibular and cochlear nerve is achieved, being able to perform a complete vestibular neurectomy respecting the cochlear nerve, being equally easy to fully identify and respect the facial nerve with the help of intraoperative neurophysiology.

The vestibular nerve is anterior and superior to the cochlear nerve in its pre-canalicular segment. Also according to some authors, there are differences in the coloration of these, the vestibular nerve being more grayish. Likewise, a fine arteriole can often be identified that is located between the cleavage plane of both nerves, which can be a useful reference [3,4] although it is true that this separation can be difficult to objectify. It should be noted that there may be crossed vestibular fibers in the trunk of the cochlear nerve, for this reason it has been proposed to perform a small section of about 0.5 mm of the cochlear nerve in the area adjacent to the vestibular, to seek to perform a complete neurectomy, without worsening hearing [3].

The control rates using this approach are excellent, being 90-100%. There is a worsening in hearing in 20% of patients, although there are authors who report an improvement rate of 25%. The permanent facial paresis rate is non-existent in most series [3,4]. We believe that the use of neurophysiological monitoring is essential to respect the facial nerve and not generate significant morbidity. The complications derived from brain retraction, with careful microsurgical management, are also minimal. Usually achieving a hermetic dural closure can be difficult, so to prevent CSF fistula various materials such as dural plasties or bioglues can be used, with which this complication is reduced to a minimum, being around 10%.

CONCLUSIONS

The retrosigmoid approach allows an excellent exposure of the vestibular nerve, making it possible to perform a complete and selective neurectomy, with good clinical results.

The help of intraoperative neurophysiology is essential for the correct identification and differentiation of the facial nerve.

Microscopic and endoscopic management and microsurgical instruments are essential to avoid problems in cerebellar retraction, and allow it to be a well-tolerated approach with few complications.

Familiarization of the neurosurgeon with this procedure and joint management with otorhinolaryngology allow adequate control of the disease.

CONFLICT OF INTERESTS

The authors declare that they have no conflict of interest.

REFERENCES

1. Yupeng Liu, Jun Yang & Maoli Duan (2020) Current status on researches of Meniere's disease: a review, *Acta Otolaryngologica*, 140: 10, 808-812.
2. Albera R, Canale A, Parandero F, Ducati A, Lanotte M. Surgical indication in Menière's disease therapy: clinical and epidemiological aspects. *Eur Arch Otorhinolaryngol* 2011; 268 (7): 967-972.
3. Li CS, Lai JT. Evaluation of retrosigmoid vestibular neurectomy for intractable vertigo in Ménière's disease: an interdisciplinary review. *Acta Neurochir (Wien)*. 2008; 150 (7): 655-661.
4. Perez R, Ducati A, Garbossa D, Benech F, Fontanella MM, Canale A, Albera R. Retrosigmoid approach for vestibular neurectomy in Meniere's disease. *Acta Neurochir (Wien)* 2005; 147 (4): 401-404.
5. Silverstein H, Jackson L. Vestibular nerve section. *Otolaryngol Clin N Am* 2002; 35: 655-673.
6. Schmerber S, Dumas G, Morel N, Chahine K, Karkas A. Vestibular neurectomy vs. chemical labyrinthectomy in the treatment of disabling Menière's disease: a long-term comparative study. *Auris Nasus Larynx* 2009; 36 (4): 400-405.
7. Hillman TA, Chen DA, Arriaga MA. Vestibular nerve section versus intratympanic gentamicin for Menière's disease. *Laryngoscope* 2004; 114: 216-222.
8. Eisenman DJ, Speers R, Telian SA. Labyrinthectomy versus vestibular neurectomy: long-term physiologic and clinical outcomes. *Otol Neurotol* 2001; 22 (4): 539-548.
9. Fisch U. Transtemporal supralabyrinthine (middle cranial fossa) vestibular neurectomy: a review of the last 100 cases. *Skull Base Surg* 1996; 6 (4): 221-225.
10. De Diego JI, Prim MP, Melcon E, de Sarriá MJ, Gavilán J. Result of middle fossa vestibular neurectomy in Meniere's disease. *Acta Otorrinolaringol Esp* 2001; 52 (4): 283-286.



This work is licensed under Creative Commons Attribution 4.0 License

To Submit Your Article Click Here: [Submit Manuscript](#)

DOI: [10.31579/2578-8868/170](https://doi.org/10.31579/2578-8868/170)

Ready to submit your research? Choose Auctores and benefit from:

- ❖ fast, convenient online submission
- ❖ rigorous peer review by experienced research in your field
- ❖ rapid publication on acceptance
- ❖ authors retain copyrights
- ❖ unique DOI for all articles
- ❖ immediate, unrestricted online access

At Auctores, research is always in progress.

Learn more www.auctoresonline.org/journals/neuroscience-and-neurological-surgery