

Juvenile Xanthogranuloma: Rare Form of Histiocytosis: About 2 Cases

Selma Benkirane*, Jihane Ziani, Kaoutar Laamari, Sara Elloudi, Zakia Douhi, Fatima Zahra Mernissi

Department of Dermatology, University Hospital Hassan II, Fez, Morocco

*Corresponding Author: Selma Benkirane, Department of Dermatology, University Hospital Hassan II, Fez, Morocco

Received date: May 27 2020; Accepted date: June 22, 2020; Published date: June 25, 2020

Citation: Selma Benkirane, Jihane Ziani, Kaoutar Laamari, Sara Elloudi, Zakia Douhi, Fatima Zahra Mernissi, Juvenile Xanthogranuloma: Rare Form of Histiocytosis: About 2 Cases. J. Clinical Research and Clinical Trials. 2(1); DOI: 10.31579/2693-4779/008

Copyright: Copyright © 2020, Selma Benkirane. This is an open access article distributed under the Creative Commons Attribution License, which permits unrestricted use, distribution, and reproduction in any medium, provided the original work is properly cited.

Abstract

A 06-month-old infant, born from a non-consanguineous marriage, with no notable pathological history, who consults for an asymptomatic nodular lesion of 1cm in diameter at the level of the orange-yellow vertex appeared since the age of 4 months, gradually increasing in size.

Keyword: histiocytosis: rare form; juvenile xanthogranulome ; dermoscopy

Case 1: A 06-month-old infant, born from a non-consanguineous marriage, with no notable pathological history, who consults for an asymptomatic nodular lesion of 1cm in diameter at the level of the orange-yellow vertex appeared since the age of 4 months, gradually increasing in size. The dermatological examination found a yellowish nodule with a smooth surface of firm, rounded and well limited consistency, with regular contours of about 1.2 cm located at the left parietal level [Figure 1 (B)] with a yellowish papule of same appearance on the lateral side of

the left thigh [figure 1 (A)]. The dermoscopic examination had shown the same appearance both in the lesion of the thigh [figure 2 (A)] and the scalp [figure 2 (B)]: a yellow background surrounded by an erythematous border with the presence of a linear vessel at the periphery. The rest of the somatic examination was unremarkable. A biological, radiological assessment and an ophthalmological examination in search of other sites were without particularities. Mothers do not want excision, so close monitoring has been instituted.

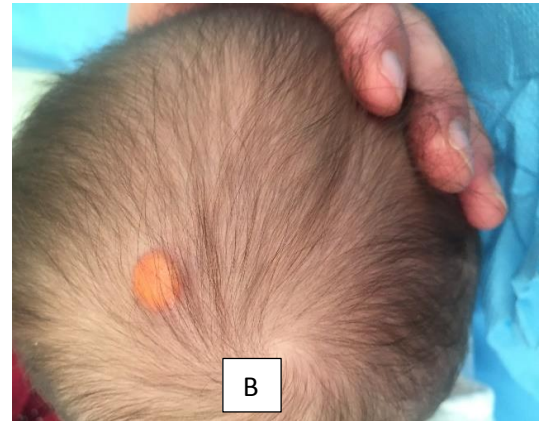
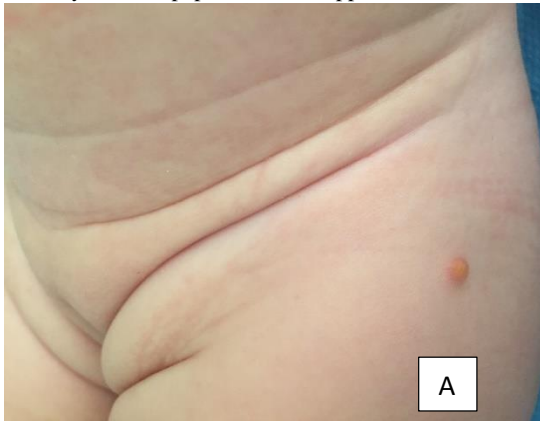


Figure 1: Two yellow-orange lesions in the first infant at the left thigh (A) and at the parietal level (B)

Case 2 : A 03-year-old girl, from a non-consanguineous marriage, with no notable pathological history, who consulted for an asymptomatic nodular lesion of 1cm in diameter at the level of the orange-yellow vertex, evolving for 3 months, gradually increasing in size . The dermatological examination revealed an orange yellow papule 0.5 cm long, well limited with regular contours at the vertex, with a pigmented scarred plaque in the center with the presence of a yellow background [Figure 3 (A)]. The

dermoscopic examination had shown a yellow background surrounded by an erythematous border with the presence of a linear vessel at the periphery [Figure 3 (B)]. The rest of the somatic examination was unremarkable. A biological, radiological assessment and an ophthalmological examination in search of other sites were without particularities. Mothers do not want excision, so close monitoring has been instituted.

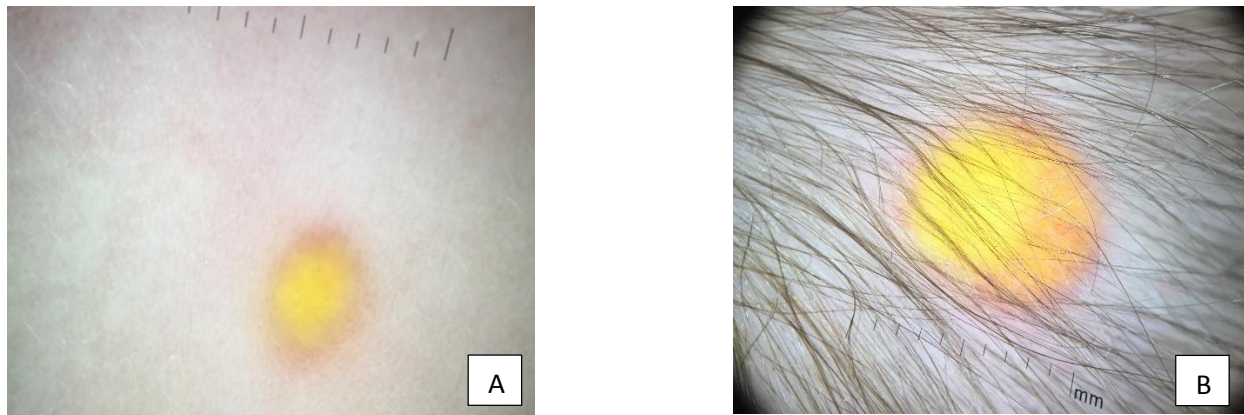


Figure 2 : Dermoscopic image showing the same appearance in both the thigh lesion (A) and the scalp (B): a yellowish background surrounded by an erythematous border

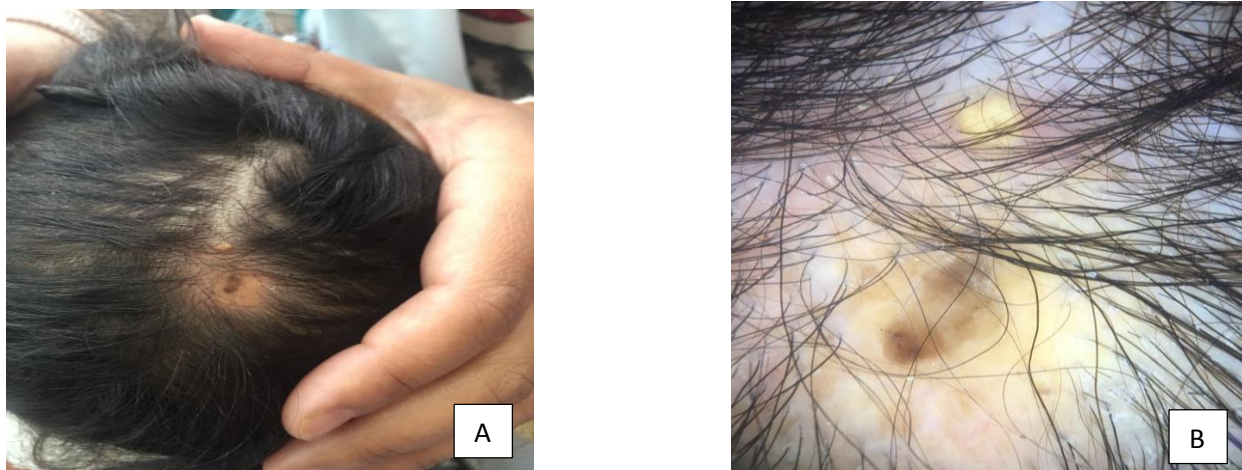


Figure 3: Clinically an orange-yellow papule 0.5 cm long at the vertex (A) with a yellow background on dermoscopy surrounded by erythematous rim (B).

Juvenile xanthogranuloma is a benign skin lesion in infants and young children first reported in 1905 by Adamson, caused by a plasmocytomonocytic proliferation, in response to an unknown etiological agent. It is the least rare of the non-langerhansian histiocytoses. In 1/5 of the lesions are present at birth and in 4/5 of the cases before the age of 1 year [1]. Rare cases have been described in adolescents and even in adults [2]. Classically juvenile xanthogranuloma is a lesion of the skin site, unique, sometimes multiple. The elective seats of juvenile xanthogranuloma are, in decreasing order of frequency, the head, neck, trunk and root of the limbs. Rarely xanthogranuloma can interest the mucous membranes (lip, tongue, palate, gum) [2-3]. Extra cutaneous localizations have also been described in the literature carrying out systemic xanthogranulomatosis [1]. Association with neurofibromatosis is possible [4]. The classic juvenile cutaneous xanthogranuloma produces a papule-like, then nodule-like skin lesion, yellow orange in color with a soft consistency, 5 to 10 mm in diameter. The characteristic histopathological image is that of a dense, well delimited dermal cell infiltrate, composed of histiocytes of variable size and shape as well as an inflammatory granuloma composed of lymphocytes, eosinophilic polynuclear cells and sometimes neutrophils, cell giant, of Touton cells. The evolution is generally favorable, and the lesion spontaneously regresses in almost all cases without sequelae or with slight pigmentation or atrophy and requires no

treatment. In practice, in cases of juvenile xanthogranuloma, the history taking, and clinical examination should focus on the search for extra-cutaneous lesions associated with an ophthalmological examination [1].

Conflicts of interest: Author declares that there is no conflict of interest

References:

- 1- Hagmann C, El-Bahrawy M, Stamp G, Abel RM. (2006). Juvenile xanthogranuloma: a case report of preterm baby. *J pediatr Surg*; 41:573-575.
- 2- Tanyeri H, Weisenberg E, Friedman M. (2000) Juvenile xanthogranuloma of the tongue. *OtolaryngolHead neck surg*; 123:641-642.
- 3- Shimoyama T, Horie N, Ide F. (2000) Juvenile xanthogranuloma of the lip: case report and literature review. *J Oral Maxillofac Surg*; 58:677-9.
- 4- Ananda Kesavan TM, Sreedevi PK. Juvenile xanthogranuloma. *Indian pediatr* 2005; 42:950.