

# Left bundle branch block and Wavy triple sign (Yasser's sign) intertwining COVID-19 Pneumonia with Renal Impairment; defective Sgarbossa criteria for Thrombolytic: A Case Report in Cardiology, Infectious Diseases, Nephrology, and Critical Care Medicine

Yasser Mohammed Hassanain Elsayed<sup>1\*</sup>

<sup>1</sup>Critical Care Unit, Al-Rodah Central Hospital, Damietta Health Affairs, Egyptian Ministry of Health (MOH), Damietta, Egypt.

**\*Corresponding Author:** Yasser Mohammed Hassanain Elsayed, Critical Care Unit, Al-Rodah Central Hospital, Damietta Health Affairs, Egyptian Ministry of Health (MOH), Damietta, Egypt.

**Received date:** April 10, 2021; **Accepted date:** April 18, 2021; **Published date:** May 10, 2021

**Citation:** Elsayed Y M H, (2021). Left bundle branch block and Wavy triple sign (Yasser's sign) intertwining COVID-19 Pneumonia with Renal Impairment; defective Sgarbossa criteria for Thrombolytic: A Case Report in Cardiology, Infectious Diseases, Nephrology, and Critical Care Medicine. *J Thoracic Disease and Cardiothoracic Surgery*, 2(1); DOI:10.31579/2693-2156/020

**Copyright:** © 2021, Elsayed Y M H. This is an open access article distributed under the Creative Commons Attribution License, which permits unrestricted use, distribution, and reproduction in any medium, provided the original work is properly cited.

## Abstract

**Rationale:** Left bundle branch block is a diagnostic utility for ST-segment elevation myocardial infarction equivalent. Consequently, administration of thrombolytic is a pivotal step. Emergent Sgarbossa criteria and their modification are considered helpful guide keys. Wavy triple an electrocardiographic sign (Yasser Sign) is a novel diagnostic sign in hypocalcemia. Interestingly, the presentation of COVID-19 pneumonia with an intertwining left bundle branch block, renal impairment, and hypocalcemia has a risk impact on both morbidity and mortality of COVID-19 patients.

**Patient concerns:** An elderly carpenter male COVID-19 patient was admitted to intensive care unit with COVID-19 pneumonia with interlacing left bundle branch block, renal impairment, and Wavy triple sign (Yasser's sign).

**Diagnosis:** Left bundle branch block and Wavy triple sign (Yasser's sign) intertwining COVID-19 pneumonia with renal impairment.

**Interventions:** Arterial blood gases, chest CT scan, electrocardiography, oxygenation, and echocardiography.

**Outcomes:** Gradual dramatic clinical, electrocardiographic, and radiological improvement had happened.

**Lessons:** The triage of the left bundle branch block with the COVID-19 patient is highly significant for both diagnosis of acute myocardial infarction and giving thrombolytic. The combination of left bundle branch block, renal impairment, and hypocalcemia COVID-19 pneumonia signifies the risk in the current case study.

**Keywords:** COVID-19; pneumonia; left bundle branch block; Wavy triple sign; Yasser's sign; Sgarbossa criteria; renal impairment; tachypneic; cefotaxime; azithromycin; oseltamivir; paracetamol

## Introduction

Left bundle branch block (LBBB) is a common condition in clinical cardiovascular. Suspected acute myocardial infarction (AMI) in the setting of LBBB presents a unique diagnostic and therapeutic challenge to the clinician. The diagnosis is especially difficult due to electrocardiographic changes caused by altered ventricular depolarization. Sgarbossa's criteria were initially very weak and, over time, became highly suggestive of acute ST-segment elevation myocardial infarction (STEMI) [1]. Sgarbossa et al. suggested a score of > 3 points in the next criteria for the diagnosis of AMI in the existence of

LBBB: (1) concordant ST-segment elevation of 1 mm (0.1 mV) in at least 1 lead (5 points), (2) concordant ST-segment depression of at least 1 mm in leads V1 to V3 (3 points), or (3) excessively discordant ST-segment elevation, defined as greater than or equal to 5 mm of ST-segment elevation when the QRS result is negative (2 points) [2]. A modified Sgarbossa rule has been proposed for the diagnosis of AMI in the existence of LBBB [3]. An interesting point regarding this rule, the substitution of the third Sgarbossa element (excessively discordant ST-segment elevation as defined by 5 mm of ST-segment elevation in the setting of a negative QRS) with one defined proportionally by ST-segment elevation to S-wave depth (ST/S ratio) was proposed to have

better diagnostic utility for STEMI equivalent [4]. LBBB concerning acute STEMI is very important. Yasser et al. (2019) reported a case of LBBB with thereafter developed acute STEMI that was indicating for thrombolytic therapy [1]. **Wavy triple an electrocardiographic sign (Yasser Sign)** is a new innovated diagnostic sign in hypocalcemia [5]. The analysis for this sign in the author interpretations are based on the following:

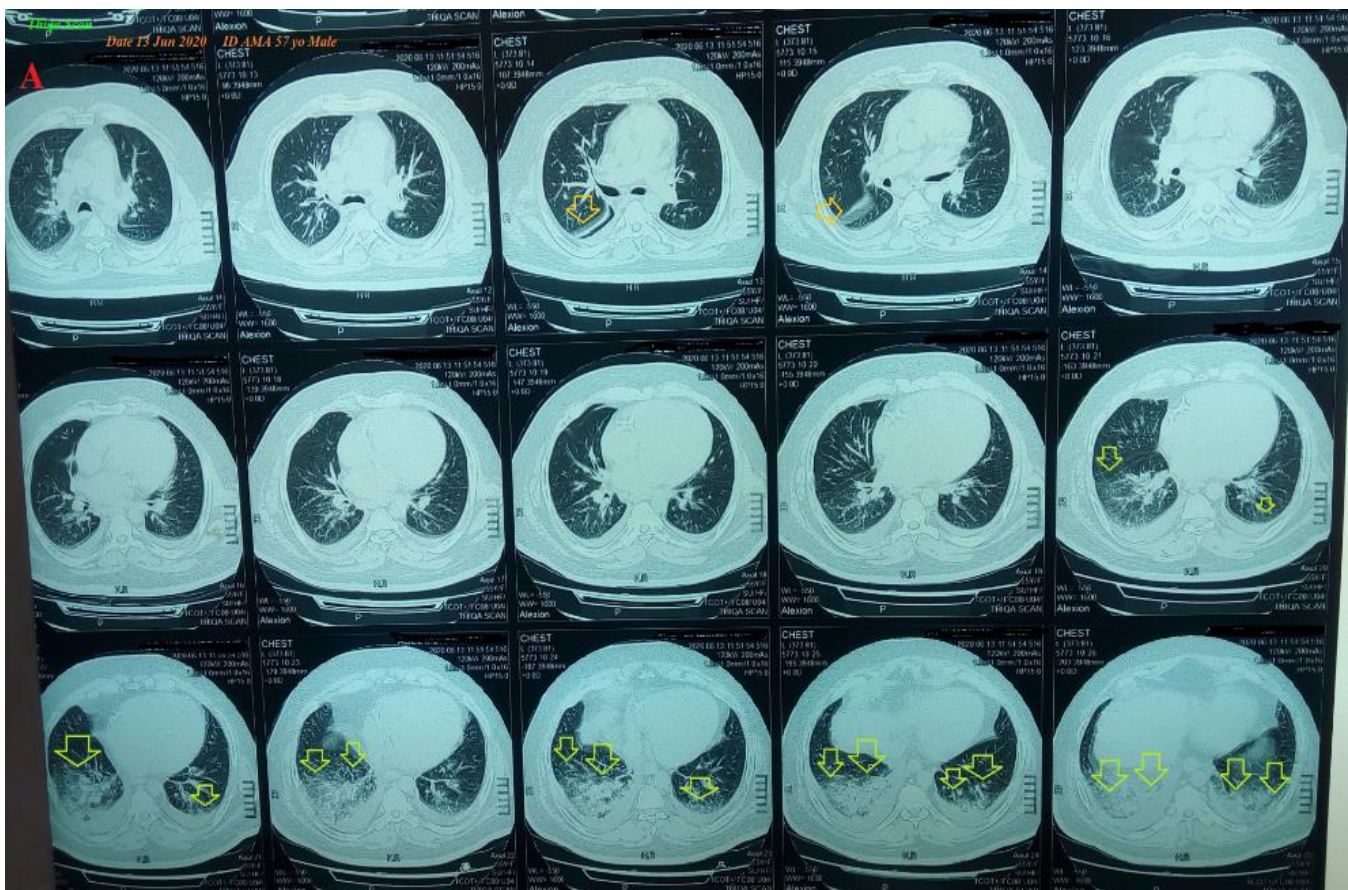
1. Different successive three beats in the same lead are affected.
2. All ECG leads can be implicated.
3. An associated elevated beat is seen with the first of the successive three beats, a depressing beat with the second beat, and an isoelectric ST-segment in the third one.
4. The elevated beat is either accompanied by ST-segment elevation or just an elevated beat above the isoelectric line.
5. Also, the depressed beat is either associated with ST-segment depression or just a depressing beat below the isoelectric line.
6. The configuration for depressions, elevations, and isoelectricities of ST-segment for the subsequent three beats are variable from case to case. So, this arrangement non-conditional.

7. Mostly, there is no participation among the involved leads. The author intended that is not conditionally included in an especial coronary artery for the affected leads [5].

The initial presentation of a novel Coronavirus-2 (**COVID-19**) that is resulting in severe acute respiratory syndrome (SARS) had appeared in Wuhan, China in December 2019 [6]. COVID-19 Disease is a highly communicable, rapidly spread, lethal worldwide disease [7]. Despite COVID-19 disease was primarily presented with respiratory symptoms, but cardiovascular involvements were common and accompanied by higher mortality among these patients [8].

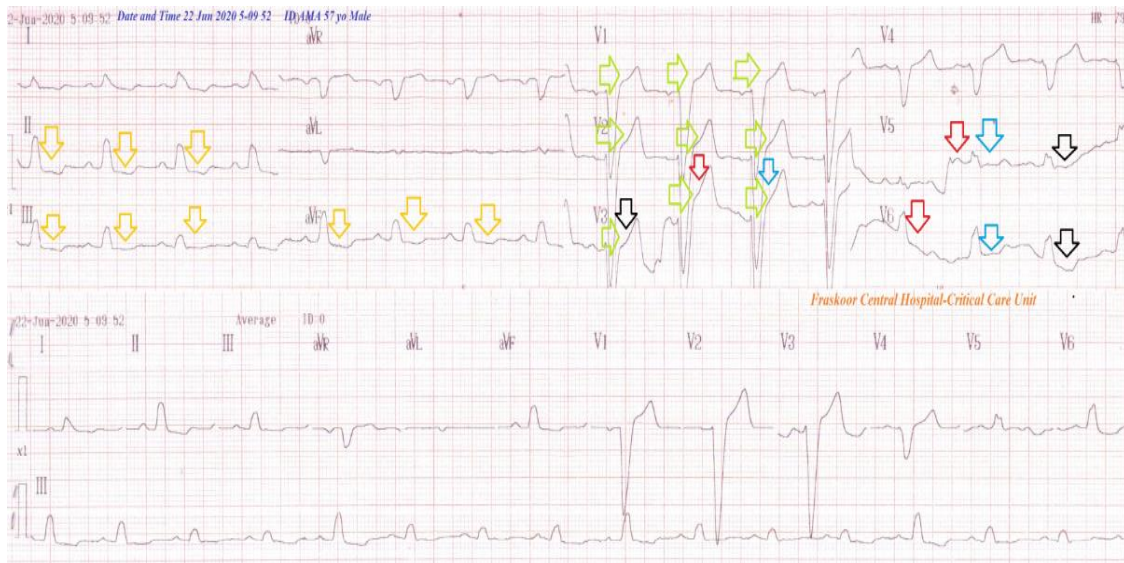
### Case presentation

A 57-year-old married carpenter Egyptian male patient presented in the emergency department with acute tachypnea and fever. Fatigue, loss of appetite, and generalized body aches were associated symptoms. Currently, he had a history of contact with a neighbor who confirmed a COVID-19 patient in the past 10 days. The patient was admitted to the intensive care unit (ICU) with acute pneumonia. Upon general physical examination; generally, the patient was tachypneic, distressed, with a regular pulse rate of 70 bpm, blood pressure (BP) of 100/70 mmHg, respiratory rate of 36 bpm, the temperature of 39.3 °C, and pulse oximeter of oxygen (O<sub>2</sub>) saturation of 91%. He seemed obese. No more relevant clinical data were noted during the clinical examination. The patient was treated in ICU with COVID-19 pneumonia (**Figure 1A**).



**Figure 1A:** chest CT scan was done on presentation showing bilateral multiple patchy ground-glass pulmonary consolidations (lime and orange arrows)

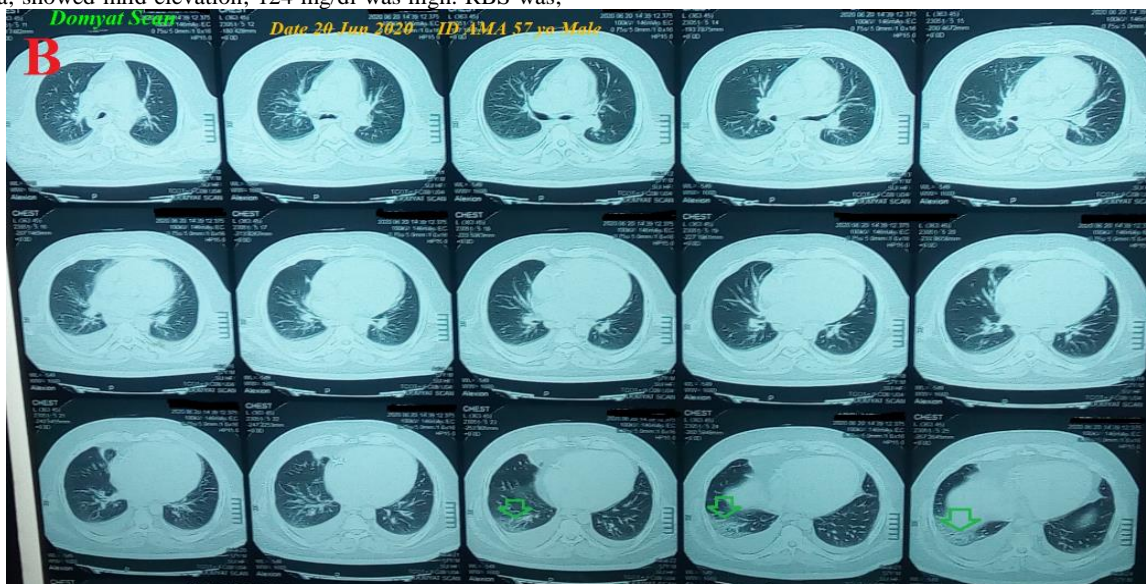
LBBB and Wavy triple sign (Yasser's sign) of hypocalcemia in consequent ECG (**Figure 2**).



**Figure 2:** ECG tracing was done on the initial ECG on presentation showing LBBB (of VR of 73) with indicating concordant ST elevation > 5 mm in anterior leads (V1, 2 and V3,) (lime arrows), with ST-segment depression in inferior leads (II, III, aVF) (orange arrows). There is a Wavy triple sign of hypocalcemia or Yasser’s sign-in V3, 5, and V6 leads (red, black, and blue arrows).

Initially, the patient was treated with O2 inhalation by O2 cylinder (100%, by nasal cannula, 5L/min). The patient was maintain treated with cefotaxime; (1000 mg IV every 8 hours), azithromycin (500 mg PO single daily dose), oseltamivir (75 mg PO twice daily only for 5 days), and paracetamol (500 mg IV every 8 hours as needed). SC (enoxaparin 80 mg twice daily), aspirin tablet (75 mg, once daily), clopidogrel tablet (75 mg, once daily), and hydrocortisone sodium succinate (100 mg IV every 12 hours) were added. The patient was hourly monitored for temperature, pulse, blood pressure, and O2 saturation. The initial complete blood count (CBC); Hb was 10.4 g/dl, RBCs;  $3.89 \times 10^3/\text{mm}^3$ , WBCs;  $8.6 \times 10^3/\text{mm}^3$  (Neutrophils; 86.9 %, Lymphocytes: 9.4%, Monocytes; 2.7%, Eosinophils; 1% and Basophils 0%), Platelets;  $148 \times 10^3/\text{mm}^3$ . S. Ferritin was high; 569 ng/ml. D-dimer was high (644 ng/ml). CRP was high; 17.1 g/dl. LDH was high; 611 U/L. SGPT was normal; 17 U/L, SGOT was normal; 13 U/L. Serum creatinine showed moderate elevation; 4 mg/dl and blood urea; showed mild elevation; 124 mg/dl was high. RBS was;

113 mg/dl. Ionized calcium was mildly low; 0.69 mmol/L. The troponin test was negative. Initial ABG showed acute metabolic acidosis. After 8 days of management; CBC; Hb was 12.7 g/dl, RBCs;  $3.94 \times 10^3/\text{mm}^3$ , WBCs;  $7.15 \times 10^3/\text{mm}^3$  (Neutrophils; 66.4 %, Lymphocytes: 24.2%, Monocytes; 9.4%, Eosinophils; 0% and Basophils 0%), Platelets;  $208 \times 10^3/\text{mm}^3$ . Serum ferritin was normal; 266 ng/ml. D-dimer was normal (142 ng/ml). CRP was negative (0.1 g/dl). LDH was still high; 552U/L. SGPT was normal; 25 U/L, SGOT was normal; 19 U/L. Serum creatinine showed mild elevation; 3.3 mg/dl and blood urea showed mild elevation; 125 mg/dl were normal. Ionized calcium was normal; 1.10 mmol/L. The troponin test had still negative. RBS was normal; 93 mg/dl. Last ABG showed partly compensated metabolic alkalosis. The last chest CT scan was done within 8 days of the presentation showing nearly dramatic improvement of the above ground-glass consolidations. (**Figure 1B**).



**Figure 1B:** chest CT scan was done within 8 days of the presentation showing nearly dramatic improvement of the above ground-glass consolidations in healing stage (green arrows).

Echocardiography showed mild hypokinesia in the anterior segment with an EF of 55%. Left bundle branch block and Wavy triple sign (Yasser's sign) intertwining COVID-19 pneumonia with renal impairment was the **most probable diagnosis**. Within 24 days of the above management, the patient finally showed nearly complete clinical, radiological, and laboratory improvement. The patient was continued on aspirin tablet (75 mg, once daily), oral nitroglycerine capsule (2.5 mg, twice daily), oral calcium, and vitamin-D preparation for 30 days with further recommended cardiac and renal follow-up.

## Discussion

### • Overview:

• An elderly carpenter male COVID-19 patient was admitted to the intensive care unit with COVID-19 pneumonia with interlacing LBBB, renal impairment, and Wavy triple sign (Yasser's sign).

• **The objective primary** for my case study was the presence of LBBB in the presence of COVID-19 pneumonia, renal impairment, and Wavy triple an ECG sign (Yasser Sign) of hypocalcemia in ICU.

• **The secondary objective** for my case study was the **question** of; How did you manage the case?

- There was a history of direct contact to confirm the COVID-19 case.
- The presence of direct contact to confirm the COVID-19 case, and bilateral ground-glass consolidation on top of acute tachypnea will strengthen the COVID-19 diagnosis.
- The electrocardiographic LBBB of Sgarbossa score of 2 points, absence of current ischemic chest pain, vague history for previous LBBB, and negative troponin test is strongly suggestive to excluding associated acute myocardial infarction.
- An associated left bundle branch block, renal impairment, hypocalcemia, COVID-19 pneumonia marked elevated d-dimer, and evidence of ischemic heart disease (IHD) signifies the risk in the current study case.
- The presence of ST-segment depressions in inferior ECG leads (II, III, aVF) may be interpreted as accompanied by severe specific ischemic myocardial insult.
- There is no interpretation for associated renal impairment. Drug inducing, COVID-19 infection, or renal in origin are possible causes.
- An associated renal impairment and tachypnea may be guided for the presence of Wavy triple an electrocardiographic sign (Yasser Sign) and hypocalcemia
- The main differential diagnoses of the case are non-STEMI and 2<sup>nd</sup> type myocardial infarction (MI II).
- A nearly complete clinical, radiological, and laboratory improvement that occurred after the management with anti-infective drugs, anticoagulants, steroids, and antiplatelet strongly implies their effects.
- Blood pressure, respiratory rate, pulse, and O2 saturation are a strong guide for clinical follow-up in COVID-19 patients.
- A gradual decreasing the level of elevated CRP, d-dimer, and serum ferritin may be used as another good laboratory guide for follow-up for COVID-19 pneumonic patients.
- The serial change of radiological changes from normal chest CT to abnormal to normal at the end will strengthen the effectiveness of used drugs in this management.
- I can't **compare** the current case with similar conditions. There are no similar or known cases with the same management for near comparison.
- The only limitation of the current study was the unavailability of coronary angiography.

## Conclusion and Recommendations

- The triage of the left bundle branch block with the COVID-19 patient is highly significant for both diagnosis of acute myocardial infarction and giving thrombolytic.
- The combination of left bundle branch block, renal impairment, and hypocalcemia COVID-19 pneumonia signify the risk in the current case study.

## Abbreviations

**ABG:** Arterial blood gases

**AMI:** Acute myocardial infarction

**CBC:** Complete blood count

**COVID-19:** Coronavirus disease 2019

**ECG:** Electrocardiography

**IV:** Intravenous

**LBBB:** Left bundle branch block

**O2:** Oxygen

**SGOT:** Serum glutamic-oxaloacetic transaminase

**SGPT:** Serum glutamic-pyruvic transaminase

**STEMI:** ST segment elevation myocardial infarction

**VR:** Ventricular rate

## Conflicts of interest

There are no conflicts of interest.

## Acknowledgment

I wish to thanks the nurse team of the intensive care unit to give me extra copies of the ECG to help me.

## References

1. Sayed YMHE. Sgarbossa Criteria in Left Bundle Branch Block in a Hypertensive Emergency, a Case Report. *Int J Cardiovasc Sci* 2021; 34(1):107-11. DOI: 10.5935/2359-4802.20190071
2. Sgarbossa EB, Pinski SL, Barbagelata A, Underwood DA, Gates KB, Topol EJ, Califf RM, Wagner GS. Electrocardiographic diagnosis of evolving acute myocardial infarction in the presence of left bundle-branch block. GUSTO-1 (Global Utilization of Streptokinase and Tissue Plasminogen Activator for Occluded Coronary Arteries) Investigators. *N Engl J Med*. 1996 Feb 22; 334(8):481-7. DOI: 10.1056/NEJM199602223340801. Erratum in: *N Engl J Med* 1996 Apr 4; 334(14):931. PMID: 8559200.
3. Meyers HP, Limkakeng AT Jr, Jaffa EJ, Patel A, Theiling BJ, Rezaie SR, et al. Validation of the modified Sgarbossa criteria for acute coronary occlusion in the setting of left bundle branch block: retrospective case control study. *Am Heart J*. 2015; 170(6):1255-64. DOI: 10.1016/j.ahj.2015.09.005. Epub 2015 Sep 24. PMID: 26678648.
4. Smith SW, Dodd KW, Henry TD, Dvorak DM, Pearce LA. Diagnosis of ST-elevation myocardial infarction in the presence of left bundle branch block with the st-elevation to s-wave ratio in a modified Sgarbossa rule. *Ann Emerg Med*. 2012; 60(6):766-76. DOI: 10.1016/j.annemergmed.2012.07.119. Epub 2012 Aug 31. Erratum in: *Ann Emerg Med*. 2013 Oct; 62(4):302. PMID: 22939607.

5. Elsayed YMH. Wavy Triple an Electrocardiographic Sign (Yasser Sign) in Hypocalcemia. A Novel Diagnostic Sign; Retrospective Observational Study. *EC Emergency Medicine and Critical Care (ECEC)*. 2019; 3(2):1-2. (Accessed: Nov 6, 2019).
6. Zhu N, Zhang D, Wang W, et al. A novel coronavirus from patients with pneumonia in China, 2019. *N Engl J Med*. 2020; 382:727–33. DOI: 10.1056/NEJMoa2001017
7. WHO. Coronavirus disease 2019 (COVID-19) Situation Report – 165, Available online: Af. (Accessed: Jul 3, 2020).
8. Kwenandar F, Japar KV, Damay V, Hariyanto TI, Tanaka M, Lugito NPH, Kurniawan A. Coronavirus disease 2019 and cardiovascular system: A narrative review. *Int J Cardiol Heart Vasc*. 2020 Jun 3; 29:100557. DOI: 10.1016/j.ijcha.2020.100557. PMID: 32550259; PMCID: PMC7266760.



This work is licensed under Creative Commons Attribution 4.0 License

To Submit Your Article Click Here: [Submit Manuscript](#)

DOI: [10.31579/2693-2156/020](https://doi.org/10.31579/2693-2156/020)

**Ready to submit your research? Choose Auctores and benefit from:**

- ❖ fast, convenient online submission
- ❖ rigorous peer review by experienced research in your field
- ❖ rapid publication on acceptance
- ❖ authors retain copyrights
- ❖ unique DOI for all articles
- ❖ immediate, unrestricted online access

At Auctores, research is always in progress.

Learn more [www.auctoresonline.org/journals/journal-of-thoracic-disease-and-cardiothoracic-surgery-](http://www.auctoresonline.org/journals/journal-of-thoracic-disease-and-cardiothoracic-surgery-)