

Safety of Extracorporeal Shockwave Myocardial Revascularization (ESMR) in Patient with a Mechanical Prosthetic Valve: A Case Report.

Gianluca Alunni^{1*}, Salvatore D'amico¹, Dario Celentani¹, Carlo Alberto Biolè¹, Alessandro Andreis¹, Mauro Rinaldi Prof¹, Marra Sebastiano²

¹Department of Cardiology, City of Health and Science of Turin, Turin, Italy

²Villa Maria Hospital, Turin, Italy.

***Corresponding Author:** Gianluca Alunni, City of Health and Science, 10100 Turin, Italy. Tel: +390116335945 Email: a.gianluca1@virgilio.it

Received date: July 13, 2018; **Accepted date:** August 03, 2018; **Published date:** August 08, 2018.

Citation this Article: Gianluca Alunni, Salvatore D'amico, Dario Celentani, Carlo Alberto Biolè, Alessandro Andreis, Marra Sebastiano, Mauro Rinaldi. (2018) Safety of Extracorporeal shockwave myocardial revascularization (ESMR) in patient with a mechanical prosthetic valve: a case report. J Clinical Cardiology and Cardiovascular Interventions. Doi:[10.31579/2641-0419/009](https://doi.org/10.31579/2641-0419/009)

Copyright: ©2018. Gianluca Alunni. This is an open-access article distributed under the terms of the Creative Commons Attribution License, which permits unrestricted use, distribution, and reproduction in any medium, provided the original author and source are credited.

Keywords: refractory angina; shock wave therapy; myocardial hypoperfusion

Introduction and highlights

The number of patients with refractory angina without revascularization options is increasing. The prognosis and the quality of life in these patients is poor and maximal medical therapy is not enough for symptoms relieve. According to the last American College of Cardiology/American Heart Association (ACC/AHA) guidelines on the management of chronic stable angina, the objective of the treatment should be the resolution of angina attacks, the reduction of the numbers of hospitalizations and the carrying out of normal daily activities without symptoms [1-6].

Extracorporeal Shockwave Myocardial Revascularization therapy (ESMR) is a non-invasive treatment and several studies have demonstrated its safety and its efficacy in patients with refractory angina (RA) to improve myocardial perfusion and exercise capacity reducing symptoms by the application shockwaves (SW) on the culprit ischemic area of the heart under echocardiographic guidance [7-26]. Shockwaves consist of low-intensive acoustic energy artificially generated by discharging of a high voltage spark under water by a generator designed to address the clinical anatomical requirements of the chest cavity. Several treatment sessions are required. The aim of this treatment is former to induce vasodilatation and latter to induce neovascularization from the healthy area to the ischemic area [27-37].

But, actually, there are no data about the safety of ESMR in patients with a mechanical prosthetic valve.

We would report about a 64-year-old man with coronary artery disease (CAD) and refractory angina pectoris despite maximally tolerated medical therapy and after percutaneous coronary intervention (PCI) and with a prosthetic aortic valve and aortic tube.

The patient received extracorporeal shockwave myocardial revascularization therapy without any complication during or after treatment.

1. Case presentation

64-years-old male patient with coronary artery disease debuted in 2002 with an anterior ST-elevation myocardial infarction (STEMI) treated by percutaneous coronary intervention (PCI) on medial left anterior descending artery (LAD) with implantation of a Bare Metal Stent (BMS).

In 2004, for the evidence of the stenosis of the bicuspid aortic valve and an ascending aorta aneurysm, substitution of the aortic valve and the ascending aorta with a mechanical valve attached to a Dacron tube graft (St. Jude 25mm + 28 mm) was performed.

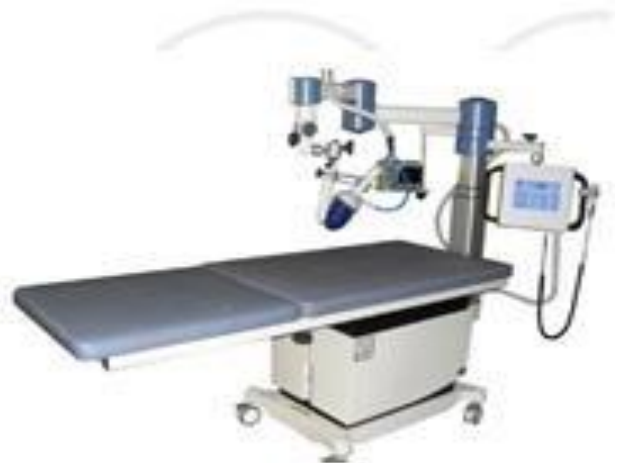In 2011, for new evidence of stress angina, PCI with a drug eluting stent (DES) implantation of the proximal RCA was performed.

In 2013, for stress angina recurrence, a myocardial single-photon emission computed tomography (SPECT) with pharmacological stress (Dipyridamole) was performed, with the evidence of modest inducible ischemia in inferior cardiac wall (SRS 3, SSS 9, SDS 6), without CAD progression at the coronary angiography.

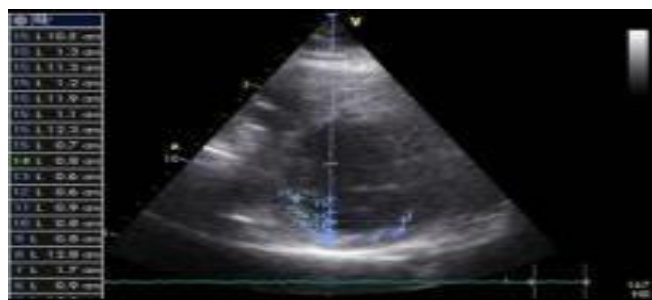
For this reason, in 2014, we decided to treat the patient with shockwaves therapy.

2. ESMR protocol

We locate the area to treat by documenting inducible ischemia at the stress myocardial SPECT. The ESMR were applied with a commercially available cardiac shock wave generator system (Cardiospect TM, Medispec, Germantown, MD) under echocardiographic guidance (Figure 1.A and B): through a cardiac ultrasound imaging system, we look at this area and these measurements are calibrated into the shockwave applicator head to ensure the position of the focal treatment zone, so using an electrocardiographic R-wave gating, shockwaves are delivered through the applicator to the sub-endocardial myocardium of the ischemic area. We applied a low energy of shockwaves (0.09 mJ/mm², ≈10% of the energy for the lithotripsy treatment).



A



B

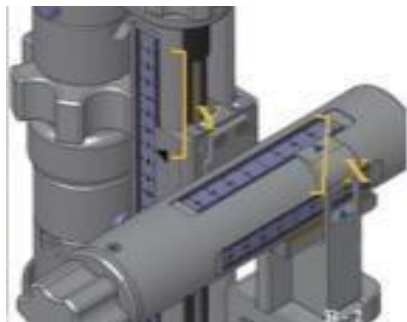


Figure 1. The methodology of cardiac shock wave therapy.

A. Shock wave generator system (Medispec, Germantown, MD, USA).

B. Shock wave focal zone alignment: Position of the sub-segment on the 2-dimensional image determined by X and Y coordinates. The shockwave applicator position is identically adjusted along X- and Y-axes corresponding to the X and Y coordinates of the ultrasound image.

The ischemic area was divided into 3 zones, corresponding to the three sessions of treatments. The treatment was divided into three sessions with 3 treatments for week every 4 weeks. 100 pulses gated by R wave trigger was performed for each target spotted (up to a total of 1000 pulses) at each individual session. Each session lasted about 20 minutes. During the treatment, symptoms and vital signs were continuously monitored.

3. Echocardiographic prosthesis control

A regular echocardiographic follow-up was performed, without evidence of malfunction or complications about the mechanical prosthetic aortic valve and tube:

In 2013, before ESMR therapy, prosthetic valve had a normal function and position, pressure gradient (PG) was 13/6 mmHg, Aortic Valve Area (AVA) measured by Velocity Time integral (VTi) was 2.3 cm² and Doppler Velocity index (DVi) was 0.56. Prosthetic tub was regular without dehiscence.

-In 2014 prosthetic valve had a normal function and position, PG was 15/8 mmHg, V max was 2 m/sec and DVi was 0.30. Prosthetic tub was regular without dehiscence (Figure 2).

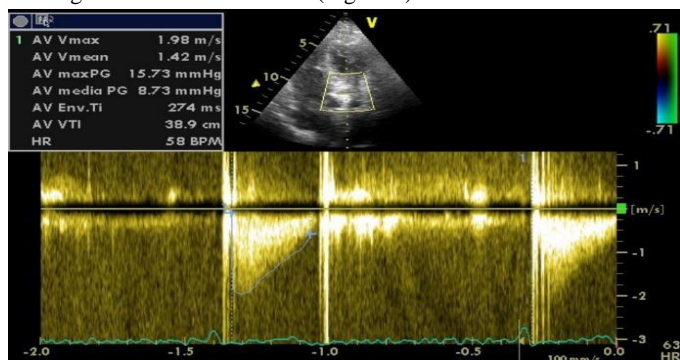


Figure 2. Echocardiography performed in 2014, before ESMR.

Last echocardiographic study was performed in January 2018 and showed a prosthetic valve with a normal function and position, PG was 12/8 mmHg, V max was 1.7 m/sec. Prosthetic tub was regular without dehiscence (Figure 3).

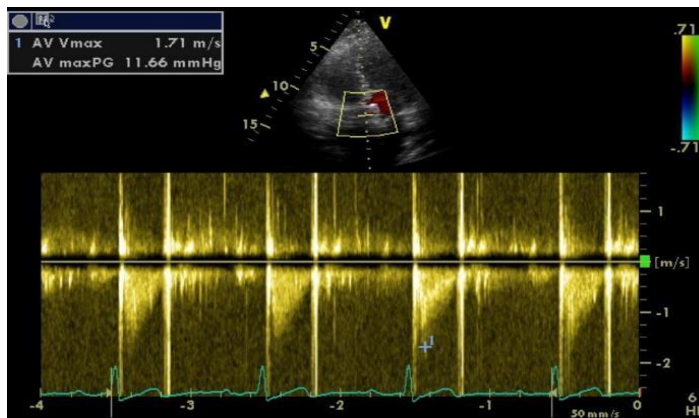


Figure 3. Echocardiography performed in 2018, three years after ESMR.

4. Conclusion

In conclusion, we treated by ESMR a patient with refractory angina and with mechanical prosthetic aortic valve and tube, without any sign of complication or malfunction of the cardiac device in acute or in further years.

The Author(s) declare(s) that there is no conflict of interest.

References

- Stephan D. Fihn, James C. Blankenship, Karen P. Alexander, John A. Bittl, John G. Byrne, et al. (2014) ACC/AHA /AATS/PCNA /SCAI /STS Focused Update of the Guideline for the Diagnosis and Management of Patients With Stable Ischemic Heart Disease. *J Am Coll Cardiol* ; 64 (18) :1929-1949.
- D'Ascenzo F, Barbero U, Moretti C, Palmerini T, Della Riva D, et al. (2014) Percutaneous coronary intervention versus coronary artery bypass graft for stable angina: meta-regression of randomized trials. *Contemp Clin Trials*;38(1):51–58.
- André P, Ekre O, Grip L, Währborg P, Albertsson P, et al. (2009) Fatality, morbidity and quality of life in patients with refractory angina pectoris. *Int J Cardiol*; 147(3):377–382.
- Mannheimer C, Camici P, Chester MR, Collins A, DeJongste M, et al. (2002) The problem of chronic refractory angina; report from the ESC Joint Study Group on the Treatment of Refractory Angina. *Eur Heart J*;23(5):355–370.
- Arnold Suzanne V, Morrow David A, Lei Yang, Cohen David J, Mahoney Elizabeth M, et al. (2009) Economic impact of angina after an acute coronary syndrome: insights from the MERLIN-TIMI 36 trial. *Circ Cardiovasc Qual Outcomes*;2:344–353.
- Barbero U, D'Ascenzo F, Nijhoff F, Moretti C, Biondi-Zoccai G, et al. (2016) Assessing risk in patients with stable coronary disease: when should we intensify care and follow-up? Results from a meta-analysis of observational studies of the COURAGE and FAME era. *Scientifica (Cairo)*;3769152.
- Cassar Andrew, Prasad Megha, Martin-Rodriguez-Porcel, Reeder Guy S, Karia Darshak, et al. (2014) Safety and efficacy of extracorporeal shockwave myocardial revascularization therapy for refractory angina pectoris. *Mayo Clin Proc* ;89(3):346 – 354.
- Fukumoto Y, Ito A, Uwatoku T, Matoba T, Kishi T, et al. (2006) Extracorporeal cardiac shock wave therapy ameliorates myocardial ischemia in patients with severe coronary artery disease. *Coron Artery Dis*;17(1):63 – 70.
- Kikuchi Y, Ito K, Ito Y, Shiroto T, Tsuburaya R, et al. (2010) Double-blind and placebo-controlled study of the effectiveness and safety of extracorporeal cardiac shock wave therapy for severe angina pectoris. *Circ J* ;74(3):589 – 591.

10. Leibowitz D, Weiss AT, Rott D, Durst R, Lotan C, (2013) The efficacy of cardiac shock wave therapy in the treatment of refractory angina: a pilot prospective, randomized, double-blind trial. *Int J Cardiol* ;167(6):3033 – 3034.
11. Kazmi WH, Rasheed SZ, Ahmed S, Saadat M, Altaf S, et al (2012) Noninvasive therapy for the management of patients with advanced coronary artery disease. *Coron Artery Dis*;23(8):549 – 554.
12. Serruys PW, Unger F, Sousa JE, Jatene A, Bonnier J.R.M, et al.(2001) Comparison of coronary artery bypass surgery and stenting for the treatment of multivessel disease. *N Engl J Med*;344:1117-1124.
13. Zelle BA, Gollwitzer H, Zlowodzki M, Buhren V, (2010) Extracorporeal shock wave therapy: current evidence. *J Orthop Trauma*;24(1):S66 – 70.
14. Alunni G, Marra S, Meynet I, D'amico M, Elisa P, et al. (2015) The beneficial effect of ex-tracorporeal shockwave myocardial revascularization in patients with refractory angina. *Cardiovasc Revasc Med* ;16(1):6 – 11.
15. Alunni G, Barbero U, Vairo A, D'Amico S, Pianelli M et al. (2017) The beneficial effect of extracorporeal shockwave myocardial revascularization: Two years of follow up. *Cardiovasc Revasc Med* 18: 572 - 576.
16. Burneikaite G, Shkolnik E, Čelutkienė J, Zuožienė G, Butkuvienė I et al.(2017) Cardiac shock-wave therapy in the treatment of coronary artery disease: systematic review and meta-analysis. *Cardiovascular Ultrasound* ; 15:11.
17. Ruiz-Garcia J, Lerman A. (2011) Cardiac shock-wave therapy in the treatment of refractive angina pectoris. *Interv Cardiol* ;3(2):191 – 201.
18. Sheu JJ, Sun CK, Chang LT, Fang HY, Chung SY, et al.(2010) Shock wave-pretreated bone marrow cells further improve left ventricular function after myocardial infarction in rabbits. *Ann Vasc Surg*;24(6):809 – 821.
19. Fu M, Sun CK, Lin YC, Wang CJ, Wu CJ, et al.(2011) Extracorporeal shock wave therapy reverses ischemia-related left ventricular dysfunction and remodeling: molecular-cellular and functional assessment. *PLoS One* ;6(9).
20. Wang Y, Guo T, Cai HY, Ma TK, Tao SM, et al.(2010) Cardiac shock wave therapy reduces angina and improves myocardial function in patients with refractory coronary artery disease. *Clin Cardiol* ;33(11):693 -699.
21. Nishida T, Shimokawa H, Oi K, Tatewaki H, Uwatoku T, et al. (2004) Extracorporeal cardiac shock wave therapy markedly ameliorates ischemia-induced myocardial dysfunction in pigs in vivo. *Circulation*;110(19):3055 – 3061.
22. Uwatoku T, Ito K, Abe K, Oi K, Hizume T, et al.(2007) Extracorporeal cardiac shock wave therapy improves left ventricular remodeling after acute myocardial infarction in pigs. *Coron Artery Dis*;18(5):397-404.
23. Zimpfer D, Aharinejad S, Holfeld J, Thomas A, Dumfarth J, et al (2009) Direct epicardial shock wave therapy improves ventricular function and induces angiogenesis in ischemic heart failure. *J Thorac Cardiovasc Surg.* ;137(4):963-970.
24. Vasyuk YA, Hadzegova AB, Shkolnik EL, Kopeleva MV, Krikunova OV, et al.(2010) Initial clinical experience with extracorporeal shockwave therapy in treatment of ischemic heart failure. *Congest Heart Fail*;16(5):226 – 230.
25. Ito K, Fukumoto Y, Shimokawa H.(2009) Extracorporeal shock wave therapy as a new and non-invasive angiogenic strategy. *Tohoku J Exp Med*;219(1):1 – 9.
26. Abe Y, Ito K, Hao K, Shindo T, Ogata T, et al. (2014) Extracorporeal low-energy shock-wave therapy exerts anti-inflammatory effects in a rat model of acute myocardial infarction. *Circ J* ;78(12):2915-2925.
27. Young SR, Dyson M. (1990) The effect of therapeutic ultrasound on angiogenesis. *Ultrasound Med Biol*;16:261 – 269.
28. Wang CJ, Huang HY, Pai CH. (2002) Shock wave-enhanced neovascularization at the tendon-bone junction: an experiment in dogs. *J Foot Ankle Surg* ; 41:16 – 22.
29. Wang FS, Wang CJ, Huang HJ, Chung H, Chen RF, et al (2001) Physical shock wave mediates membrane hyperpolarization and Ras activation for osteogenesis in human bone marrow stromal cells. *Biochem Biophys Res Commun* ;287:648 – 655.
30. Gotte G, Amelio E, Russo S, Marlinghaus E, Musci G, et al (2002) Short-time non-enzymatic nitric oxide synthesis from L-arginine and hydrogen peroxide induced by shock waves treatment. *FEBS Lett*;520:153 – 155.
31. Mariotto S, Cavalieri E, Amelio E, Ciampa AR, de Prati AC, et al.(2005) Extracorporeal shock waves: from lithotripsy to anti-inflammatory action by NO production. *Nitric Oxide* ;12(2):89 – 96.
32. Mariotto S, de Prati AC, Cavalieri E, Amelio E, Marlinghaus E, et al (2009) Extracorporeal shock wave therapy in inflammatory diseases: molecular mechanism that triggers anti-inflammatory action. *Curr Med Chem* ;16:2366 – 2372.
33. Reher P, Doan N, Bradnock B, Meghji S, Harris M. (1999) Effect of ultrasound on the production of IL-8, basic FGF and VEGF. *Cytokine* ;11:416 – 423.
34. Gutersohn A, Caspari G. (2000) Shock waves upregulate vascular endothelial growth factor mRNA in human umbilical vascular endothelial cells. *Circulation*;102:(18).
35. Yoshida J, Ohmori K, Takeuchi H, Shinomiya K, Namba T, et al.(2005) Treatment of ischemic limbs based on local recruitment of vascular endothelial growth factor-producing inflammatory cells with ultrasonic microbubble destruction. *J Am Coll Cardiol* ;46(5):899 – 905.
36. Aicher A, Heeschen C, Sasaki K, Urbich C, Zeiher AM, et al (2006) Low-energy shockwave for enhancing recruitment of endothelial progenitor cells: a new modality to increase efficacy of cell therapy in chronic hind limb ischemia. *Circulation* ; 114:2823 – 2830.
37. Yip HK, Chang LT, Sun CK, Youssef AA, Sheu JJ, et al (2008) Shock wave therapy applied to rat bone marrow-derived mononuclear cells enhances formation of cells stained positive for CD31 and vascular endothelial growth factor. *Circ J* ;72(1):150 – 156.