

# Coronary Artery Vasospasm: A Unique Cause of ST-Elevation Myocardial Infarction in COVID19

Julia Peterson DO<sup>1\*</sup>, Shahad Al Chalaby MB ChB<sup>1</sup>, Oluwayemisi Adejumo MD<sup>1,2</sup>, Xin Yang MD<sup>1,2</sup>

<sup>1</sup> Department of Internal Medicine, Alameda Health System – Highland Hospital, Oakland, California, United States

<sup>2</sup> Department of Cardiology, Alameda Health System, Oakland, California, United States

\*Corresponding author: Julia Peterson, Department of Internal Medicine, Alameda Health System – Highland Hospital, Oakland, California, United States.

Received Date: April 04, 2021; Accepted Date: May 01, 2021; Published Date: May 10, 2021.

Citation: J Peterson, Shahad Al Chalaby, O Adejumo, X Yang. (2021) Coronary Artery Vasospasm: A Unique Cause of ST-Elevation Myocardial Infarction in COVID19. *Cardiology Research and Reports*. 3(2): Doi: [10.31579/2692-9759/021](https://doi.org/10.31579/2692-9759/021)

Copyright: © 2021 Julia Peterson. This is an open-access article distributed under the terms of the Creative Commons Attribution License, which permits unrestricted use, distribution, and reproduction in any medium, provided the original author and source are credited.

## Abstract

Coronary artery vasospasm (CAV) is an under-recognized cause of ACS in patients with COVID-19. Difference in pathophysiology and management increases the importance of the identification of these patients. We describe the first case of CAV in a patient with COVID-19 in the absence of signs of severe systemic inflammation.

**Keywords:** acute coronary syndrome; coronary angiography; echocardiography; chest pain; vascular disease; COVID-19

## Introduction

Coronavirus 2019 (COVID-19) has been shown to be associated with the development of a wide range of cardiovascular disorders. Coronary vasospasm and related myocardial injury in patients with COVID-19 infection is infrequently described and may be underdiagnosed. Here we present a novel case of a patient with mild COVID-19 infection presenting with STEMI and found to have severe coronary spasm complicated by a transmural myocardial infarction.

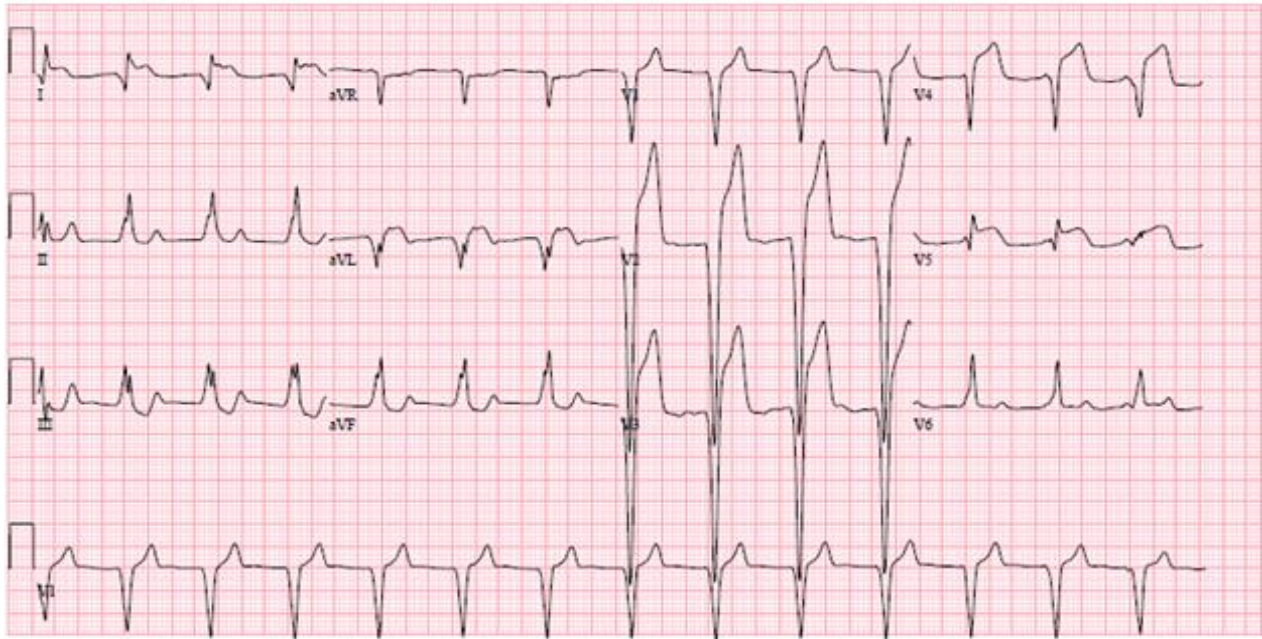
## Case Report

A 59-year-old man with a recent diagnosis of COVID-19 presented to the emergency department (ED) with 6 days of progressively worsening episodic left sided chest pain. Patient described chest pain as severe, pressure like, non-radiating, associated with shortness of breath and nausea. Ten days prior to his ED presentation, he developed symptoms of fatigue, malaise, loss of taste and smell. He tested positive for COVID-19 from a workplace exposure and was in isolation at home. The patient's past medical history was significant for hypothyroidism, and a new diagnosis of hyperlipidemia and diabetes mellitus. His only medication prior to admission was levothyroxine.

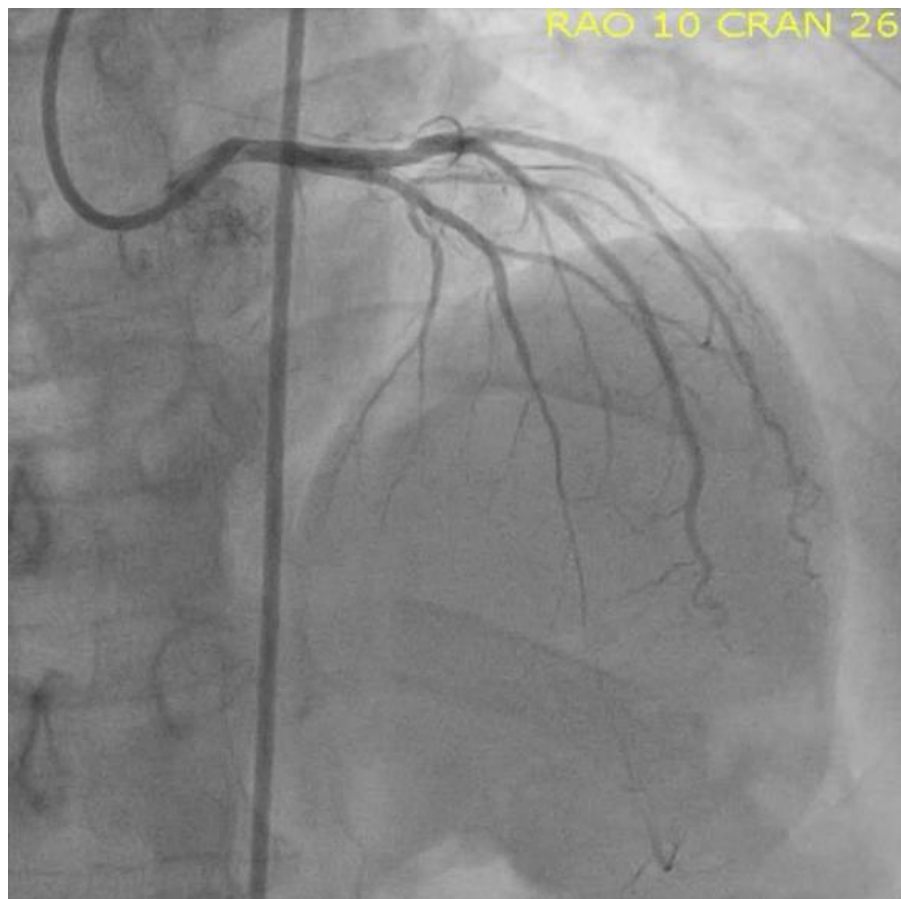
On arrival to the ED, he complained of acute worsening of chest pain of a few hours duration and his triage vital signs showed a blood pressure of 169/86 mmHg, heart rate of 67 beats per minute, respiratory rate of 18 breaths per minute, oxygen saturation of 99% on room air, and

temperature of 36.6 degrees Celsius. ECG identified anteroseptal and lateral STEMI with reciprocal changes in inferior leads (figure1). Patient was loaded with aspirin 324 mg when STEMI was noted on ECG in the ED. He also received 0.4 mg of nitroglycerin sublingually and 4 mg of morphine intravenously with mild transient improvement in his symptoms prior to cardiac catheterization. Initial serum troponin was 0.89 ng/mL (normal <0.1 ng/mL). Emergent coronary angiography was performed and identified severe mid and distal LAD spasm (Figure 2). Intracoronary nitroglycerin was given with significant improvement in LAD spasm (Figure 3), which was associated with complete resolution of symptoms. A transthoracic echocardiogram showed mildly reduced left ventricular ejection fraction of 40–45% with anteroseptal hypokinesia along with apical and distal anterolateral segments akinesia. Serum troponin peaked at 202.29 ng/mL. Chest radiograph was unremarkable. Patient was found to have elevated hemoglobin A1C 10.9% and was diagnosed with diabetes mellitus. Thyroid stimulating hormone was 2.93 mIU/mL. Urine toxicology screen was negative for cocaine and methamphetamine.

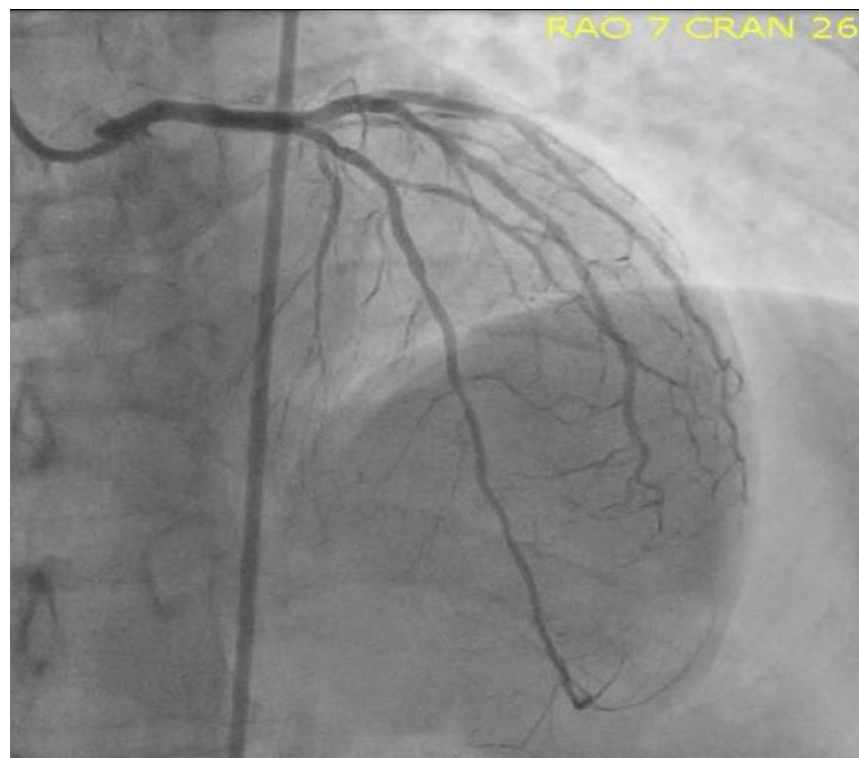
He was then started on aspirin 81 mg, high intensity atorvastatin, Lisinopril, and metoprolol succinate for newly diagnosed cardiomyopathy. Patient remained hemodynamically stable throughout this hospitalization with complete resolution of symptoms. He was discharged home three days later with as needed nitroglycerin, aspirin, statin, angiotensin converting enzyme inhibitor, and beta blocker and is planned for follow up in clinic to optimize heart failure management.



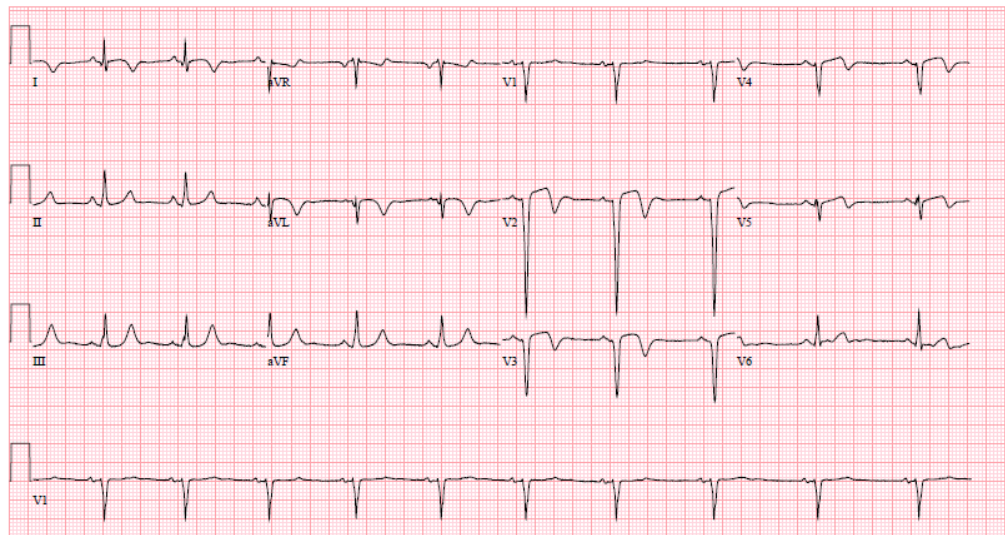
**Figure 1:** ECG showing more than 3 mm ST elevation in anteroseptal leads.



**Figure 2:** Coronary Angiogram illustrating mid-distal LAD vasospasm before administration of intracoronary nitroglycerin.



**Figure 3:** Coronary Angiogram illustrating mid-distal LAD vasospasm after administration of intracoronary nitroglycerin, with significant improvement in vasospasm.



**Figure 4:** ECG showing resolution of ST elevation in antero-septal leads after intracoronary nitroglycerin administration with resolution of symptoms and improvement in coronary vasospasm on coronary angiography.

## Discussion

The novel coronavirus 2019 has resulted in numerous cases with various cardiovascular complications, including but not limited to: acute coronary syndrome [1, 2], stress induced cardiomyopathy, right ventricular dysfunction [3], myocarditis, arrhythmias, and thromboembolism [4]. Only one case of coronary artery vasospasm in a patient with COVID-19 infection has been reported in the literature thus far [5], in a patient with severe COVID-19 pneumonia complicated by acute respiratory distress syndrome presenting with chest pain. During coronary angiogram, that patient had evidence of hemodynamically significant coronary artery

disease that did not improve with intracoronary nitroglycerin resulting in stent placement and was ultimately diagnosed using invasive vasospasm testing.

To our knowledge, our case is the first report of CAV in a patient with COVID-19 infection presenting with STEMI on ECG and found to have severe CAV in a corresponding vessel without obvious provocation. Our patient had more than 3 mm ST elevation in the antero-septal leads with corresponding severe mid to distal LAD vasospasm with near obliteration of vessel lumen. This improved significantly with intracoronary nitroglycerin administration with concurrent resolution of symptoms and

ECG normalization. Patient did not have known independent risk factors for CAV, including tobacco, cocaine and methamphetamine or other stimulant use.

COVID-19 causes a severe systemic inflammatory state, including release of pro-inflammatory cytokines, T helper cell cytokine response, oxidative stress, and endothelial dysfunction related to increased ACE-2 (Angiotensin converting enzyme) receptor activation [6, 7]. It is possible that this patient may have already had underlying endothelial dysfunction and microvascular dysfunction related to his newly diagnosed diabetes [8] and hyperlipidemia that when coupled with a systemic inflammatory state associated with COVID-19 infection predisposed him to have CAV with transmural myocardial infarction.

His COVID-19 respiratory symptoms were mild on presentation and out of proportion to his degree of chest pain. Despite his mild symptoms related to COVID-19 disease, he developed severe LAD spasm complicated by a transmural myocardial infarction leading to LV systolic dysfunction. His symptoms and LAD spasm resolved with intracoronary nitroglycerin administration with resolution of STEMI on ECG (Figure 4) supporting the diagnosis of CAV. Up to one third of COVID-19 patients presenting with STEMI on ECG have angiographically normal coronary arteries in one case series by Bangalore et al [2], which may be among other possible reasons due to underdiagnosed intermittent CAV.

## Conclusion

To date, this is the first case of coronary vasospasm reported with COVID-19 infection in the United States and the second case reported worldwide. A wide variety of cardiovascular manifestations have been identified during the COVID-19 pandemic; however, CAV is infrequently reported and may have a higher prevalence in this patient population.

We seek to increase medical society awareness about CAV in COVID-19 infection and that the condition can develop even in the absence of signs of severe systemic inflammation or hypoxemia. Further studies are needed to investigate the association between COVID-19 disease and the risk of coronary vasospasm.

## Abbreviations:

COVID-19: Coronavirus 2019

STEMI: ST segment elevation myocardial infarction

ECG: Electrocardiography

CAV: coronary artery vasospasm

ED: Emergency Department

ACS: Acute coronary syndrome

LAD: left anterior descending coronary artery

**Acknowledgements:** We would like to acknowledge the patient and the significance of this case in expanding our understanding of the cardiovascular complications in COVID19. We would like to also acknowledge the effort and contribution of all the authors in writing this paper. We have no funding sources to acknowledge.

**Author Disclosures:** The authors have reported no disclosures and no relationships with industry.

## References:

1. Shi S, Qin M, Shen B, et al. (2020) Association of cardiac injury with mortality in hospitalized patients with COVID-19 in Wuhan, China. *JAMA Cardiol.* 5 (7):802-810.
2. Bangalore S, Sharma A, Slotwiner A, et al. (2020) ST-segment elevation in patients with Covid-19 – a case series. *N Engl J Med.* 382(25):2478-2480.
3. Fukui M, Cavalcante JL. (2020) Relation among right ventricular dysfunction, lung damage, and mortality in patients with COVID-19. *JACC Cardiovasc Imaging.* 13(8):1858-1859.
4. Driggin, E, Madhavan MV, Bikdeli B, et al. (2020) Cardiovascular considerations for patients, health care workers, and health systems during the COVID-19 pandemic. *J Am Coll Cardiol.* 75(18):2352-2371.
5. Rivero F, Antuña P, Cuesta J, Alfonso F, et al. (2020) Severe coronary spasm in a COVID-19 patient. *Catheter Cardiovasc Interv.* 10.1002/ccd.29056.
6. Leisman DE, Ronner L, Pinotti R, et al. (2020) Cytokine elevation in severe and critical COVID-19: a rapid systematic review, meta-analysis, and comparison with other inflammatory syndromes. *Lancet Respir Med.* 8(12):1233-1244.
7. Babapoor-Farrokhran S, Gill D, Walker J, Rasekhi RT, Bozorgnia B, Amanullah A. (2020) Myocardial injury and COVID-19: Possible mechanisms. *Life Sci.* 253:117723.
8. Shinozaki K, Hirayama A, Nishio Y, et al. (2001) Coronary endothelial dysfunction in the insulin-resistant state is linked to abnormal pteridine metabolism and vascular oxidative stress. *J Am Coll Cardiol.* 38(7):1821-1828.



This work is licensed under Creative Commons Attribution 4.0 License

To Submit Your Article Click Here: [Submit Manuscript](#)

DOI: [10.31579/2692-9759/021](https://doi.org/10.31579/2692-9759/021)

### Ready to submit your research? Choose Auctores and benefit from:

- ❖ fast, convenient online submission
- ❖ rigorous peer review by experienced research in your field
- ❖ rapid publication on acceptance
- ❖ authors retain copyrights
- ❖ unique DOI for all articles
- ❖ immediate, unrestricted online access

At Auctores, research is always in progress.

Learn more [www.auctoresonline.org/journals/cardiology-research-and-reports](http://www.auctoresonline.org/journals/cardiology-research-and-reports)