

COVID-19 pneumonia with right bundle branch block, Movable phenomenon, and S1S2S3 syndrome in diabetic, hypertensive, and stented ischemic disease; multiple risks and dramatic response; at home management; a case-report

Yasser Mohammed Hassanain Elsayed

Critical Care Unit, Damietta Health Affairs, Egyptian Ministry of Health (MOH), Damietta, Egypt.

Corresponding Author: Yasser Mohammed Hassanain Elsayed, Critical Care Unit, Damietta Health Affairs, Egyptian Ministry of Health (MOH), Damietta, Egypt.

Received date: May 30, 2021; **Accepted date:** June 14, 2021; **Published date:** June 17, 2021

Citation: Yasser M. H. Elsayed (2021) COVID-19 pneumonia with right bundle branch block, Movable phenomenon, and S1S2S3 syndrome in diabetic, hypertensive, and stented ischemic disease; multiple risks and dramatic response; at home management; a case-report. *J. Heart and Vasculature* 1(4); DOI: 10.31579/JHV-2021/022

Copyright: © 2021, Yasser Mohammed Hassanain Elsayed, This is an open access article distributed under the Creative Commons Attribution License, which permits unrestricted use, distribution, and reproduction in any medium, provided the original work is properly cited.

Abstract

A novel COVID-19 with a lethal acute respiratory syndrome had emerged in Wuhan, China in December 2019 interestingly; the presentation of COVID-19 infection with diabetes, hypertension, and ischemic heart disease has a risk impact on both morbidity and mortality in COVID-19 patients. The Movable-weaning phenomenon or Yasser's phenomenon is a novel electrocardiographic phenomenon in hypocalcemia. Movable-weaning off an electrocardiographic phenomenon is a guide for both Wavy triple and double electrocardiographic signs. Middle-aged worker male COVID-19 diabetic, hypertensive, and stented ischemic heart disease patient presented to physician outpatient clinic with pneumonia. COVID-19 pneumonia with right bundle branch block, Movable phenomenon or Yasser's phenomenon of hypocalcemia, and S1S2S3 syndrome in diabetic, hypertensive, and stented ischemic disease. Non-contrasted chest CT scan, electrocardiography, oxygenation, and echocardiography were the interventions. Dramatic of both clinical and radiological improvement had happened. The combination of pneumonia, right bundle branch block, Movable phenomenon or Yasser's phenomenon of hypocalcemia, stented ischemic heart disease, diabetes, and hypertension is an indicator of the over-risk of both morbidity and mortality. It signifies the role of anticoagulants, antiplatelet, anti-infective drugs, and steroids in COVID-19 patients with pneumonia and the above multiple risks are effective therapies. Adjusting the dose of steroids with a diabetic and hypertensive patient was reasonable.

Keywords: coronavirus, pneumonia, right bundle branch block, movable phenomenon, S1S2S3 syndrome, stent, ischemic heart disease, diabetes, and hypertension

Abbreviations

CBC: Complete blood count

COVID-19: Coronavirus disease 2019

CV: Cardiovascular

ECG: Electrocardiography

IV: Intravenous

IHD: Ischemic heart disease

LAD: Left axis deviation

O2: Oxygen

POC: Physician outpatient clinic

RAD: Right axis deviation

RBBB Right bundle branch block

RVH: Right ventricular hypertrophy

SGOT: Serum glutamic-oxaloacetic transaminase

SGPT: Serum glutamic-pyruvic transaminase

VR: Ventricular rate

Introduction

The essential presentation of an existing Coronavirus-2 (COVID-19) that is causing strenuous acute respiratory syndrome (SARS) had protruded in Wuhan, China in December 2019 [1]. COVID-19 Disease is a highly communicable, abruptly spread, lethal worldwide disease [2]. Despite

COVID-19 disease was initially appeared with respiratory symptoms, but cardiovascular affection was frequent rather than the presence of higher rates [3]. However, cardiovascular events may be evident as a delayed phenomenon in pneumonic COVID-19 patients [3]. Right bundle branch block (RBBB) generally, happens in 0.2% to 1.3% of the population and is mostly a benign electrocardiographic (ECG) finding [4]. Nevertheless, some studies showed an increase in the risk of both cardiovascular (CV) morbidity and mortality [4]. Mortality may occur in patients with RBBB despite an absence of CV Disease [4]. RBBB is used as a remarkable predictor of poor outcome in patients with acute myocardial infarction (AMI), but the prognostic entanglement of RBBB in patients with suspected ischemic heart disease (IHD) is controversial [5]. Moreover, the link between RBBB and incidence of IHD and its effects on the severity of IHD has still not been decided [5]. The presence of changeable Wavy triple electrocardiographic sign in ECG leads is a hallmark for the existence of the Movable phenomenon or Yasser's phenomenon of hypocalcemia [6]. Tachypnea was a possible cause of hypocalcemia and subsequent Wavy triple electrocardiographic and Movable-weaning phenomenon of hypocalcemia [7]. The S1S2S3 syndrome may occur within certain limits in children but in adults increase the suspicion of right ventricular hypertrophy (RVH) [8]. The S1S2S3 syndrome is not an uncommon ECG sign associated with acquired RVH due to chronic pulmonary disease (CPD) [8]. Most patients with pulmonary emphysema will present with right axis deviation (RAD) on the ECG. Nevertheless, some patients with emphysema may have left axis deviation (LAD) in the absence of clinical IHD, systemic hypertension, or chronic heart failure [9]. This kind of LAD is called pseudo-LAD (S1S2S3 syndrome) [9].

This article aimed to clarify the effect of multiple risks such as right bundle branch block, Movable phenomenon, S1S2S3 syndrome, diabetic, hypertensive, and stented ischemic disease in COVID-19 pneumonia.

Case presentation

A 55-year-old married male Egyptian worker patient presented to the physician outpatient clinic (POC) with acute tachypnea, palpitations, fever, and chest pain. Generalized malaise and body pain, loss of appetite, loss of smell, and taste were associated symptoms. The patient gave a history of the symptoms for 6 days. Currently, he had a history of contact with his neighbor who confirmed a COVID-19 patient in the past 10 days. There was a history of angina with cardiac catheterization with one stent placement. Informed consent was taken. Upon general physical examination; generally, the patient was tachypneic, distressed, with a regular pulse rate 91 bpm, blood pressure (BP) of 100/70 mmHg, respiratory rate of 27 bpm, the temperature of 39.5 °C, and pulse oximeter of oxygen (O₂) saturation of 93%. He appeared to have a good body-weight built. No more relevant clinical data were noted during the clinical examination. The patient was treated at home as COVID-19 pneumonia with RBBB, Movable phenomenon or Yasser's phenomenon of

hypocalcemia, and S1S2S3 syndrome in diabetic, hypertensive, and stented IHD. Initially, the patient was treated with O₂ inhalation by O₂ cylinder (100%, by nasal cannula, 5L/min). The patient was maintain treated with cefotaxime; (1000 mg IV every 8hours), azithromycin (500 mg PO single daily dose), oseltamivir (75 mg PO twice daily only for 5 days), and paracetamol (500 mg IV every 8 hours as needed). SC enoxaparin 80 mg twice daily), aspirin tablet (75 mg, once daily), clopidogrel tablet (75 mg, once daily), and hydrocortisone sodium succinate (100 mg IV every 12 hours; was tapered with time) were added [10-13]. The patient was daily monitored for temperature, pulse, blood pressure, and O₂ saturation. Serial ECG tracings were done. The initial ECG was done on presentation showing RBBB of VR; 91 bpm. There are S1S2S3 syndrome and Wavy triple sign or Yasser's sign of hypocalcemia in II, V2, 3, and V6 leads. (Figure 1A). ECG tracing was done within one minute of the initial ECG showing the same RBBB of VR; 93 bpm. There are SISIISII syndrome and Movable or Yasser's phenomenon of hypocalcemia in V3, 5, and V6 leads (Figure 1B). The initial complete blood count (CBC); Hb was 9.96 g/dl, RBCs; 3.89*10³/mm³, WBCs; 13.3*10³/mm³ (Neutrophils; 81.2 %, Lymphocytes: 12.7%, Monocytes; 5.1%, Eosinophils; 1% and Basophils 0%), Platelets; 216*10³/mm³. S. Ferritin was high; 466 ng/ml. D-dimer was high (718 ng/ml). CRP was high (14.3g/dl). LDH was high (576 U/L). SGPT was normal (40 U/L), SGOT was normal (26 U/L). Serum creatinine was normal (0.9 mg/dl) and blood urea was normal (37 mg/dl). RBS was high (249 mg/dl). Ionized calcium was low (0.76 mmol/L). The troponin test was negative. After 13 days of management; RBS was normal (96 mg/dl). CBC; Hb was 13.4 g/dl, RBCs; 4.61*10³/mm³, WBCs; 4.23*10³/mm³ (Neutrophils; 56.8 %, Lymphocytes: 40.2%, Monocytes; 2%, Eosinophils; 1% and Basophils 0%), Platelets; 142*10³/mm³. Serum ferritin was normal (151 ng/ml). D-dimer was normal (174 ng/ml). CRP was negative (5.7 g/dl). LDH was normal (362U/L). SGPT was high (61.2 U/L), SGOT was high (51.4 U/L). Serum creatinine (1.31 mg/dl) and blood urea (31.9 mg/dl) were normal. Ionized calcium was normal; 1.2 mmol/L. The troponin test had still negative. The Chest CT was done within 7 days of the treatment showing bilateral patchy ground-glass pulmonary consolidation in the peripheral and posterior distribution of the lower lobe of the right lung in the healing stage (Figure 2). Echocardiographic images previously were done for follow-up showing hypokinetic inferior and basal inferoseptal segments with grade I diastolic dysfunction with EF of 66% (Figure 3). COVID-19 pneumonia with right bundle branch block, Movable phenomenon or Yasser's phenomenon of hypocalcemia, and S1S2S3 syndrome in diabetic, hypertensive, and stented ischemic disease was the most probable diagnosis. Within 15 days of the above management, the patient finally showed nearly complete clinical, radiological, and laboratory improvement. The patient was continued on aspirin tablet (75 mg, once daily) nitroglycerin ret. 2.5mg oral capsule, and bisoprolol 5mg oral tablet, oral calcium, and vitamin-D preparation for 30 days with further recommended and cardiac chest follow-up.

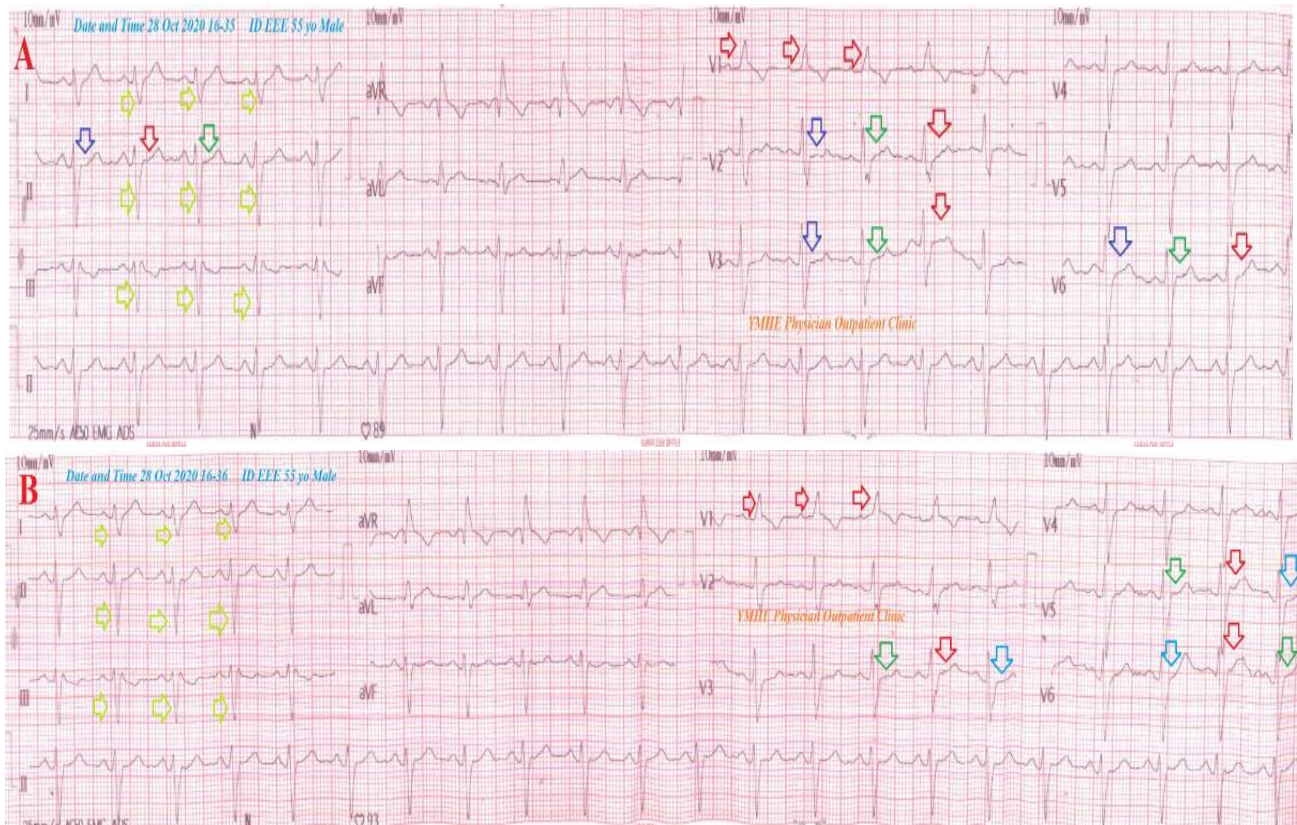


Figure 1: Serial ECG tracings; A. tracing was done on initial presentation showing RBBB (red arrows) of VR; 91 bpm. There are S1S2S3 syndrome (lime arrows) and Wavy triple sign or Yasser’s sign of hypocalcemia in II, V2, 3, and V6 leads (red, blue, and green arrows). B. tracing was done within one minute of the initial ECG showing the same RBBB (red arrows) of VR; 93 bpm. There is S1S2S3 syndrome (lime arrows) and Movable or Yasser’s phenomenon of hypocalcemia in V3, 5, and V6 leads (red, blue, and green arrows).

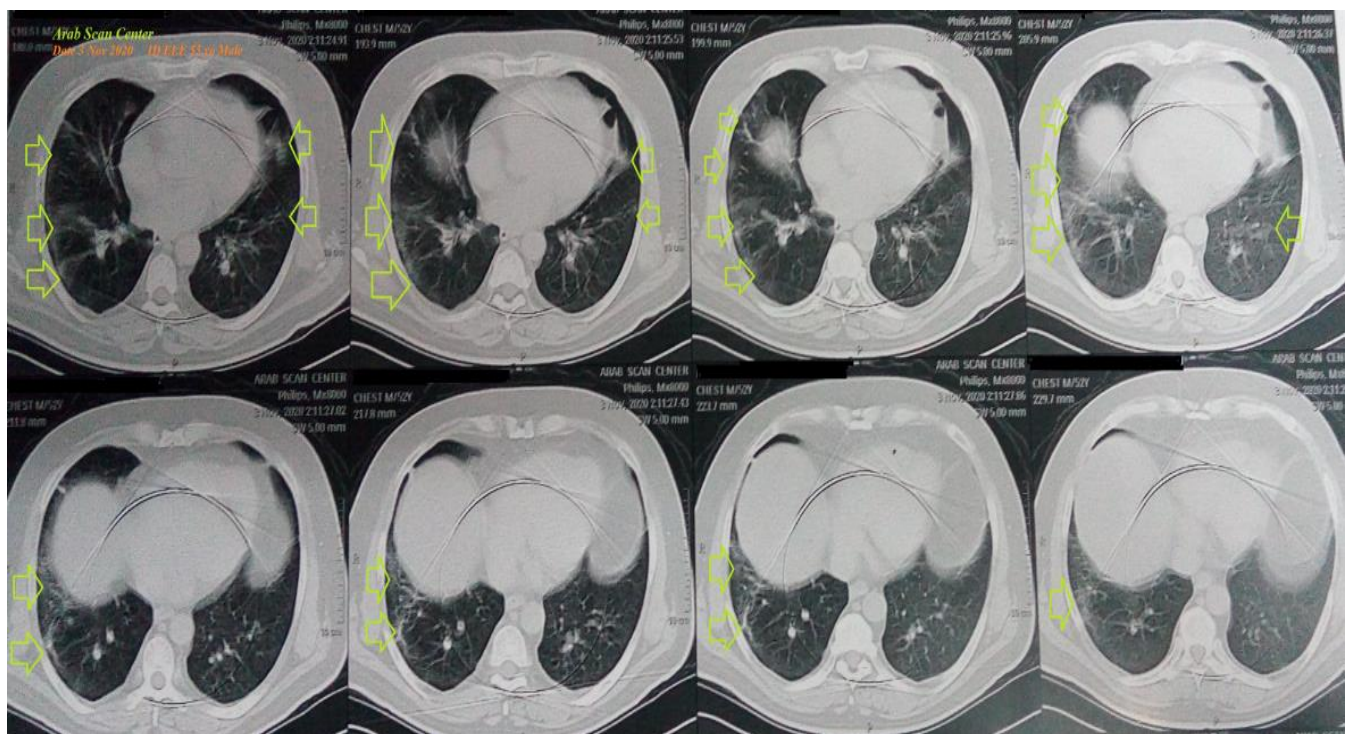


Figure 2: Chest CT was done within 7 days of the treatment showing bilateral patchy ground-glass pulmonary consolidation in the peripheral and posterior distribution of the lower lobe of the right lung in the healing stage (lime arrows).

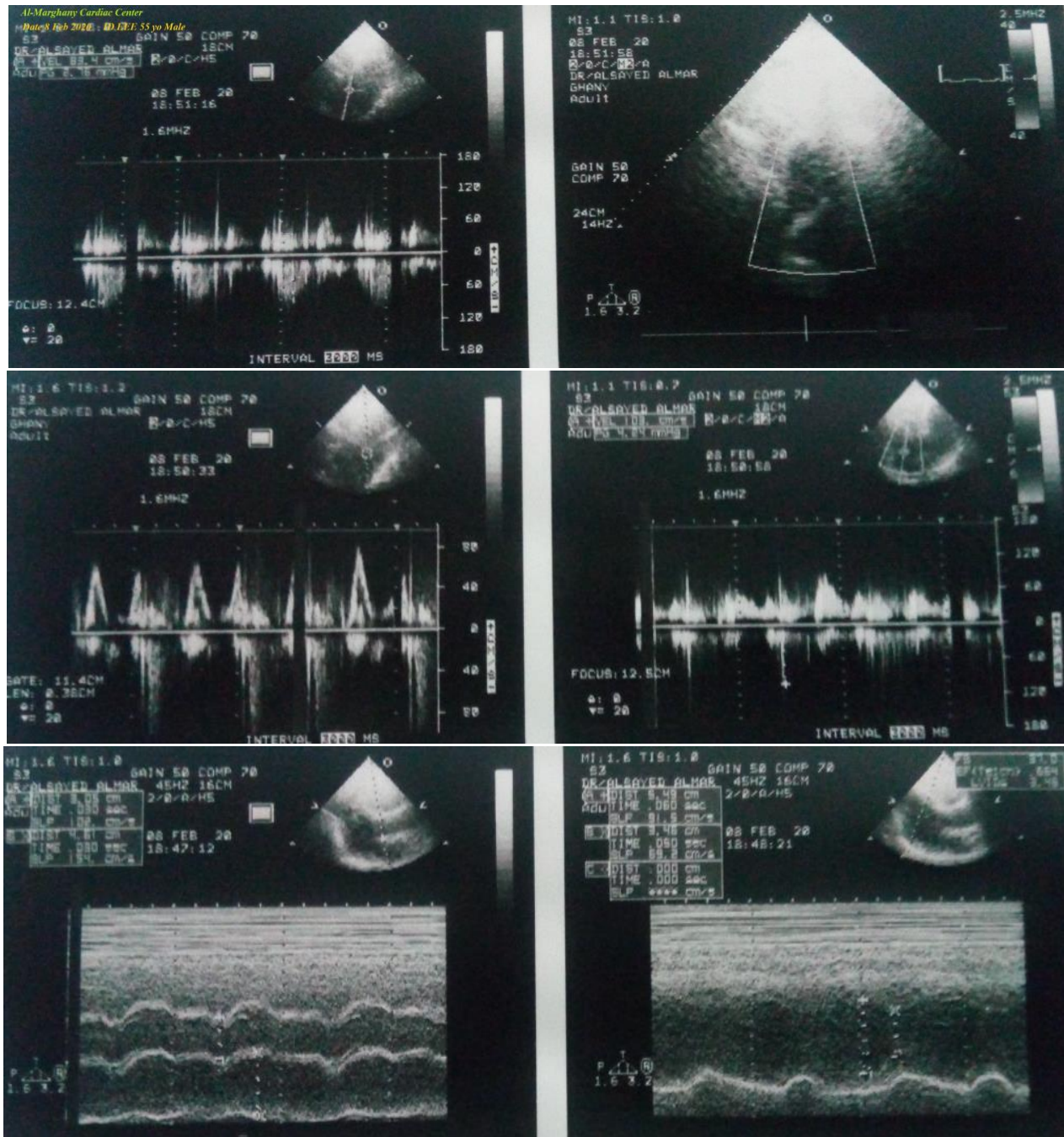


Figure 3-Echocardiographic images previously were done for follow-up showing hypokinetic inferior and basal inferoseptal segments with grade-I diastolic dysfunction.

Discussion

- Middle-aged worker male COVID-19 diabetic, hypertensive, and stented ischemic heart disease patient presented to POC with pneumonia.
- The primary objective for this case study was the presence of COVID-19 pneumonia with right bundle branch block, Movable phenomenon or Yasser’s phenomenon of hypocalcemia, and S1S2S3 syndrome in diabetic, hypertensive, and stented IHD in POC.
- The secondary objective for this case study was the question of; how did you manage the case at home?

- There was a history of direct contact to confirm the COVID-19 case.
- The presence of direct contact to confirmed the COVID-19 case, and bilateral ground-glass consolidation on top of acute tachypnea will strengthen the COVID-19 diagnosis.
- The history of angina who had undergone percutaneous transluminal coronary angioplasty (PTCA) with stent and hypokinetic echocardiography are indicating ischemic heart disease.

- Despite the existence of ECG RBBB mostly a benign finding but, maybe a hallmark for an associated acute pulmonary embolism in the current case.
- An associated ECG S1S2S3 syndrome may be a signal for chronic pulmonary disease, despite also, it increases the suspicion of both RVH and pulmonary embolism.
- Movable phenomenon or Yasser's phenomenon of hypocalcemia is a signal for tachypnea in the current case.
- The combination of COVID-19 pneumonia with RBBB, Movable phenomenon or Yasser's phenomenon of hypocalcemia, S1S2S3 syndrome, diabetes, hypertension, and stented ischemic disease are significant risk factors.
- The rising of SGPT and SGOT after treatment is of unknown etiology. But, mostly it is drug-inducing.
- An decreasing the dose of steroids in the diabetic hypertensive patients was reasonable.
- Acute pulmonary embolism was the possible differential diagnosis for the current case study.
- I can't compare the current case with similar conditions. There are no similar or known cases with the same management for near comparison.
- The only limitation of the current study was the current echocardiography.

Conclusion

The combination of pneumonia, right bundle branch block, Movable phenomenon, stented ischemic heart disease, diabetes, and hypertension is an indicator of the over-risk of both morbidity and mortality. It signifies the role of anticoagulants, antiplatelet, anti-infective drugs, and steroids in COVID-19 patients with pneumonia and the above multiple risks are effective therapies. Adjusting the dose of steroids with a diabetic, and the hypertensive patient was reasonable.

Conflicts of interest

There are no conflicts of interest.

Acknowledgment

I wish to thanks my wife to save time and improving the conditions for supporting me.



This work is licensed under Creative Commons Attribution 4.0 License

To Submit Your Article Click Here: [Submit Manuscript](#)

DOI: [10.31579/JHV-2021/022](https://doi.org/10.31579/JHV-2021/022)

References

1. Zhu N, Zhang D, Wang W, et al. (2020) A novel coronavirus from patients with pneumonia in China, 2019. *N Engl J Med.* 382:727–733. DOI:10.1056/NEJMoa2001017
2. WHO. Coronavirus disease 2019 (COVID-19) Situation Report – 165.
3. Kwenandar F, Japar KV, Damay V, Hariyanto TI, Tanaka M, Lugito NPH, Kurniawan A. (2020) Coronavirus disease 2019 and cardiovascular system: A narrative review. *Int J Cardiol Heart Vasc.* 29:100557. DOI: 10.1016/j.ijcha.2020.100557. PMID: 32550259; PMCID: PMC7266760.
4. Gaba P, Pedrotty D, DeSimone CV, Bonikowske AR, Allison TG, Kapa S. (2020) Mortality in Patients With Right Bundle-Branch Block in the Absence of Cardiovascular Disease. *J Am Heart Assoc.* 9(19):e017430. DOI: 10.1161/JAHA.120.017430.
5. Parsa AF, Haghighi L. (2012) Right bundle branch block is not a predictor of coronary artery disease. *Acta Med Iran.* 50(2):117-121. PMID: 22359081.
6. Elsayed YMH. (2021) Movable-Weaning off an Electrocardiographic Phenomenon in Hypocalcemia (Changeable Phenomenon or Yasser's Phenomenon of Hypocalcemia)-Retrospective-Observational Study. *CPQ Medicine*, 11(1), 01-35.
7. Elsayed YMH. (2021) A COVID-19 extensive bilateral pneumonia, variants ischemic heart disease, and Movable-weaning phenomenon of hypocalcemia or Yasser's phenomenon; dramatic reversal at home management. *J Clin Images Med Case Rep.* 2(2):1035.
8. Ray Pryor. (1964) The S1, S2, S3 Syndrome in Chronic Pulmonary Disease. *Diseases of the Chest*, 46(2):226.
9. Mishra A, Mishra S, Mishra JP (2018) Review: 'Pseudo'-syndromes in cardiology. *Blood Heart Circ.* 2(3):1-7. DOI: 10.15761/BHC.1000140
10. National Institutes of Health (2020). COVID-19 Treatment Guidelines Panel. Coronavirus Disease 2019 (COVID-19) Treatment Guidelines.
11. Kumar P, et al (2021) Role of ACE2 receptor and the landscape of treatment options from convalescent plasma therapy to the drug repurposing in COVID-19. *Mol Cell Biochem.* 476(2):553-574. DOI: 10.1007/s11010-020-03924-2.
12. Elsayed YMH (2020) A COVID-19 Bilateral Patchy Pneumonia in a Diabetic and Hypertensive Patient despite Normal Lymphocytic Count; At Home Distinct Management; A Case Report. *J Med Clin Stud.* 3(4):140.
13. Elsayed YMH (2020) A COVID-19 Bilateral Peripheral Pneumonia in a Cirrhotic Patient; at Home Diverse Management; A Case Report. *J Clin & Commun Med.* 2(4):209-213.

Ready to submit your research? Choose Auctores and benefit from:

- ❖ fast, convenient online submission
- ❖ rigorous peer review by experienced research in your field
- ❖ rapid publication on acceptance
- ❖ authors retain copyrights
- ❖ unique DOI for all articles
- ❖ immediate, unrestricted online access

At Auctores, research is always in progress.

Learn more www.auctoresonline.org/journals/journal-of-heart-and-vasculature-