

Case Report

Open Access

Acetylcholine Spasm Provocation Test by Trans-Radial Artery and Vein Approach: A Case Report

Shozo Sueda^{1*}, Hiroaki Kohno¹, Hirokazu Habara¹, Kaori Fujimoto¹.¹Department of Cardiology, Ehime Niihama Prefectural Hospital, Tsukazaki Hospital.***Corresponding Author:** Shozo Sueda, the Department of Cardiology, Ehime Niihama Prefectural Hospital, Niihama City, Japan.
Email: EZF03146@nifty.com**Received date:** April 30, 2018; **Accepted date:** May 16, 2018; **Published date:** May 21, 2018.**Citation this Article :** Shozo Sueda, Hiroaki Kohno, Hirokazu Habara, Kaori Fujimoto, Acetylcholine spasm provocation test by trans-radial artery and vein approach: a case report J. Clinical Cardiology and Cardiovascular Intervention, **Doi:10.31579/2641-0419/006****Copyright:** ©2018. Shozo Sueda. This is an open-access article distributed under the terms of the Creative Commons Attribution License, which permits unrestricted use, distribution, and reproduction in any medium, provided the original author and source are credited.

Abstract

70-year-old man admitted to our hospital because of chest discomfort on effort. Because we inserted the 6 Fr sheath into the wrong radial vein, we replaced the 5 Fr sheath into the radial vein. We inserted the 6 Fr sheath into the radial artery. We performed the acetylcholine and ergonovine spasm provocation tests under the temporary pace maker insertion. After the procedures, we compressed the radial artery and vein with radial band simultaneously. No bleeding or hematoma was found after the removal of radial band. We could perform the acetylcholine test via the radial artery and vein without any complications.

Keywords

Radial artery, Radial vein, Acetylcholine spasm provocation test.

Introduction

According to the Japanese Circulation Society (JCS) guidelines, the insertion of temporary pace maker is necessary during acetylcholine testing.1) We reported the brachial artery and vein approach spasm provocation tests of acetylcholine.2) We recently performed the radial artery and brachial vein approach spasm provocation test of acetylcholine. Here, we report a case whom we could successfully perform the acetylcholine test via the radial artery and vein approach procedure.

Case report

In 2000, 52-year-old man admitted to another hospital because of chest oppression on exercise. Just mild atherosclerosis on the mid left anterior descending (LAD) artery was found. Intracoronary ergonovine administration of 40 µg into the right coronary artery (RCA) caused focal spasm on segment 2-3, while subtotal occlusion at segment 7 was recognized after the administration of 64 µg ergonovine into the left coronary artery (LCA). He was diagnosed as multiple coronary spastic angina. Under the two calcium-channel antagonists (nifedipine R 80 mg and benidipine 8 mg/day) and statin (fluvastatin 15 mg), he was well controlled. In 2018, coronary computed tomography was performed. Coronary atherosclerosis on both left anterior descending artery and circumflex artery was suspected, while myocardial thallium scintigraphy showed the anterior and inferior ischemia.

We tried to perform the coronary angiography including the acetylcholine test. We failed the puncture of brachial vein and punctured the radial artery. We inserted the 6 Fr sheath into the wrong radial vein. We replaced the 5 Fr sheath into the radial vein. We again punctured the radial artery near the radial vein and cannulated with 6 Fr sheath. (Figure 1-A) No significant coronary stenosis was found on control coronary angiography (Figure 2-A, 2-B). We performed the acetylcholine test on both coronary arteries (Figure 1-B). No spasm was provoked after the intracoronary administration of 20/50/80/100 µg acetylcholine (Figure 2-C, 2-D). Intracoronary ergonovine test was performed. Typical spasm was not provoked after the administration of 40/64 µg ergonovine (Figure 2-E, 2-F). After the administration of nitrate, no significant fixed stenosis was recognized (Figure 2-G, 2-H). We could successfully perform the pharmacological spasm provocation tests via the radial artery and vein approach procedures (Figure 1-C) and compressed the puncture sites with the radial band simultaneously (Figure 1-D). After the 8 hours' compression of radial band, no bleeding or hematoma was found around the puncture sites. He discharged well next morning.

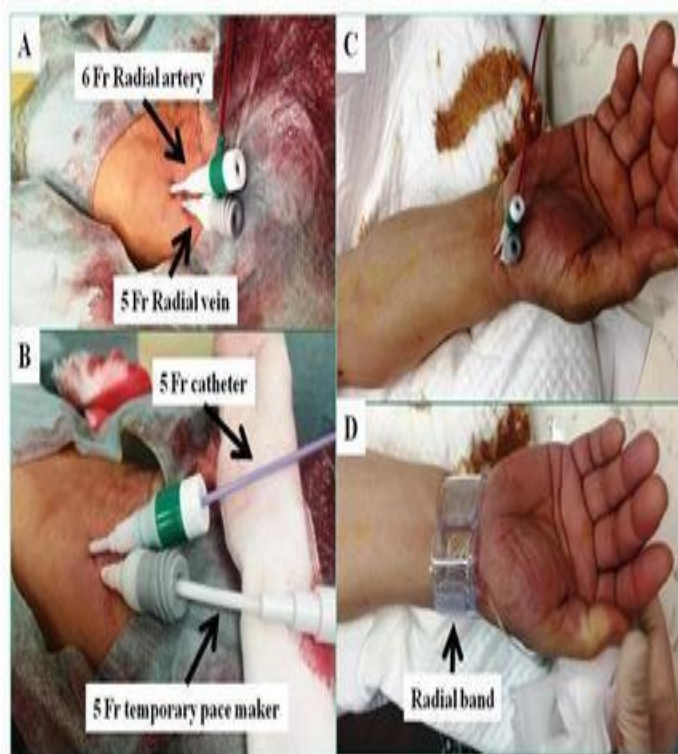

Figure 1: Procedures of radial artery and vein approach catheterization and hemostat device of radial band

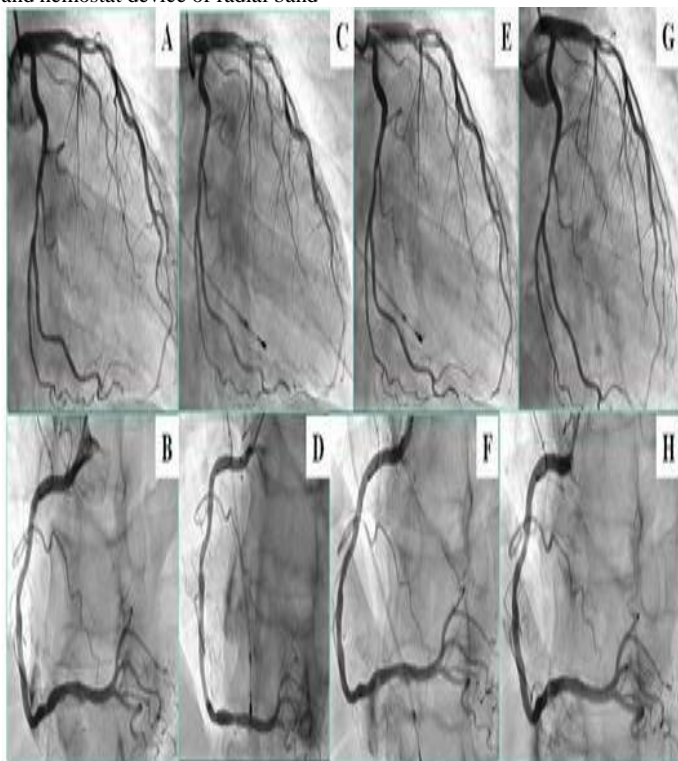


Figure 2: Pharmacological spasm provocation tests

A & B: control coronary angiography

C: after the injection of acetylcholine 100 g D: after the injection of acetylcholine 80 g

E: after the administration of 64 g ergonovine F: after the administration of 40 g ergonovine G & H: after the injection of nitrates.

Discussion

We could successfully perform the pharmacological spasm provocation tests including the intracoronary acetylcholine test via the radial artery and vein approach procedure. No bleeding or hematoma was found after the 8 hours' compression of the radial band.

During performing the acetylcholine test, it is necessary to insert the temporary pace maker for safety. We used femoral vein, internal jugular vein, or brachial vein to insert the temporary pace maker. Initially, we performed the acetylcholine tests via the femoral artery and vein.3) Next, we performed the acetylcholine tests by the brachial artery and femoral vein. In 2000, we reported the brachial artery and vein approach acetylcholine tests. 1) Recently, we performed the radial artery and brachial vein approach acetylcholine tests. However, two compression sites were necessary and the exercise disturbance of the upper arm was recognized.

Acetylcholine testing without the temporary pace maker was reported by Ong et al. 4) However, even more than 3 minutes administration of acetylcholine showed the back-up pace maker rhythm set at 40 beats/minute in a quarter of patients with LCA testing. 5) Acetylcholine tests in the RCA were performed in just a third of their study patients. We recommend the temporary pace maker insertion when we performed the intracoronary acetylcholine testing as the JCS guidelines. Although the routine radial vein insertion may be difficult, radial artery and vein approach acetylcholine tests were feasible and safe in this case. The most important issue was the just one compression site and more comfortable for patients.

Conclusions

We could successfully perform the radial artery and vein approach acetylcholine test without any complication in this case. When we failed the insertion of brachial vein sheath, radial vein insertion may be another choice on acetylcholine tests.

References

1. JCS joint working group.(2014) Guidelines for diagnosis and treatment of patients with vasospastic angina (Coronary spastic angina) (JCS 2013) *Circ J*; 78: 2779-2801.
2. Sueda S, Oshita A, Izoe Y, Kohno H, Fukuda H, et al.(2007) Coronary artery spasm provocation test by simultaneous brachial artery and vein approach with the Tometakun hemostat. *Jpn J Interv Cardiol*. 22: 510-513.
3. Sueda S, Ochi N, Kawada H, Matsuda S, Hayashi Y,et al (1999) Frequency of provoked coronary vasospasm in patients undergoing coronary arteriography with spasm provocation test of acetylcholine. *Am J Cardiol* 83(8): 1186-1190.
4. Ong P, Athabasiadis A, Borgulya G, Mahrholdt H, Kaski JC, et al(2012) Secctem Udo. High prevalence of a pathological reponse to acetylcholine testing in patients with stable angina pectoris and unobstructed coronary arteries: The ACOVA study. *J Am Coll Cardiol* 59(7):655-662.
5. Sueda S, Kohno H, (2017)The acetylcholine administration time plays the key role for provoked spasm in the spasm provocation test. *J Cardiol* 70(2): 141-146